

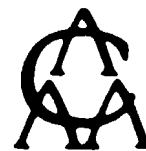**The 19<sup>th</sup>  
Annual Meeting  
of the  
American Association  
of Clinical Anatomists**



**June 4-7, 2002  
Gainesville, FL**

jointly sponsored by

**University of Florida  
and the  
American Association of Clinical Anatomists**

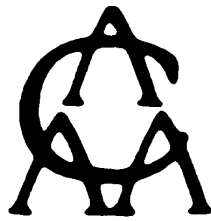

## **About the Cover Illustration**


### **Century Tower and the University Auditorium**

Century Tower and the University Auditorium are major landmarks of the University of Florida campus. Century Tower was built in 1953 to commemorate the 100th anniversary of the University and was dedicated to the University of Florida students killed in World Wars I and II. The University Auditorium, completed in the mid 1920's, is one of several University buildings included in the National Register of Historic Places.

**The  
American Association  
of  
Clinical Anatomists**



The object of the Association shall be to advance the science and art of Clinical Anatomy, to encourage research and publication in the field and to maintain high standards in the teaching of Anatomy.



## **Officers of the Executive Council**

### **President**

Daniel O. Graney, Ph.D.

### **President-Elect**

Carol Scott-Conner, M.D., Ph.D., F.A.C.S.

### **Secretary**

Lawrence M. Ross, M.D., Ph.D.

### **Treasurer**

Thomas H. Quinn, Ph.D.

### **Past-President**

R. Benton Adkins, M.D.

### **Program Secretary**

Brian R. MacPherson, Ph.D.

### **Councillors**

John A. Negulesco, Ph.D.  
Wojciech (Al) Pawlina, M.D.  
Andreas H. Weiglein, M.D.  
Michael A. Casey, Ph.D.  
Geoffrey D. Guttman, Ph.D.  
James W. Holsinger, Jr., M.D., Ph.D.

# ***Clinical Anatomy***

Official Journal of the  
American Association of Clinical Anatomists  
and the  
British Association of Clinical Anatomists

**Editor-in-Chief** - Stephen W. Carmichael

**AACA Editor** – Robert J. Leonard

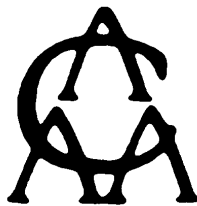**BACA Editor** – Stuart McDonald

## **Editorial Board - 2002**

Founding Editor: Ralph Ger (1988-91)

### **Associate Editors:**

S. Aharinejad	Malcolm H. Hast	Andrew T. Raftery
F. David Aker	David A. Hogg	Cornelius Rosse
Peter C. Amadio	Berend Hillen	Tatsuo Sato
Robert H. Anderson	David B. Jenkins	L. Scheuer
Charles E. Blevins	D. Gareth Jones	Hans-Martin Schmidt
David Bowsher	Jan L. Kasperbauer	H. Norman Schnitzlein
Gene L. Colborn	Subramaniam Krishnan	Ray J. Scothorne
John M. Cooke	J. Thomas Lambrecht	Carol E.H. Scott-Conner
Arthur F. Dalley	Larry L. Litke	Mark F. Seifert
Peter H. Dangerfield	Scott Lozanoff	James P. Shaw
Raffaele DeCaro	Vishy Mahandevan	Shizuko Shoumura
Adrian K. Dixon	W. Stanley Monkhouse	Reon Somana
Harold Ellis	Keith L. Moore	Robert J. Spinner
Raymond F. Gasser	Robert P. Myers	Phillip R. Waggoner
Ralph Ger	Richard L.M. Newell	Marvin Wagner
Daniel O. Graney	Kathryn E. Peek	Andreas H. Weiglein
N. Alan Green	Sepp Poisel	Peter L.T. Willan



## Annual Banquet

Thursday June 6, 2002

Presentation of *Honored Member Award*  
to

***Robert D. Acland, M.B.B.S., F.R.C.S.***

Century Ballroom  
Doubletree Hotel & Conference Center

**6:45 pm** - Reception "Two-Bits" Lounge (cash bar)

**7:30 pm** - Dinner and presentation of *Honored Member Award* to  
Robert D. Acland

The \$295 registration fee paid by members includes the cost of the Scientific Program and the Banquet. The spouse or guest of a registrant is welcome to attend the banquet. Additional tickets are available at a cost of \$50

### Previously Honored Members

W. Henry Hollinshead, 1984	Carmine D. Clemente, 1993
Chester B. McVay, 1985	Keith L. Moore, 1994
Donald James Gray, 1986	Roy J. Scothorne, 1995
Russell T. Woodburne, 1987	Robert A. Chase, 1996
Oliver Beahrs, 1988	Tatsuo Sato, 1997
N. Alan Green, 1989	John E. Skandalakis, 1998
Frank H. Netter, 1990	Donald R. Cahill, 1999
Ralph Ger, 1991	Sandy C. Marks, Jr., 2000
M. Roy Schwartz, 1992	David G. Whitlock, 2001

## Honored Member, 2002



### The American Association of Clinical Anatomists

recognize and award Honored Membership to

### **Robert D. Acland, M.B.B.S., F.R.C.S.**

Clinical Anatomist • Educator • Innovator

For his distinguished career in, and enthusiasm for, clinically-relevant anatomy, and particularly in recognition of his efforts to make gross anatomy dynamic and more readily understood by students through the *Video Atlas of Human Anatomy*.

Awarded at the 19<sup>th</sup> Annual Meeting of the AACA, Gainesville, Florida, June 6, 2002.

## **Sponsors/Commercial Exhibitors**

Generous donations and/or commercial exhibitor fees paid by the following companies and organizations have substantially reduced the Association's expenses in presenting this meeting. You are encouraged to visit the exhibits available for viewing in the *Hawthorne, Azalea and Magnolia Rooms*. Please refer to the loose materials in your registration packet for an up-to-date listing, including sponsors who have registered after the date of this printing.

**ThermoShandon  
Hydrol Chemical  
Icon Learning Systems, Inc.  
Gold Standard Multimedia  
Holt Anatomical  
Lippincott, Williams & Wilkins  
Mosby Publishing  
Primal Pictures, LTD.**

## **The 19<sup>th</sup> Annual AACA Scientific Session**

### **ACCREDITATION**

This activity has been planned and implemented in accordance with the Essential Areas and Policies of the Accreditation Council for Continuing Medical Education (ACCME) through the joint sponsorship of the University of Florida College of Medicine and the American Association of Clinical Anatomists. The University of Florida College of Medicine is accredited by the ACCME to provide continuing medical education for physicians.

### **DESIGNATION OF CME CREDIT**

The University of Florida College of Medicine designates this educational activity for a maximum of 11.25 hours in Category 1 credit towards the AMA Physician's Recognition Award. Each physician should claim only those hours of credit that he/she actually spent in the educational activity



**19<sup>th</sup> Annual Scientific Session  
of the  
American Association of Clinical Anatomists**

June 4 - 7, 2002  
University of Florida College of Medicine  
Gainesville, FL

**Tuesday, June 4, 2002** - most events at *Doubletree Hotel & Conference Center*.

- 8:00 a.m.    **Journal Committee Meeting** - (members of Journal Committee) - *Cypress Room*
- 8:00 a.m.    **Registration** - *Conference Service Area* (closes at 5:45 p.m.).
- 9:30 a.m.    **Council Meeting** - (AACA Officers and Councilors) - *Live Oak Room*
- 12:45 p.m.   **Career Development Committee Symposium:** "The Right Stuff" - *Hickory Room*
- 3:00 p.m.    Set-up for Commercial Exhibitors, *Hawthorne, Azalea and Magnolia Rooms*
- 6:00 p.m.    **Welcome Reception\*** for all meeting attendees & their accompanying persons - *Harn Museum of Art* (located across the street from the hotel).

\*The University of Florida gratefully acknowledges an unrestricted educational grant from **ThermoShandon, Hydrol Chemical** and **Icon Learning Systems** for support of the Welcome Reception.

**Wednesday, June 5, 2002** - All events at *Doubletree Hotel & Conference Center*.

- 7:00 a.m.    **Editorial Board Breakfast Meeting** - breakfast hosted by John Wiley & Sons, Inc. (for Editors/ Associate Editors of *CLINICAL ANATOMY*) - *Dogwood Room*.

Wednesday, June 5th

7:00 a.m.        **Registration** - Conference Service Area  
**Commercial Exhibits** - Hawthorne, Azalea and  
Magnolia Rooms

7:00-8:00 a.m. **Continental Breakfast**

**Poster Session I** - Hawthorne, Azalea and Magnolia Rooms

*All posters listed below will be on display throughout Wednesday, 8:00 a.m. to 4:30 p.m. Presenters of even-numbered posters must be present at their posters during the morning refreshment break, those presenting odd numbered posters must be present during the afternoon refreshment break.*

*\* preceding the poster number indicates the presentation is in the Predoctoral Award Competition.*

- 01** - The study of muscle architecture using three-dimensional ultrasound. **AGUR, Anne**, Roger LEEKAM\*, Aaron FENSTER\*, and Nancy MCKEE\*. Departments of Surgery and Medical Imaging, University of Toronto and The J.P. Robarts Research Institute, University of Western Ontario, ON, CANADA.
- 02** - The influence of the upper rectal artery and its branches on recent hemorrhoidectomy techniques. **AIGNER\*, Felix**, Gerd BODNER\*, Friedrich CONRAD\*, Helga FRITSCH\*, Stefano LONGATO\* and Sepp POISEL. University of Innsbruck, Institute for Anatomy, Department of Radiology and Department of Surgery, University of Innsbruck Medical Center, Innsbruck, AUSTRIA.
- 03** - Intramedullary melanoma: a case report and review of the literature. **ARCHIE\*, Victor C.**, Guy J.F. JULLIARD\*, Robert PARKER\* Steve P. LEE\*, and Michael T. SELCH\*. UCLA Department of Radiation Oncology UCLA Medical Center, Los Angeles, CA. (Sponsored by J.D. Collins).
- 04** - A comparative study of fluid secreting systems in sensory organs. FIRBAS, Ulrike\*, Sonja HOCHMEISTER\*, and **Wilhelm FIRBAS**. Institute of Anatomy, University of Vienna, Vienna, AUSTRIA.

- 05 - A further investigation using Immunocytochemical localization of Cathepsin B in injured muscle cells. **FISHER, Brian D.\*** and Anil H. WALJI. Division of Anatomy, Faculty of Medicine and Dentistry, University of Alberta, Edmonton, AB. CANADA.
- 06 - The subscapular artery and its relationship with the brachial plexus. **GIL, Y.C.\***, H.J. YANG\*, H.S. WON\*, H.J. JI\*, DS JANG\*, I.H. JUNG, and H.Y. LEE. Department of Anatomy and Brain Korea 21 Project for Medical Science, Yonsei University College of Medicine, Seoul, KOREA.
- 07 - Inferior alveolar nerve paresthesia associated with endodontic therapy. **JERGENSON, Margaret A.**, Kenneth I. KNOWLES\*, and James H. HOWARD\*. Departments of Oral Biology and Endodontics, Creighton University School of Dentistry, Omaha, NE.
- 08 - Congenital short femur - a case study. **JEVOOR, Praful S.**, Butchi R. POTTURI\*, and Sharad M. ANTIN\*, Department of Anatomy & Orthopedics, J.N .Medical College, Belgaum, INDIA.
- 09 - Bilateral and congenital absence of radius. A case study. **JEVOOR, Praful S.**, Butchi R. POTTURI\*, and Sharad M. ANTIN\*. Department of Anatomy & Orthopedics, J.N. Medical College, Belgaum, INDIA.
- 10 - The jugular tubercle: microsurgical topographic anatomy. **KUNICKI\*, Jacek**, Bogdan CISZEK\* , Malgorzata BRZOZOWSKA\*, Paweł KRAJEWSKI \* and Kamil PIETRASIK. Departments of Anatomy, Subdivision of Neurotraumatology, Chair of Surgery, and Department of Forensic Medicine, Medical University of Warsaw, Warsaw, POLAND.
- 11 - Transverse facial artery and its relationship to the parotid duct and facial nerve. **LEE, Hyeyeon**, Heejoon YANG\*, Youngchun GIL\*, Hyungsun WON\*, and Dongsu JANG\*. Department of Anatomy and Brain Korea 21 Project for Medical Science, Yonsei University College of Medicine, Seoul, KOREA.

- 12 - Accurate adaptation of anatomical slices of the foot to correlated CT and MRI images by means of a stereotactic navigation system. **LONGATO\***, **Stefano**, Karl-Heinz KUENZEL\*, Felix AIGNER\*, Hubert MESSNER\*, Othmar GABER, Helga FRITSCH\*, Reto J. BALE\*, Thomas LANG\*, Thomas TRIEB\*, Michael RIEGER\*, Peter KOVACS\*, Werner JASCHKE\* and Sepp POISEL. University of Innsbruck, Institute of Anatomy and Histology, Department of Radiology I, Innsbruck, AUSTRIA.
- 13 - Biolistic transfection and morphological analysis of cultured sympathetic neurons. **LONGATO\***, **Stefano**, Michael PIMPL\*, Werner NINDL\*, Sepp POISEL, Felix AIGNER\* and Lars KLIMASCHEWSKI\*. Institute of Anatomy and Histology, University of Innsbruck, Innsbruck, AUSTRIA.
- 14 - The location and the morphology of the artery of Kugel in adult human heart. **LOUKAS, Marios**<sup>1</sup>, Mirek KIEDROWSKI<sup>1\*</sup>, Artur BARTCZAK<sup>1,3\*</sup>, Michal KAMIONEK<sup>1\*</sup>, Michal STACHURA<sup>1\*</sup>, Martin FUDALEJ<sup>2\*</sup>, Teresa WAGNER<sup>1\*</sup> <sup>1</sup> Department of Pathology, Institute of Rheumatology, <sup>2</sup> Department of Forensic service, Warsaw Medical University, <sup>3</sup> Department of Pathology, Warsaw Medical University, Warsaw, POLAND.
- 15 - The genetic basis of frontonasal dysplasia. **LOZANOFF, Scott**, and Brandeis M. McBRATNEY\*. Department of Anatomy and Reproductive Biology, University of Hawai'i School of Medicine, Honolulu, HI., and Department of Anthropology, Harvard University, Cambridge, MA.
- 16 - Gross topographical anatomy by dissection for basic surgical training candidates - development and implementation of a course at University of Sydney. **STEWART\***, **Fiona**<sup>1</sup>, Gregory J. LESLIE<sup>2\*</sup>, and Richard H. WEST<sup>3\*</sup>. <sup>1</sup>Department of Anatomy and Histology, University of Sydney, NSW, <sup>2</sup>Departments of Surgery - Liverpool, Bankstown, Dubbo Hospitals, N.S.W. and <sup>3</sup>Royal Australasian College of Surgeons, Melbourne, Victoria, AUSTRALIA. (Sponsored by B.R. MacPherson).

Wednesday, June 5th

- 17 - Anatomical analysis of the suprarenal arteries. **SAKAMOTO\***, **Hirokazu**, Keiichi AKITA\*, and Tatsuo SATO. Unit of Functional Anatomy, Tokyo Medical and Dental University School of Medicine, Tokyo, JAPAN.
- 18 - Tremors, chest pain, syncope, hoarseness, visual floaters are unusual clinical symptoms associated with vascular obstruction in patients with thoracic outlet syndrome (TOS): MRI / MRA. **SAXTON, Ernestina H\***, James D. COLLINS, Theodore Q. MILLER\*, Samuel S. AHN\*, and Alfred CARNES\*, Department of Radiology, University of California, Los Angeles, CA.
- 19 - Anatomical variations of the digastric muscle: a report of two cases. **SONEIRA, Carlos F.**, and William R. HAVILAND\*. Departments of Clinical Science and Physical Therapy, University of Wisconsin-La Crosse, La Crosse, WI.
- 20 - Intratumor vessel size distribution is a predictor of metastatic phenotype and tumor recurrence in patients with early stage squamous cell carcinoma of the oral cavity. THLIVERIS James A., **Mark G. TORCHIA\***, Richard NASON\*, Steven AHING\*. University of Manitoba, Departments of Human Anatomy and Cell Science, Surgery, and Oral Pathology, Winnipeg, MB, CANADA.
- 21 - Morphologic variations of the thyroid isthmus and its clinical significance. **WON H.S.\***, I.H. CHUNG\*, J.S. PARK\*, C.S. OH\*. Department of Anatomy and Brain Korea 21 Project for Medical Science, Department of General Surgery, Yonsei University College of Medicine, Seoul, Korea, Department of Anatomy, Sungkyunkwan University, School of Medicine, Suwon, KOREA.

8:00 a.m. **Opening Ceremonies /Remarks: Century Ballroom.**

*Daniel O. Graney, Ph.D.*  
AACA President, University of Washington

*Douglas J. Barnett, M.D.*  
Vice President for Health Affairs  
Nemours Eminent Scholar, UF COM

Wednesday, June 5th

*Stephen P. Sugrue*, Ph.D.  
Professor and Chairman  
Anatomy & Cell Biology, UF COM

*Lynn J. Romrell*, Ph.D.  
Professor, Anatomy & Cell Biology, Chair LOC  
Associate Dean for Medical Education, UF COM

8:45 a.m. **Bus departs *Doubletree Hotel and Conference Center for Accompanying Persons' Program*** -  
sightseeing trip to St. Augustine (full day trip)

8:30 a.m. **Scientific Platform Session I** - Robert M. DePhilip -  
Moderator. *Century Ballroom*.

\* *preceding the time of presentation indicates it is in the Predoctoral Award Competition.*

+ *preceding the time of presentation indicates it is in the Presidential Travel Award Competition.*

8:30 - Lapsus lingulae: the peculiarities of the lingual artery.  
**RICHARDS, Alan T.**, Neil S. NORTON, Steve FENTON, &  
Thomas H. QUINN. Departments of Surgery, Oral Biology, &  
Biomedical Sciences, Creighton University, Omaha, NE.

\*\*8:45 - Absence of left inferior thyroid artery - clinical implications.  
**SHERMAN\***, **Jonathan H.**, and Gene L. COLBORN.  
Medical College of Georgia and the Departments of Cell  
Biology, Anatomy and Surgery, Augusta, GA.

\*\*9:00 - The ansa pectoralis: anatomy and applications. **GRIFES\***,  
**Robert M.**, Robert M. SULLIVAN\*, and Gene L. COLBORN.  
Ross University School of Medicine, NY, and the Medical  
College of Georgia, Augusta, GA.

+9:15 - Fenestration of the superior medullary velum for the trapped fourth ventricle. **TUBBS, R. Shane\***, John C. WELLONS III\*,  
George SALTER, W. Jerry OAKES\*. Pediatric Neurosurgery,  
Children's Hospital, and Department of Cell Biology,  
University of Alabama at Birmingham, Birmingham, AL.

Wednesday, June 5th

- 9:30 - Microsurgical relationships between the veins of the posterior cranial fossa and the trigeminal nerve. **KUNICKI\***, **Jacek**, Bogdan CISZEK\* , and Pawel KRAJEWSKI\*. Department of Anatomy, Medical University of Warsaw, Poland, Subdivision of Neurotraumatology, Chair of Surgery, Department of Forensic Medicine, Medical University of Warsaw, Warsaw, Poland. (Sponsored by K. Pietrasik).
- 9:45 - Mandibular nerve block - anatomical study of a modified technique. **WEIGLEIN, Andreas H.**, Peter UMFAHRER\*, Gert SANTLER\*, and Klaus PREIDLER\*. Institute of Anatomy, School of Dentistry, MRI Institute, Karl-Franzens-University, Graz, AUSTRIA.
- 10:00 - Cranio-cervical anomalies (CCA) associated with vertebral artery dissection (VAD) in children (VAD); a clinical association. HASAN, Izhar<sup>1</sup>, **Simon WAPNICK**<sup>2</sup>, Michael S. TENNER<sup>3</sup>, Raj MURALI <sup>1</sup>and William T. COULDWELL<sup>1</sup>. Departments of <sup>1</sup>Neurosurgery, <sup>2</sup>Cell Biology and Anatomy, and <sup>3</sup>Radiology, New York Medical College, New York, NY.
- \*10:15 - Video demonstration of a dissection of the female pelvic lymphatics. **SATO, Tatsuo**, Hirokazu SAKAMOTO\*, Sadaaki HEIMA\*, Yoko TSUBOI\*, and Keiichi AKITA\*. Unit of Functional Anatomy, Tokyo Medical and Dental University Graduate School, Tokyo, JAPAN.
- 10:30 a.m. **Refreshment Break** – browse the posters and commercial exhibits – *Prefunction area, Hawthorne, Azalea and Magnolia Rooms.*
- 11:00 a.m. **Presidential Presentation:** “*Art and Beauty of the Body and Brain in Surgery*”. **Albert L. Rhoton Jr., M.D.**, R.D. Keene Family Professor and Chairman Emeritus, Department of Neurological Surgery, University of Florida COM. *Century Ballroom.*
- 12:00 p.m. **Lunch in Albert’s Restaurant. Browse the posters and commercial exhibits** - *Prefunction Area, Hawthorne, Azalea and Magnolia Rooms.*

**1:15 p.m. Scientific Platform Session II** - Jennifer K. Brueckner – Moderator. *Century Ballroom.*

- \*1:15 - Infundibulosinus partition, a new structure of the right ventricle. **LOUKAS Marios**<sup>1</sup>, Artur Bartczak<sup>1,3\*</sup>, Michal Kamionek<sup>1\*</sup>, Mirek Kiedrowski<sup>1\*</sup>, Michal Stachura<sup>1\*</sup>, Martin FUDALEJ<sup>2\*</sup>, and Teresa WAGNER<sup>1\*</sup>. <sup>1</sup> Department of Pathology, Institute of Rheumatology, <sup>2</sup> Department of Forensic service, Warsaw Medical University, <sup>3</sup> Department of Pathology, Warsaw Medical University, Warsaw, POLAND.
- \*1:30 - Angiographic manifestation and anatomical presence of the intramural LAD: surgical significance. **LACHMAN\***, **N<sup>1</sup>**, K.S. SATYAPAL<sup>2</sup>, and E.A. VANKER<sup>\*3</sup>. <sup>1</sup>Department of Human Biology, Faculty of Health, Technikon Natal; <sup>2</sup>Discipline of Anatomy, School of Basic and Applied Medical Science, Faculty of Health Sciences, University of Durban-Westville, Durban, SOUTH AFRICA.
- \*1:45 - Anatomical basis for a successful upper limb sympathectomy. **RAMSAROOP\***, **Lelika**, Bhugwan SINGH\*, Jaynathan MOODLEY\*, Prawesh PARTAB\*, and Kapil S SATYAPAL. Department of Anatomy, School of Basic and Applied Medical Sciences, University of Durban-Westville; Department of Surgery, Nelson R. Mandela School of Medicine, Durban, SOUTH AFRICA .
- \*2:00 - Innervation of anterior and posterior soleus: a three-dimensional model. **AGUR, Anne**, Eldon LOH\*, Victor NGTHOW-HING\*, Eugene FIUME\*, and Nancy McKEE\*. Departments of Surgery and Computer Science, University of Toronto, Toronto, ON, and Honda R&D Americas Inc., CANADA.
- \*\*2:15 - Effect of time postmortem on mechanical properties of immature swine tendons. **COTY\***, **Mark**, and Don R. HILBELINK. Department of Anatomy, University of South Florida, Tampa, FL.



Wednesday, June 5th

\*2:30 - Injuries caused by low level impacts to shoulders of 16 human cadavers: a comparative study of autopsy and radiologic findings. **BOLTE\***, **John H. III** and Margaret H. HINES. Department of Anatomy and Medical Education, The Ohio State University, Columbus, OH.

\*2:45 - Elastin point mutations in patients with inguinal hernia. **RODRIGUES, Consuelo J.**, Jin H. YOO\*, and Aldo J. RODRIGUES, JR. Department of Surgery, Faculty of Medicine, University of Sao Paulo, Sao Paulo-SP, BRAZIL.

3:00 p.m. **Refreshment Break** - browse the posters and commercial exhibits - *Prefunction Area, Hawthorne, Azalea and Magnolia Rooms.*

**3:30 p.m. Annual AACA Business Meeting** – *Century Ballroom.* (for all AACA members, including membership applicants)

4:30 p.m. Bus returns to *Doubletree Hotel & Conference Center* from Accompanying Person's Program trip

***Dinner – on your own.***

**Thursday, June 6, 2002** - All events at *Doubletree Hotel & Conference Center*

7:00 a.m. **Past President's Breakfast Meeting.** *Restaurant Private Dining Room.*

7:00 a.m. **Financial Affairs Committee/Treasurer Breakfast Meeting.** *Restaurant Dining Room.*

7:00 a.m. **Special Interest Group (part 1): Directors of Willed-Body Programs.** *Century Ballroom.* (All interested registrants are invited to attend).

7:00 a.m. **Registration – Conference Service Area.**  
**Commercial Exhibits** - *Hawthorne, Azalea and Magnolia Rooms*

Thursday, June 6th

7:00-8:00 a.m. **Continental Breakfast**

**Poster Session II - Hawthorne, Azalea and Magnolia Rooms**

*All posters listed below will be on display throughout Thursday, 7:30 a.m. to 4:30 p.m. Presenters of even-numbered posters must be present at their posters during the morning refreshment break, those presenting odd numbered posters must be present during the afternoon refreshment break.*

- 01 - Assessment of organized peer Instruction in the dental gross anatomy laboratory. **BRUECKNER, Jennifer K.** and Brian R. MacPHERSON. Instructional Technology Development Group, Department of Anatomy and Neurobiology, University of Kentucky, Lexington, KY.
- 02 - A teaching portfolio in clinical anatomy generated by student-faculty collaboration in a summer prosection program. **COOKE, John M.**, Anne M. GILROY, Jeanne D. KELLER, and Sandy C. MARKS. Department of Cell Biology, University of Massachusetts Medical School, Worcester, MA.
- 03 - The virtual human embryo project: digital image databases of representative serially-sectioned embryos from the Carnegie collection. **CORK, R. John\***, and Raymond F. GASSER. Cell Biology & Anatomy, LSU Health Sciences Center, New Orleans, LA.
- 04 - Opportunities for learning experiences in imaging and biomedical information management. **DISCHER\***, **William F.**, Elizabeth LOCKETT and Adrienne NOE. National Museum of Health and Medicine of the Armed Forces Institute of Pathology, Washington, D.C.
- 05 - Web-based learning materials that students actually use. **GEST, Thomas R.**, S. ANILESH\*, P. BALCENA\*, E. BATTS\*, J. BESS\*, W. BURKEL, W. CASTELLI\*, D. COOPER\*, G. CORTRIGHT, J. CURKENDALL\*, S. DEVANEY\*, G. DURKA-PELOK\*, B. EGELAND\*, N. ELKIN\*, D. FISHER\*, S. GONZALEZ\*, O. HANSHAW\*, D. KAY\*, S. KIM\*, A. RAOOF, M. ROUBIDOUX\*, N. SAUNDERS\*, J.

Thursday, June 6th

SMITH\*, D. SOMAND\*, D. SPEARMAN\*, T. STEIN\*, C. VEMURI\*, and J. WALTER\* Division of Anatomical Sciences, Department of Radiology, & Medical School Classes of 2001-2004, Ann Arbor, MI.

- 06 - Limbering up the limbs unit. **GILROY, Anne M.**, and John M. COOKE. Department of Cell Biology, University of Massachusetts Medical School, Worcester, MA.
- 07 - The development and assessment of an online learning objective answer database. **GOULD, Douglas J.** and Brian R. MacPHERSON. Instructional Technology Development Group, Department of Anatomy and Neurobiology, University of Kentucky, Lexington, KY.
- 08 - An integrated basic and clinical science course in the first four months of medical school: a three year perspective. **HANSEN, John T.**, and Nancy S. CLARK\*. Department of Neurobiology and Anatomy, and Department of Medicine, University of Rochester School of Medicine and Dentistry, Rochester, NY.
- 09 - Comparison of anonymous and non-anonymous responses in peer- and self-evaluations of dental students. MACIEJEWSKA\*, Izabela, Jacek KACZMAREK\*, and **Wojciech PAWLINA**. Medical University of Gdańsk, Poland and Department of Anatomy, Mayo Clinic and Mayo Medical School, Rochester, MN.
- 10 - Working effectively with a one-man Body Bequeathal Program. **MacPHERSON, Brian R.** Instructional Technology Development Group, Department of Anatomy and Neurobiology, University of Kentucky, Lexington, KY.
- 11 - The impact of formative feedback during the first-year clinical anatomy course. **MALAKHOVA, Olga**, Kyle E. RAREY, Robert VANDER GRIEND, and Lynn J. ROMRELL. Department of Anatomy and Cell Biology and Department of Orthopaedics. University of Florida, Gainesville, FL.
- 12 - The effects of an alternate dissection schedule on anatomy lab practical performance. **McWHORTER, David L.** and Pamela P. THOMAS. Department of Anatomy, The

Thursday, June 6th

University of Health Sciences College of Osteopathic  
Medicine, Kansas City, MO.

- \*13 - Benefits of the gross anatomy teaching assistant experience. **OCEL, Joseph J.**, Christopher M. WITTICH, Brian A. PALMER, Stephen W. CARMICHAEL, and Wojciech PAWLINA. Department of Anatomy, Mayo Clinic and Mayo Medical School, Rochester, MN.
- 14 - Five-card anatomy draw: a cumulative oral examination in the gross anatomy Laboratory. **RAREY, Kyle E.**, Olga MALAKHOVA, Robert VANDER GRIEND\*, and Lynn J. ROMRELL. Department of Anatomy and Cell Biology and Department of Orthopaedics, University of Florida, Gainesville, FL.
- 15 - Peer feedback and self-assessment in a first-year anatomy course. **RAREY, Kyle E.**, Olga MALAKHOVA, Lynn J. ROMRELL, and Robert VANDER GRIEND\*. Department of Anatomy and Cell Biology and Department of Orthopaedics. University of Florida, Gainesville, FL.
- 16 - Enhancing retention and recall of gross anatomy. **RAREY, Kyle E.**, Olga MALAKHOVA, Robert VANDER GRIEND\*, and Lynn J. ROMRELL. Department of Anatomy and Cell Biology and Department of Orthopaedics, University of Florida, Gainesville, FL.
- 17 - Tele-illustration: new technologies to enhance teaching. **SEIFERT, Mark F.**, and Ronald L. SHEW. Department of Anatomy and Cell Biology, Indiana University School of Medicine, Indianapolis, IN.
- 18 - Stepping forward regarding the integration between the clinical skills and gross anatomy courses. **STEFAN, Cristian**, William T. BETZ \*, and Anca M. STEFAN \*. Department of Basic Sciences and Department of Family Medicine, Pikeville College School of Osteopathic Medicine, Pikeville, KY.

- 19 - Creation of a technologically enhance educational environment: augmentation of existing resources fore teaching human gross anatomy and embryology. **WALKER, James J.**, J. Leslie BOOTH\*, James F. KIMBROUGH\*, and Amy S. RECKTENWALD\*. Lafayette Center for Medical Education, Purdue University and Indiana University School of Medicine, West Lafayette, IN.
- 20 - Introduction of clinical procedures to freshman medical students using fresh cadaveric material. **WHITWORTH\***, **Richard H. Jr.**, Tracey LEGROS\* and Peter DEBLIEUX\*. Department of Cell Biology & Anatomy and Department of Emergency Medicine, LSU Health Sciences Center, New Orleans, LA. (Sponsored by W.J. Swartz).
- 21 - T.I.P.S.: A computerized study guide for the temporal, infratemporal, and pterygopalatine regions. **WINESKI, Lawrence E.**,<sup>1</sup> Perry RIGGINS,<sup>2\*</sup> Rebecca A. SEALAND.<sup>2\*</sup> Department of Anatomy & Neurobiology<sup>1</sup>, Division of Information Technology Services<sup>2</sup>, Morehouse School of Medicine, Atlanta, GA.

8:00 a.m. **Scientific Platform Session III** - Todd R. Olson - Moderator, *Century Ballroom*.

- 8:00 - The Cadaver as the First Patient: Providing cadaver's medical history to students will enhance clinical relevance of anatomy and contribute positively to students' learning of medicine. ANILESH, Smitha\*, **Ameed M. RAOOF**, Tom GEST, William BURKEL, Geraldine DURKA-PELOK\*, and Debra KAY\*. Division of Anatomical Sciences, Department of Radiology, University of Michigan, Ann Arbor, MI.
- 8:15 - Web-based dissection videos. **BURKEL William E.**, Thomas GEST, Parrish BALCENA\*, Gerald CORTRIGHT, Jay CURKENDALL\*, Geraldine DURKA-PELOK\*, Neal ELKIN\*, Sun-Kee KIM\*, Joshua SMITH\*, David SOMAND\*, and Jonathan WALTER.\* Division of Anatomical Sciences and Medical School Classes of 2003 and 2004 The University of Michigan Medical School, Ann Arbor, MI.

- 8:30 - Fourth year gross anatomy electives: clinically relevant courses for clinically prepared students. **STEIN\*, Tamara A.**, Caren M. STALBURG\*, Thomas R. GEST, and William E. BURKEL. Division of Anatomical Sciences and Department of Obstetrics and Gynecology, University of Michigan Medical School, Ann Arbor, MI.
- \*8:45 - When less is more: reducing lectures to promote active learning. **GEST, Thomas R.**, S. ANILESH\*, P. BALCENA\*, E. BATTS\*, J. BESS\*, W. BURKEL, W. CASTELLI\*, D. COOPER\*, G. CORTRIGHT, PhD, J. CURKENDALL\*, S. DEVANEY\*, G. DURKA-PELOK\*, B. EGELAND\*, N. ELKIN\*, D. FISHER\*, S. GONZALEZ\*, O. HANSHAW\*, D. KAY\*, S. KIM\*, A. RAOOF, M. ROUBIDOUX\*, N. SAUNDERS\*, J. SMITH\*, D. SOMAND\*, D. SPEARMAN\*, T. STEIN\*, C. VEMURI\*, and J. WALTER\* Division of Anatomical Sciences, Department of Radiology, & Medical School Classes of 2001-2004, Ann Arbor, MI.
- \*9:00 - Team building and peer teaching in a gross anatomy course for physical therapy students. **PETTERBORG, Larry J.** School of Physical Therapy, Presbyterian Campus, Texas Woman's University. Dallas, TX.
- 9:15 - Teaching the physical examination using interactive web technologies: the Ohio State project. **CAIN, Timothy J.\***, Cynthia KREGGER\*, Douglas KNUTSON\* Chris FISH\*, Chris FINNERAN\*, Curtis STEWART\* and Larry GABEL,\* 2MD – Medical Multimedia Design, Departments of Internal Medicine and Family Medicine, College of Medicine & Public Health, The Ohio State University, Columbus, OH. (Sponsored by R.M. DePhilip)
- 9:30 - Is there still a need for the use of wet specimens in the medical neuroscience course? **STEFAN, Cristian.** Department of Basic Sciences, Pikeville College School of Osteopathic Medicine, Pikeville, KY.
- 9:45 - The use of handouts and clinical cases in a gross anatomy course for allied health professions. **SONEIRA, Carlos F.**, and William R. HAVILAND\*. Departments of Clinical Science

Thursday, June 6th

and Physical Therapy, University of Wisconsin-La Crosse,  
La Crosse, WI.

8:45 a.m. **Bus departs Doubletree Hotel & Conference Center for Accompanying Person's Program.**  
Sightseeing trip to Silver Springs (3/4 day).

10:00 a.m. **Refreshment Break** - browse the posters and commercial exhibits - *Hawthorne, Azalea and Magnolia Rooms.*

**10:30 a.m. Scientific Platform Session IV** - Todd R. Olson - Moderator. *Century Ballroom.*

\*10:30 - Integrating computers and technology with dissection in the human gross anatomy laboratory: improving efficiency in the modern laboratory setting. **REEVES, Rustin E.**, John E. ASCHENBRENNER\*, Rouel S. ROQUE\*, Robert J. WORDINGER\* and Harold J. SHEEDLO\*. Department of Pathology and Anatomy, University of North Texas Health Science Center, Fort Worth, TX.

10:45 - Cadaver-based invasive procedures training for medical students. **PATTERSON, Hugh A.** and Jeffery A. TABAS\*. School of Medicine, Pathology, and Department of Anatomy, Emergency Department, San Francisco General Hospital, University of California, San Francisco, CA.

11:00 - Predictors of success in the anatomical science portion of a doctoral-level physical therapy curriculum. **SCOTT, Samuel A.**, A. Joseph THRELKELD, and Anthony E. KINCAID. Department of Physical Therapy, Creighton University, Omaha, NE.

11:15 - Animation of human foregut development. **BOLENDER, David L.**, Mark J. HOLTERMAN, Greg BLEW\*, and Joi HOLCOMB\*. Department of Cell Biology, Neurobiology and Anatomy, Medical College of Wisconsin, Milwaukee, WI, and Department of Surgery and School of Biomedical and Health Information Sciences, University of Illinois at Chicago, IL.

Thursday, June 6th

- 11:30 - Embryology distance learning: calling all hands.  
**HOLTERMAN, Mark J.**, David L. BOLENDER, Maurice PESTICELLI\*, Gregory BLEW\*, Elizabeth LOCKETT, Adrienne NOE, Charles PAIDAS\*, Jeffery PENTECOST\* and Mark PULLEN\*. University of Illinois at Chicago, Chicago, IL, Medical College of Wisconsin, Milwaukee, WI, National Museum of Health and Medicine, George Mason University, Fairfax, VA, Johns Hopkins Medical School, Baltimore, MD, and Oregon Health Sciences University, Portland, OR.
- 11:45 - Expanding anatomy in the medical curriculum: clinical anatomy for the third year surgery clerkship. **JONES, Kenneth H.**, and Robert M. DePHILIP. Department of Anatomy & Medical Education, The Ohio State University, Columbus, OH.
- 12:00 p.m. **Lunch in Albert's Restaurant** - Browse the poster and commercial exhibits - *Hawthorne, Azalea and Magnolia Rooms.*
- 1:00 p.m. Conference Service Desk moves to *Century Ballroom* entrance.
- 1:15 p.m. Scientific Platform Session V** - Douglas J. Gould - Moderator. *Century Ballroom.*
- 1:15 - Computational anatomy: agenda for a newer frontier.  
**TRELEASE, Robert B.** Department of Pathology and Laboratory Medicine, UCLA School of Medicine, Los Angeles, CA.
- 1:30 - Two-dimensional computerized modeling using plastinated human brain sections for Access Grid instructional delivery.  
**LOZANOFF, Scott**, Beth K. LOZANOFF\*, Mircea-Constantin SORA\*, Julie ROSENHEIMER, Marcus KEEP\*, Joshua JACOBS\*, Stanley SAIKI\*, Dale ALVERSON\*. Department of Anatomy and Reproductive Biology, University of Hawai'i School of Medicine, Honolulu, HI; SURFdriver Software, Kailua, HI; Department of Anatomy, Anatomical Institute, Vienna University, Vienna, Austria; Department of Medicine, University of Hawai'i School of Medicine, Honolulu, HI; Tripler Army Medical Hospital,



Thursday, June 6th

Honolulu, HI, Department of Pediatrics and Obstetrics and Gynecology, University of New Mexico School of Medicine, Albuquerque, NM.

- 1:45 - Web-based materials for the enhancement of anatomical instruction - a project supported by the U.S. Department of Education, Fund for the Improvement of Secondary Education. **HENSON, O'Dell W., Jr.**, Jennifer M. BURGOON\* and Noelle A. GRANGER. University of North Carolina School of Medicine, Department of Cell and Developmental Biology, Chapel Hill, NC.
- 2:00 - NeuroTime, a computer-assisted learning tool for the neuroanatomy laboratory. **SEVERSON, Arlen R.**, and Donna J. FORBES\*. University of Minnesota School of Medicine Duluth, Department of Anatomy and Cell Biology, Duluth, MN.
- 2:15 - Construction and use of simple devices to create movement in anatomic videography. **ACLAND, Robert D.** University of Louisville, Louisville, KY.
- 2:30 p.m. **Refreshment Break** - Browse the posters and commercial exhibits - *Hawthorne, Azalea and Magnolia Rooms*
- 3:00 p.m. Educational Affairs Symposium** - *Century Ballroom.*  
(All interested registrants are invited to attend).
- Introduction. **Michael A. Casey.**
  - Ancient anatomy (Galen and before). **Vid Persaud.**
  - Medieval and renaissance anatomy. **Michael A. Casey.**
  - Progress in anatomy between 1600 and 1900. **Robert D. Acland.**
  - 20<sup>th</sup> century anatomy and the future. **Arthur F. Dalley.**
  - Summary. **David Porta.**
  - *general discussion*

Thursday, June 6<sup>th</sup>

- 3:30 p.m. **Bus returns to *Doubletree Hotel & Conference Center* from Accompanying Person's day trip.**
- 6:45 p.m.** Gathering at "Two-Bits" Lounge (cash bar)
- 7:30 p.m.** **Annual AACA Banquet** and presentation of Honored Member Award to *Robert D. Acland*, Professor of Surgery, Division of Plastic and Reconstructive Surgery, University of Louisville. *Century Ballroom*.

**Friday, June 7, 2002** - All events at *Doubletree Hotel & Conference Center*

- 7:00 a.m. **Registration – Conference Service Area**  
**Commercial Exhibits** - *Hawthorne, Azalea and Magnolia Rooms*
- 7:00 a.m. **Meeting of Educational Affairs Committee** (All interested are invited to attend) - *Dogwood Room*.
- 7:00 a.m. **Special Interest Group (part II - if needed): Directors of Willed-Body Programs** *Century Ballroom*. (All interested registrants are invited to attend).
- 7:00-8:00 a.m. **Continental Breakfast**
- 8:00 a.m. Scientific Platform Session VI** - Anne M. Gilroy  
- Moderator, *Century Ballroom*.
- 8:00 - Sources of anatomical knowledge in the works of Frida Kahlo. **PHILO, Ron** and Charleen M. MOORE\*. Department of Cellular and Structural Biology, The University of Texas Health Science Center at San Antonio, San Antonio, TX.
- 8:45 - Have probe, will travel: adventures in teaching anatomy and planning a context-appropriate anatomy curriculum in Kathmandu. **DALLEY, Arthur F., II**. Department of Cell and Developmental Biology, Vanderbilt University Medical Center, Nashville, TN.

Friday, June 7th

- 9:00 - Procedures performed by family physicians in hospital practice in a developing country -an evaluation of clinical anatomy competence. BOON, Johannes M<sup>1</sup>., **Peter H. ABRAHAMS**<sup>2</sup>, Johannes H. MEIRING<sup>1</sup>, and Theo WELCH<sup>3\*</sup>. <sup>1</sup> Department of Anatomy, Faculty of Health Sciences, University of Pretoria, Pretoria, SOUTH AFRICA <sup>2</sup> Kigezi International School of Medicine, Girton College, Cambridge, UNITED KINGDOM , St George's University Grenada, WEST INDIES <sup>3</sup> Kigezi International School of Medicine, Queens' College, Cambridge, UNITED KINGDOM.
- 9:15 - Studying topographical anatomy?- a reason why! **FIEGL, Georg**. Institute of Anatomy, Karl-Franzens University, Graz, AUSTRIA.
- 9:30 - A comparison of dissections with 3-D CT images of cadaver faces subjected to impact by baseballs. **PORTA, David J.**<sup>1-2</sup>, Jeryl C. JONES<sup>\*3</sup>, Joel D. STITZEL Jr.<sup>\*4</sup>, Joseph M. CORMIER<sup>\*4</sup>, William J. HURST<sup>\*4</sup>, and Stefan M. DUMA<sup>\*4</sup>. <sup>1</sup> Department of Biology, Bellarmine University, Louisville, KY. <sup>2</sup> Department of Anatomical Sciences and Neurobiology, University of Louisville School of Medicine, Louisville, KY. <sup>3</sup> Virginia-Maryland Regional College of Veterinary Medicine, Blacksburg, VA, <sup>4</sup> Virginia Tech Impact Biomechanics Laboratory, Blacksburg, VA.
- 9:45 - Clinico-morphological study of lumbrical muscles in the human hand. **AJMANI, Madan.L.** Department of Anatomy, All India Institute of Medical Sciences, New Delhi, INDIA. (Sponsored by B.R. MacPherson).
- 10:00 a.m. **Refreshment Break** - Browse the posters and commercial exhibits - *Hawthorne, Azalea and Magnolia Rooms*
- 10:30 a.m. Scientific Platform Session VII** - Brian R. MacPherson - Moderator, *Century Ballroom*.
- 10:30 - The descending branch of the inferior gluteal artery and the posterior femoral cutaneous nerve: basic anatomy, inter-dependence and relevance for flap surgery. WINDHOFER\*, Christian, Erich BRENNER, Christoph PAPP\*, and

Friday, June 7th

**Bernhard MORIGGL.** University of Innsbruck, Institute of Anatomy and Histology, Innsbruck, Department of Plastic and Reconstructive Surgery, Hospital Barmherzige Brueder, Salzburg, AUSTRIA.

- 10:45 - Restoration of motor function of the deep peroneal nerve by direct nerve transfer of branches from the tibial nerve. An anatomical study. **BODILY\***, **Kale D.**, Robert J. SPINNER, and Allen T. BISHOP\*. Mayo Medical School, Department of Orthopedics and Department of Neurosurgery, Mayo Clinic and Mayo Foundation, Rochester, MN.
- 11:00 - Surgical procedures compromise the vascular supply to the brachial plexus causing Thoracic Outlet Syndrome (TOS): MRI / MRA. **COLLINS, James D.**, Ernestina H. Saxton, Theodore Q. Miller\*, Samuel S. Ahn\*, and Alfred Carnes\*. Department of Radiology, University of California, Los Angeles, CA.
- 11:15 - Determining the relation of the axillary nerve to the shoulder joint capsule from an arthroscopic perspective. **PRICE\***, **Matthew R.**, Edward TILLET\*, Stephen G. NETTLETON, and Robert D. ACLAND. Department of Anatomical Sciences and Neurobiology, and Department of Orthopaedics, University of Louisville School of Medicine, Louisville, KY.
- 11:30 - A practical light embalming technique for use in the surgical fresh tissue dissection laboratory. **ANDERSON, Stephen D.** Body Bequeathal Program, University of Louisville School of Medicine, Louisville, Louisville, KY.
- 11:45 Adjourn
- 1:00 p.m. **Meeting of new Council - Dogwood Room.**

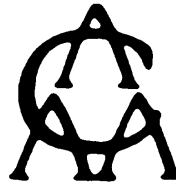Saturday, June 8th

**Saturday, June 8, 2002** - AACA and University of  
Florida College of Medicine jointly sponsored  
Postgraduate Course

*"Clinical Anatomy of the Skull Base and High Resolution MRI"*

Evelyn F. and William L. McKnight Brain Institute  
University of Florida College of Medicine

*Separate registration fee required*  
*For a description of the program, please see the following page*



## **19<sup>th</sup> Annual Meeting Postgraduate Course**

# **Clinical Anatomy of the Skull Base and High Resolution MRI**

Saturday, June 8, 2002

Evelyn F. and William L. McKnight Brain Institute  
University of Florida College of Medicine  
Gainesville, FL

Jointly sponsored by  
University of Florida College of Medicine and the  
American Association of Clinical Anatomists

### **CME ACCREDITATION**

This activity has been planned and implemented in accordance with the Essential Areas and Policies of the Accreditation Council for Continuing Medical Education (ACCME) through the joint sponsorship of the University of Florida College of Medicine and the American Association of Clinical Anatomists. The University of Florida College of Medicine is accredited by the ACCME to provide continuing medical education for physicians.

### **DESIGNATION OF CME CREDIT**

The University of Florida College of Medicine designates this educational activity for a maximum of 2.25 hours in Category 1 credit towards the AMA Physician's Recognition Award. Each physician should claim only those hours of credit that he/she actually spent in the educational activity.

## ***Schedule of Postgraduate Program***

- 7:30 - 7:45 a.m. Shuttle bus departs *University of Florida Doubletree Hotel and Conference Center* for the Evelyn F. and William L. McKnight Brain Institute of the University of Florida
- 7:45 - 8:30 a.m. Registration/Check-In and continental breakfast on the 1<sup>st</sup> floor lobby
- 8:30 - 9:45 a.m. Overview of McKnight Brain Institute - facilities available and advances being made at the Institute – Dr. William G. Luttge, Executive Director.

Three groups of attendees will rotate between 45 minute sessions in the Human Patient Simulator (HPS), Surgical Research and Training Laboratory (SRTL), and Advanced Magnetic Resonance Imaging and Spectroscopy (AMRIS).

**Sessions begin at 10:00 a.m., 11:15 a.m., and 12:15 p.m.  
The course will end at 1:00 p.m.**

- 10:00 - 10:45 a.m. Team 1 - HPS  
Team 2 - AMRIS  
Team 3 - SRTL
- 10:45 - 11:15 a.m. Break
- 11:15 - 12:00 p.m. Team 1 - SRTL  
Team 2 - HPS  
Team 3 - AMRIS
- 12:15 - 1:00 p.m. Team 1 - AMRIS  
Team 2 - SRTL  
Team 3 - HPS
- 1:00 p.m. Program adjourns. Bus will return participants to the *University of Florida Doubletree Hotel and Conference Center*

## **ABSTRACTS**

ACLAND, Robert D. University of Louisville, Louisville, KY. Construction and use of simple devices to create movement in anatomic videography.

In making a series of video presentations on human anatomy special devices were needed to allow movement of the dissected specimen. The movements to be made included rotation around both vertical and horizontal axes, linear motion, and movement of one part of the specimen relative to the other. Simple hand-operated devices were created to produce these movements. To maximize the instructional value of any movement certain production values should be respected. These include the timing of movement to coincide with the spoken narrative; graded acceleration and deceleration to introduce and conclude a movement; and the avoidance of confusion when movements are made in more than one plane or axis. The presentation will be illustrated with video showing the devices in action. The lessons learned in using these devices may be of value to educators creating movement in computer based programs.

ACLAND, Robert D. University of Louisville, Louisville, KY. Progress in anatomy between 1600 and 1900.

Macroscopic anatomy was one of the hottest sciences between 1600 and 1800. By the early 1800s almost every region and system of the human body had been minutely and accurately described, within the limits of investigation by naked eye or hand lens. The rate of progress was remarkable, considering the impediments to progress that existed. During the 1600s the lead in anatomical progress moved from Italy to northern Europe, with Leyden as the epicenter. There and in Paris anatomic art, essential for the spread of knowledge, reached its highest level of refinement in the 1700s. During the 1800s the focus of anatomic interest shifted strongly toward microscopic anatomy, and investigation of the central nervous system. We will recall some of the achievements of anatomists both well known and obscure who saw things first, who made things clear, and who left us lasting visible reminders of the spirit of their age. Along with heroes we will recall villains including plagiarists, grave robbers and murderers.

AGUR, Anne, Roger LEEKAM\*, Aaron FENSTER\*, and Nancy MCKEE\*. Departments of Surgery and Medical Imaging, University of Toronto and The J.P. Robarts Research Institute, University of Western Ontario, ON, CANADA. The study of muscle architecture using three-dimensional ultrasound.



## Abstracts

The purpose of this study was to investigate the feasibility of collecting muscle architectural data using 3-D ultrasound. The architecture of the human gastrocnemius and soleus muscles has been documented in a cadaver dissection (Agur et al. 1997) and a 2-D ultrasound study (Chow et al. 2000). Based on the cadaveric study the optimal scanning planes for the architecturally distinct regions of each muscle were determined. Each area was scanned with the muscle relaxed and contracted (full voluntary plantar flexion). An ATL HDI5000 real time ultrasound scanner with variable frequency, 5-10 MHz, linear array transducer and 3D reconstruction software (Fenster et al. 2001) was used for the study. A total of 8 sites were examined in the relaxed and contracted state. The ultrasound scans appear as 3-D blocks of tissue (256x256x200 pixels). The scanned block of tissue can be sectioned from any of its surfaces at any angle. This enables the investigator to be able to determine the optimum plane for visualization and documentation of the muscle fiber bundles, aponeuroses and septa within the muscle. These morphological features can be traced throughout the block and their location confirmed from many different planes. 3-D ultrasound may provide a novel approach to the study of human muscle. It enables scanning a block of tissue that can be later manipulated to ensure that the optimal scanning plane is used to collect data, from a specific site. In contrast, traditional 2-D ultrasound provides one image per scan that cannot be further manipulated. This new technology may facilitate better understanding of the normal and pathological muscle.

AGUR, Anne, Eldon LOH\*, Victor NG-THOW-HING\*, Eugene FIUME\*, and Nancy McKEE\*. Departments of Surgery and Computer Science, University of Toronto, Toronto, ON, Honda R&D Americas Inc., ON, CANADA. Innervation of anterior and posterior soleus: a three-dimensional model.

Innervation of skeletal muscle, including soleus (Sekiya, 1991; Schultz 1972), has been studied using 2-D methodologies such as sketches and photos of the dissected nerves. Difficulty in depth discrimination after removal of the non-neural tissues and the complexity of overlapping branches make it difficult to trace the nerves. In this study, new computer and digitization technologies will be used to allow 3-D visualization of nerves. The external surface of the soleus was digitized with a Microscribe 3D-X digitizer. Individual nerve branches were exposed in short segments using a surgical microscope. Each segment of the nerve was digitized. Dissection and digitization were repeated until the individual nerve branches

## Abstracts

could no longer be followed with a dissecting microscope (X10-40). The digitized data of the external surface of the muscle, of the outline of each of the parts of the muscle and of the nerve branches were entered into our B-spline program. A manipulatable three-dimensional representation of the cadaveric soleus specimen and its intramuscular innervation was generated. Using this model the complexity of nerve distribution in the human soleus muscle was reconstructed. The nerve branches can be viewed individually or in groups, from any angle, within the volume of each muscle part. The anterior soleus was innervated by two main branches distributed medially and laterally within the muscle belly. The posterior soleus was innervated by five main branches. Communicating branches were numerous. 3-D modeling provides a comprehensive approach to the study of neuromuscular interrelationships and may lead to a better understanding of muscle function.

AIGNER\*, Felix, Gerd BODNER\*, Friedrich CONRAD\*, Helga FRITSCH\*, Stefano LONGATO\* and Sepp POISEL. University of Innsbruck, Institute for Anatomy, Department of Radiology and Department of Surgery, University of Innsbruck Medical Center, Innsbruck, AUSTRIA. The influence of the upper rectal artery and its branches on recent hemorrhoidectomy techniques.

Since 1995 the HAL (hemorrhoidal artery ligation) is used for submucosal ligation of hemorrhoidal arteries with the aid of an ultrasonographic transducer (Morinaga et al. 1995). The success of this technique depends on the submucosal course of these arterial branches. Our investigations showed that there are even branches of the upper rectal artery which pierce the rectal wall in a way impossible to be reached by this ligation method. By means of 3 macroscopic preparations of adult pelves, 10 cutting series through fetal and newborn pelves after embedding in epoxy-resin and 35 perineal invivo ultrasonographs on proctologic patients and young students we found that these branches course outside the muscle layer of the rectal wall in craniocaudal direction. They enter the rectal wall above the pelvic diaphragm to supply the hemorrhoidal plexus. Respecting the hemorrhoidal reappearance one should consider that there exist further plexus supplying branches of the upper rectal artery which cannot be reached by HAL, but may be detected by ultrasonography and should be carefully treated.

## Abstracts

AJMANI, Madan.L\*. Department of Anatomy, All India Institute of Medical Sciences, New Delhi, INDIA. (Sponsored by B.R. MacPherson). Clinico-morphological study of lumbrical muscles in the human hand.

Much of the versatility of the human hand depends upon its intrinsic musculature. The lumbrical muscles constitute an important part of the intrinsic musculature of hand. Together with interossei their significance in the delicate balance of digital movements is disproportionate to their size. An attempt has been made to study the variations of the attachments, form and nerve supply of the lumbricals that could have some bearing on surgical problems of hand. The study was done in dissection of 68 hands and forearm regions taken from 34 adult cadavers of both sexes. Their attachments, form and component parts were ascertained. The distribution pattern of the muscular branch of median and ulnar nerves were studied in detailed. Significant variations were recognized in the innervation of the lumbricals of the hands. The clinical relevance of these variations emerged in the nerve injured patient with apparent function distal to the level of injury. Both at the initial evaluation of injury and for planning reconstruction surgery of such patients, the possibility of these variant patterns must be considered.

ANDERSON, Stephen D. Body Bequeathal Program, University of Louisville School of Medicine, Louisville, KY. A practical light embalming technique for use in the surgical fresh tissue dissection laboratory.

Surgeons using a fresh tissue dissection laboratory need specimens with tissue color and texture as close as possible to those of the living body. Completely unembalmed specimens kept in a cooler remain in good condition only for a few days, then decay rapidly. Unembalmed specimens can be frozen for later use, but freezing harms their texture, and decay is suspended only for as long as they remain frozen. Since 1998 we have used a method of "light embalming", adapted from funeral home techniques, on over 200 cadavers used in our Fresh Tissue Dissection Laboratory. Lightly embalmed cadavers can be kept in a cooler for at least six weeks before use, with negligible loss of tissue quality and color. Once dissection is begun, the cadavers remain in excellent condition, free from odor, for at least two further weeks. Light embalming overcomes the practical problems seen with completely unembalmed specimens, avoids the use of freezing, and extends the range of activities that can be planned in a fresh tissue laboratory. This paper

## Abstracts

presents details of the method, and shows the condition of tissues at various time intervals following preservation. We assume that light embalming does not kill all transmissible pathogens.

ANILESH, Smitha\*, Ammed M. RAOOF, Tom GEST, William BURKEL, Geraldine DURKA-PELOK\*, and Debra KAY\*. Division of Anatomical Sciences, Department of Radiology, University of Michigan, Ann Arbor, MI. The Cadaver as the first patient: providing cadaver's medical history to students will enhance clinical relevance of anatomy and contribute positively to students' learning of medicine.

It has been proven that early exposure of medical students to clinical concepts is an essential component of their education. The relevance of basic science knowledge to the medical profession has been regularly examined and emphasized in current medical curricula. The provision of the cadaver's medical history to students constitutes a significant early exposure to clinical reasoning and promotes the concept of professionalism. Students will learn how to analyze and correlate clinical data with anatomical and pathological findings. The implementation of this technique doesn't require expensive resources or equipment. Dissection is a required part of the core anatomy courses, and what is needed is data collection and posting in a database. The information was made available to all students during the course by posting it on the web. Students were able to examine and follow up cadavers with unique findings. The usefulness of this technique was assessed through the official end-of-the-course evaluation form, and by a separate questionnaire distributed to students. An array of interesting data was collected. The majority of students believed that the technique was helpful in re-enforcing the clinical relevance of dissection and in relating to the cadaver as a patient.

ARCHIE\*, Victor C., Guy J.F. JULLIARD\*, Robert PARKER\* Steve P. LEE\*, and Michael T. SELCH\*. UCLA Department of Radiation Oncology UCLA Medical Center, Los Angeles, CA. (Sponsored by James Collins). Intramedullary melanoma: a case report and review of the literature.

Less than 40 cases of intramedullary melanoma have been reported in the literature. Here we report a 49 yo male with midthoracic back pain that underwent workup with imaging revealing an isointense lesion at T11. Intraoperatively the patient was noted to have a melanotic lesion arising from the parenchyma of the cord. The lesion was subtotally resected. After appropriate immunohistochemical

## Abstracts

stains, the lesion was classified as malignant melanoma. The patient received 50.4Gy in 1.8Gy fractions. His back pain completely resolved. Pathologically intradural melanomas may be confused with melanocytomas, or melanotic schwannomas which have a much more indolent course. This has led some authors to conclude that this disease is less aggressive than primary melanoma of other sites. However, these lesions may be highly aggressive. Mitotic indices and MIB-1 staining have proven useful in this regard.

BODILY\*, Kale D., Robert J. SPINNER, and Allen T. BISHOP\*. Mayo Medical School, Department of Orthopedics and Department of Neurosurgery, Mayo Clinic and Mayo Foundation, Rochester, MN. Restoration of motor function of the deep peroneal nerve by direct nerve transfer of branches from the tibial nerve. An anatomical study. Stretch injuries to the common peroneal nerve, common at the time of varus knee injury, result in significant morbidity due to loss of ankle dorsiflexion. Reconstruction is often unsuccessful because of the severity of the injury, its relatively proximal location and the usual need for lengthy sural nerve grafts. When such procedures fail an ankle-foot orthosis is required. Tendon transfer frequently fails to eliminate the need for bracing and may result in late hindfoot valgus and arthritis. The objective of this study was to determine the anatomical feasibility of an alternative reconstruction, consisting of nerve transfer of motor branches from the tibial nerve to the deep peroneal nerve. This technique bypasses the zone of injury, obviates the need for an intercalary nerve graft and, decreases regeneration time by reconstructing the nerve as close as possible to the end-organ. All of these advantages should improve the results of primary nerve reconstruction. In 10 cadaveric limbs, the branching pattern, length, and diameter of motor branches of the tibial nerve in the proximal leg were characterized. Nerve transfer of each of these motor branches was then simulated to the proximal deep peroneal nerve. A consistent, reproducible pattern of innervation was seen with minor variability. Branches to the flexor hallucis longus and flexor digitorum longus muscles were determined to be adequate for direct nerve transfer in all specimens without interpositional graft based on their diameter and length. Other branches, including those to the tibialis posterior, popliteus, gastrocnemius, and soleus muscles were not consistently adequate. This study confirms the anatomical feasibility of direct nerve transfer using nerves to toe flexors as a treatment option to restore ankle dorsiflexion.

## Abstracts

BOLENDER, David L., Mark J. HOLTERMAN, Greg BLEW\*, and Joi HOLCOMB\*. Department of Cell Biology, Neurobiology and Anatomy, Medical College of Wisconsin, Milwaukee, WI, and Department of Surgery and School of Biomedical and Health Information Sciences, University of Illinois at Chicago, IL. Animation of human foregut development.

The spatial relationships among organ forming primordia are constantly changing with time during embryonic development. Visualizing such complex rearrangements is a challenge for many medical students. Reconstructing these complex interactions using animation provides a means by which students can segment the developmental process in order to understand it. Digitized sections of human embryos from the Carnegie Collection were provided by the Human Developmental Anatomy Center. Foregut derivatives and cardiovascular structures visible in the sections were annotated and the data reconstructed into three dimensional animations. Annotation data from embryos at Carnegie Stages 12-18 were morphed into a sequential presentation showing foregut and cardiovascular structures. Changes in the length, shape and flexure of the foregut are visible as one progresses through the different stages. Changes in the cardiovascular structures as well as their relationship to the foregut structures can also be observed. Supported by a contract from the National Library of Medicine.

BOLTE\*, John H. III and Margaret H. HINES. Department of Anatomy and Medical Education, The Ohio State University, Columbus, OH. Injuries caused by low level impacts to shoulders of 16 human cadavers: a comparative study of autopsy and radiologic findings.

The purpose of these studies was to add to the body of knowledge currently being employed by physicians and automotive engineers in anticipating the kind and degree of shoulder injury that might occur in side impact automobile crashes. Sixteen unembalmed human cadavers were impacted with a constant mass at variable speeds within 48 hours of death. Physical, X Ray and Magnetic Resonance examinations were done both before and after the impacts. At completion of each test shoulder autopsies were performed.. Autopsy best identified joint looseness or instability, Magnetic Resonance soft tissue and X Ray bone injuries. Low speed impact tests frequently result in injuries of soft tissue and bones. Instabilities of the acromioclavicular and sternoclavicular joints occurred in 81 % of the subjects. Fractures of the distal one third of the clavicle, found in 39 % of the cadavers were the most frequent bone injuries while

## Abstracts

tears of the rotator cuff or labrum ,11 % were the most frequently found soft tissue injuries. Additional work on shoulder injuries is currently underway. (Sponsored by Grant No.DTNH22-97-D-08001 from the National Highway Traffic Safety Administration).

BOON, Johannes M<sup>1</sup>., Peter H. ABRAHAMS <sup>2</sup>, Johannes H. MEIRING <sup>1</sup>, and Theo WELCH <sup>3\*</sup>. <sup>1</sup> Department of Anatomy, Faculty of Health Sciences, University of Pretoria, Pretoria, SOUTH AFRICA <sup>2</sup> Kigezi International School of Medicine, Girton College, Cambridge, St. George's University Grenada, WEST INDIES<sup>3</sup> Kigezi International School of Medicine, Queens' College, Cambridge, UNITED KINGDOM. Procedures performed by family physicians in hospital practice in a developing country -an evaluation of clinical anatomy competence.

The safe and successful performance of office, surgical and emergency procedures as well as procedures for radiological imaging demand a working and yet specific knowledge of anatomy. The aim of this study was to determine a) which clinical procedures are performed in South Africa; b) the frequency, importance and comfort of performance; c) difficulties and complications encountered; d) the role of clinical anatomy competency in reducing difficulties and complications and improving confidence; e) the selection of 15 procedures for which the relevant clinical anatomy was determined and a state of the art clinical anatomy training program developed. To this aim a questionnaire was completed by 102 doctors at various hospitals on 57 procedures relevant to family practice in South Africa. After analysis of the questionnaires the following procedures were selected which were regarded as most problematic from an anatomical viewpoint: Central venous catheterization, cricothyroidotomy, pericardiocentesis, great saphenous vein cutdown, oro/naso tracheal intubation, lumbar puncture, appendectomy, cesarean section, reduction of uncomplicated forearm fractures, ectopic pregnancy surgery, epistaxis management, rectal examination, proctoscopy and sigmoidoscopy, knee joint aspiration, wrist and digital nerve block and obstetric ultrasound. A referenced knowledge base was developed by an extensive literature search under the following headings: Indications, contraindications, step by step procedure, anatomical pitfalls and complications. This was expanded to develop a Virtual Procedures Clinic, an interactive multimedia package, a small section of which will be demonstrated. (Sponsored by Association of Commonwealth Universities-Scholar grant ZACA 2000-135 and Medical Research Council, South Africa).

## Abstracts

BRUECKNER, Jennifer K. and Brian R. MacPHERSON. Instructional Technology Development Group, Department of Anatomy and Neurobiology, University of Kentucky, Lexington, KY. Assessment of organized peer instruction in the dental gross anatomy laboratory.

Learning by teaching others has long been recognized as a highly effective pedagogical technique by the educational research community. The use of organized peer instruction has recently been introduced into medical gross anatomy laboratory instruction in the form of "rotating" dissections. During each class period, only a fraction of the students at each laboratory station perform the assigned dissection. At the end of class, the dissectors demonstrate key structures to their non-dissecting peers; these roles alternate each class period so that each student has the dual opportunity to teach and to learn. To date, this rotating approach to laboratory instruction has not been described in a dental gross anatomy curriculum and is the focus of the present study. During each laboratory period, only three of the six dental students in each laboratory team performed the specified regional dissection. The non-dissectors attended the laboratory session only during the last 30 minutes of class and learned the day's material from their peers. Survey data indicated that over 90% of the dental students were satisfied with the rotating dissection approach. When asked how the approach affected their mastery of lab material, 44% of the class indicated that this approach enhanced their laboratory learning, while 40% felt that it had no effect. Of the students who felt that the rotating dissection impeded their learning, most attributed the problems to their preference for dissecting every day or to the quality of the student dissector presentations. 89% of the class, however, indicated that the quality of peer presentations in their group was satisfactory or better. The majority of the class indicated that they enjoyed both learning from and instructing their peers.

BURKEL William E., Thomas GEST, Parrish BALCENA\*, Gerald CORTRIGHT, Jay CURKENDALL\*, Geraldine DURKA-PELOK\*, Neal ELKIN\*, Sun-Kee KIM\*, Joshua SMITH\*, David SOMAND\*, and Jonathan WALTER.\* Division of Anatomical Sciences and Medical School Classes of 2003 and 2004 The University of Michigan Medical School, Ann Arbor, MI. Web-based dissection videos.

We have made changes to our gross anatomy course to increase opportunities for self-directed active learning. During the last two years we created digital movies of each of the anatomical dissections for our gross anatomy course. Dissection procedures



## Abstracts

and dissections were recorded with a Canon XL1 digital video camera and a Kodak DC290 digital camera. The video segments were edited using Apple QuickTime Pro, iMovie, Media Cleaner Pro software, and several PowerMac computers. Summary still images were captured from the videos, labeled in Photoshop and reinserted as appropriate for review purposes. The movies were compressed for playback as streaming media using the Sorenson video codec. The movies were then delivered via our web courseware using a Mac OS X streaming video server. The students were encouraged to use the videos as prelaboratory preparation and especially at the location where they are most useful, within the gross anatomy laboratories during dissection. A questionnaire was used to harvest student opinions of the effectiveness of the dissection videos as learning tools. Student response to the videos has been extremely positive and they found them useful in a variety of ways depending upon their learning style. Faculty found them useful in that all students received the same dissection instructions and they did not have to go over procedures with each dissecting group.

CAIN, Timothy J.\*, Cynthia KREGGER\*, Douglas KNUTSON\* Chris FISH\*, Chris FINNERAN\*, Curtis STEWART\* and Larry GABEL,\*  
2MD – Medical Multimedia Design, Departments of Internal Medicine and Family Medicine, College of Medicine & Public Health, The Ohio State University, Columbus, OH. (Sponsored by Robert M. DePHILIP) Teaching the physical examination using interactive web technologies: the Ohio State project.

Teaching physical examination skills to a large number of students with a limited number of physician teachers often places strain on already over-extended faculty. Two-hundred and ten medical students matriculate each year at the Ohio State University College of Medicine & Public Health. Ensuring that this large group of students is exposed to a common set of normal and abnormal physical exam findings and techniques is a logistical challenge. In response we have developed an interactive, web-based primer to introduce medical students to the fundamental principles, techniques and findings of the physical examination. We have focused on seven content areas and have used Macromedia Flash and streaming technologies to create a computer-based resource to supplement traditional learning strategies. Examples will be shown to illustrate how this multimedia-rich site was developed and deployed. Specifically, we will show how Flash was used to mimic a blood pressure assessment, a pulmonary auscultation, a fundoscopic exam, among other techniques. In addition, examples of annotated

## Abstracts

digital video vignettes of common exam techniques will be demonstrated. An on-line demonstration is available at <http://medicine.osu.edu/exam> (Supported by the U.S. DHHS Bureau of Health Professions, HRSA (1-D05-PE-80150), the OSU Department of Family Medicine and College of Medicine & Public Health).

COLLINS, James D., Ernestina H. Saxton, Theodore Q. Miller\*, Samuel S. Ahn\*, and Alfred Carnes\*. Department of Radiology, University of California, Los Angeles, CA. Surgical procedures compromise the vascular supply to the brachial plexus causing Thoracic Outlet Syndrome (TOS): MRI / MRA.

Bilateral magnetic resonance imaging (MRI) displays anatomic sites of brachial plexus compression. The MRA cross-references the MRI in brachial plexopathy. Pathology, trauma and surgery alter fascial planes. Postsurgery patients present with symptoms of thoracic outlet syndrome. MRI and MRA display postsurgical changes in landmark anatomy that compromise the vascular supply of the brachial plexus, particularly the venous return. The patients selected for this presentation were imaged on a 1.5 Tesla magnet (Signa; General Electric Medical Systems, Milwaukee, WI) in the coronal, transverse, transverse oblique, and sagittal planes, 4 mm slice thickness, 512 x 256 matrix size. With saline water bags to enhance the signal to noise ratio. Abduction external rotation of the extremities and 2D TOF MRA sequences were obtained. This presentation display sites of vascular compression in patients who have undergone surgical procedures that caused TOS: heart transplantation complicated by renal shutdown requiring arterio-venous shunt placement; grafting of the subclavian artery to the common carotid; anastomosis of the axillosubclavian artery to the carotid; resection of the aberrant subclavian artery with graft to ascending aorta; mastectomy with lymph node dissection and silicone implantation. Venous obstruction impeded arterial blood flow and triggered increased intracranial, intrathoracic and intraabdominal pressures with TOS symptoms.(Clin.Anat.8:1-16).

COOKE, John M., Anne M. GILROY, Jeanne D. KELLER, and Sandy C. MARKS. Department of Cell Biology, University of Massachusetts Medical School, Worcester, MA. A teaching portfolio in clinical anatomy generated by student-faculty collaboration in a summer prosection program.

For the past twenty years, our department has employed medical students in a summer prosection program. Initiated as a program to

## Abstracts

support curricular innovation, the program now functions as a vital source of materials needed to support our teaching programs in clinical anatomy. Students are hired during the summer between their first and second years to work on a variety of faculty-supervised projects. Although the major focus of the program is the first-year medical course in human anatomy, the prosected specimens are used extensively in other courses involving clinical anatomy. In addition to cadaver dissections, students have prepared computer-assisted learning modules, instructional videotapes, supplements to the course syllabus, anatomical illustrations, and anatomical models. In addition to providing advanced training to students and residents, the program has also provided important opportunities for faculty development and scholarship. A description of the program including budget will be provided and a portfolio of projects presented.

CORK, R. John\*, and Raymond F. GASSER. Cell Biology & Anatomy, LSU Health Sciences Center, New Orleans, LA. [The virtual human embryo project: digital image databases of representative serially-sectioned embryos from the Carnegie collection.](#)

Images of the serial sections of the best, normal, human embryos in the Carnegie collection are being assembled into databases. One database for each of the Carnegie stages and substages will be produced. These stages cover the period of development when all the body systems are laid down and many major malformations can occur. Sets of section images are digitally restored, labeled and aligned, and incorporated into a HTML document that can be viewed on any computer with an Internet browser. Section images are displayed at different magnifications together with a measuring bar. An image of the whole mount embryo indicates the plane and level of each section. Each section is labeled with the most current embryological terminology. Drawings and photographs derived from previously studies of each specimen are also included, as are animations of the 3D surface reconstructions and fly-through animations of the aligned sections. Databases are being made available on DVDs and CDs, and will eventually be accessible through our website; [virtualhumanembryo.lsuhscc.edu](http://virtualhumanembryo.lsuhscc.edu) . The stage 13 database is already available, and the databases for stages 10 and 12 are scheduled for completion by spring 2002. (Supported by grant #R01-HD37811 from NICHD.)

## Abstracts

COTY\*, Mark, and Don R. HILBELINK. Department of Anatomy, University of South Florida, Tampa, FL. Effect of time postmortem on mechanical properties of immature swine tendons.

Computed surface modeling of anatomical structures is now easily accomplished. Introduction of functionality to these computed models for purposes such as surgical simulation or finite element analysis requires incorporation of accurate biomechanical properties. Significant variability in mechanical testing techniques, storage methods, and species variation exists in the published literature. As a result, consistent, validated biomechanical properties data for most soft tissues does not exist. The focus of this project was to examine the effect of postmortem storage time on Ultimate Tensile Strength (UTS) and Young's Modulus (YM) of porcine digital flexor tendons. One hundred and fifty two failure tests were conducted on fresh digital flexor tendons from immature swine (mean age of 71 days) at 19 discrete time intervals over ten hours postmortem. Statistically significant ( $P < .001$ ,  $\alpha = .05$ ) degradation in UTS was observed. By 10 hours, Ultimate Tensile Strength had declined 4.7% when compared to the 30 minute postmortem group. Linear regression analysis of UTS revealed a degradation line with a slope of -0.012. No statistically significant degradation ( $P = .68$ ) was observed in YM during the ten hour elapsed time postmortem. This study shows that postmortem time elapse must be considered when estimating in-vivo mechanical properties of tendon using tensile testing techniques.

DALLEY, Arthur F., II. Department of Cell and Developmental Biology, Vanderbilt University Medical Center, Nashville, TN. Have probe, will travel: adventures in teaching anatomy and planning a context-appropriate anatomy curriculum in Kathmandu.

An idea originating in 1999 with a vision of national self-sufficiency in quality and cost effective health care, formalized in 2000, has resulted in the creation of the new Kathmandu University Medical School (KUMS) in Nepal. Kathmandu University itself established in 1991 as a non-profit, privately-managed but publicly oriented academic institution, providing undergraduate and graduate education in engineering, management, arts, education, and natural sciences has already become recognized for its commitment to academic excellence. The first medical (MBBS) class of 43 students was accepted and began classes in September, 2001. The 5½-year curriculum initially devised in conjunction with Harvard University and endorsed by the Nepal Medical Council places a heavy emphasis on public health. Admission priorities include female students, permanent residency in remote rural areas, and

## Abstracts

marginalized ethnic groups. This grass-roots effort has acquired 27 hectares of land for building a medical school complex, including quarters for faculty and hostels for students, and eventually a university hospital. All funding and materials have been donated. Faculty services for the training of both local faculty and students have been donated primarily by the US (Harvard University mainly) and Switzerland. Grant assistance from the Canadian Government has enabled some KUMS faculty to visit Canadian medical schools. This presentation will document my experiences volunteering as visiting faculty at KUMS during April '02, with the intention of recruiting additional volunteer faculty and donations of books and resources from the AACA membership and meeting participants.

DALLEY, Arthur F., II. Department of Cell and Developmental Biology, Vanderbilt University Medical Center, Nashville, TN. History of gross anatomy: 20<sup>th</sup> century anatomy and the future.

This epic production (20<sup>th</sup> Century Anatomy) will be reviewed and criticized. Cast (in order of appearance): *Author educators*: Henry Gray (still), J Sobotta, DJ Cunningham, Sir Henry Morris, JCB Grant, Henry Hollinshead, Barry Anson, Russell Woodburne, Ronan O'Rahilly, Eduard Pernkopf, Harold Ellis, RMH McMinn, Keith Moore, Frank Netter; *Dissector educators*: David Bassett, Bari Logan, J Rohen/C Yokochi, Robert Acland. Acts: *Major educational events*: Flexner and GPEP reports. *Methodologies in anatomical education*: functional anatomy, clinical anatomy, sectional anatomy, radiological anatomy, virtual anatomy. *Trends in medical education*: disciplines vs. systems, problem-based learning (PBL), case-based learning (CBL), computer-aided instruction (CAI). *Terminology*: BNA, Nomina Anatomica, Terminologia Anatomica. *Legal/legislative events*: Uniform Anatomical Gift Act, capitation vs. NIH funding, the decline and demise of Departments of Anatomy, elimination of anatomical training and teaching experiences as components of graduate education, body brokers. *Impact of technology*: radiology, anatomical transparencies (books/projection), 35 mm slides, Bassett Stereoscopic Atlas©, copiers, planar medical imaging (CT, MRI, US), VCR/Acland's Video Atlas©, PCs, A.D.A.M.©, the internet, fiber optics (endoscopy), multimedia presentation, the Visible Human Project©, Microsoft Power Point©. Conclusion: the cadaver loses the pre-eminent, nearly solo role in anatomical education it has enjoyed since the time of Vesalius, taking on a strong supporting cast, allowing the observation and recreation of anatomy in the living and outside the laboratory. Previews and coming attractions: audience participation/speculation requested.

## Abstracts

DISCHER\*, William F., Elizabeth LOCKETT and Adrienne NOE. National Museum of Health and Medicine of the Armed Forces Institute of Pathology, Washington, D.C. Opportunities for learning experiences in imaging and biomedical information management.

This poster is a discussion of student contributions, from ninth grade to graduate level studies, to the Human Developmental Anatomy Center's (HDAC) mission. Discussed in this poster are the plans for future projects involving student internships. Specifically cited in this poster are students that have contributed to auto-translation of medical journals, web-site design, annotating embryological images and computer models of early human development. High school internship programs from various school districts have assigned their students to the HDAC and after a full semester the students' work has been reviewed by the sending school district. The students' responses to the HDAC work environment and the guidance of the HDAC staff have met with the approval of the administrators of the high school internship programs in all of the sending school districts repeatedly over the past eight years. A graduate degree granting accredited university has awarded one of its graduate students a masters degree based on his masters thesis project which the student performed here at the HDAC.

FIEGL, Georg. Institute of Anatomy, Karl-Franzens University, Graz, AUSTRIA. Studying topographical anatomy?- a reason why!

A strong combination of anatomical knowledge and clinical topics is an excellent basis for the education of medical students. The Institute of Anatomy Graz offered a simple but early introduction into regional anaesthesia during two dissection courses of 2<sup>nd</sup> year students in 2000 and 2001. In 2000 189 students trained the femoral nerve block in the femoral triangle in small groups (4-8 students) with a time limit of one hour. In 2001 89 students trained the stellate ganglion block. After an introduction on the use of regional anaesthesia and a repetition of the anatomy of the anatomical region, the students trained the nerve blocks. To control the success of the nerve block, we did a flap dissection on the cadaver. After the training, the students evaluated the workshop. 83,07% (2000, femoral nerve block\*) of the students respectively 80,9% (2001, stellate ganglion block\*\*) highly agreed that the workshop improved topographical knowledge. 91,01% (\*) and 93,26% (\*\*) respectively, highly agreed that this workshop increases the recognition of clinical and anatomical correlation. 94,71% (\*) and 95,51% respectively (\*\*) would attend more workshops of this kind. With such workshops, the

## Abstracts

students are motivated to study topographical anatomy more conscientiously.

FIRBAS, Ulrike\*, Sonja HOCHMEISTER\*, and Wilhelm FIRBAS. Institute of Anatomy, University of Vienna, Vienna, AUSTRIA. A comparative study of fluid secreting systems in sensory organs.

A comparison of the mammalian stria vascularis and the avian tegmentum vasculosum in the inner ear and of the ciliary body in the eye revealed similarities as well as important differences in the epithelia and the capillary systems. The production of endolymph and aqueous humour is connected to various functions in the sensory organs and fluid dysbalance can lead to serious disorders like Meniere's disease and glaucoma. Basal labyrinth and cellular junctions of epithelial cells are typical for active fluid transport. The secretory epithelias have a neighbourhood to pigmented cells. In the ciliary body the pigment epithelium is below the unpigmented secretory epithelium. Under the stria vascularis numerous melanocytes can be found in the spiral ligament. The arrangement and number of capillaries have great similarities, but in the stria vascularis they penetrate into the epithelium. There are important differences in the composition of the fluids and in the number of autonomous nerve fibres, which are numerous in the ciliary body. Important details are demonstrated with illustrations and diagrams of the ultrastructure and microcirculation of the three organs.

FISHER, Brian D. \* and WALJI, Anil H. Division of Anatomy, Faculty of Medicine and Dentistry, University of Alberta, Edmonton, AB, CANADA. A further investigation using Immunocytochemical localization of Cathepsin B in injured muscle cells.

Rat's gastrocnemius muscle showed increased protein degradation (+75-115%) at 48 h after traumatic injury. Injured muscle showed increased cathepsin B activity. In situ hybridization, cathepsin B mRNA localized to mononuclear cell infiltrate in injured muscle and only background levels of hybridization were observed either over muscle cells in injured tissue or in uninjured muscle. Light microscopy and in situ hybridization: in injured muscle, only scattered silver grains in a random pattern were observed and this was not different from muscle sections which were treated with an unrelated antisense riboprobe, CTP-glucagon, or with a sense transcript of cathepsin B cDNA. In injured gastrocnemius, cathepsin B mRNA localized to the area of tissue damage. Dense clusters of silver grains were seen over and around mononuclear cell infiltrates localized in the widened interstitial space and around the damaged

## Abstracts

myofibrils. Immunoelectron microscopy: at 2 days post trauma specific myofibril damage was noted in cross section. Both in the control and injured muscles, muscle cells were scarcely stained with anti-cathepsin B and this was not different from sections in which the primary antibody had been deleted. In the interstitial space, cells of the mononuclear cell infiltrate were stained and gold particles and were specifically localized over lysosomal-structures. Combined with the in situ hybridization, these results suggest that the observed increase in cathepsin B activity and mRNA in injured muscle reflect the invasion into damaged muscle of phagocytes rich in this proteinase. Further the enzymes secreted by the cells of the inflammatory infiltrate are likely to be a major participant in protein catabolism associated with local trauma.

GEST, Thomas R., S. ANILESH\*, P. BALCENA\*, E. BATTS\*, J. BESS\*, W. BURKEL, W. CASTELLI\*, D. COOPER\*, G. CORTRIGHT, PhD, J. CURKENDALL\*, S. DEVANEY\*, G. DURKAPELOK\*, B. EGELAND\*, N. ELKIN\*, D. FISHER\*, S. GONZALEZ\*, O. HANSHAW\*, D. KAY\*, S. KIM\*, A. RAOOF, M. ROUBIDOUX\*, N. SAUNDERS\*, J. SMITH\*, D. SOMAND\*, D. SPEARMAN\*, T. STEIN\*, C. VEMURI\*, and J. WALTER\* Division of Anatomical Sciences, Department of Radiology, & Medical School Classes of 2001-2004, Ann Arbor, MI. When less is more: reducing lectures to promote active learning.

Three years ago, we initiated a long-term plan to change the focus of the medical gross anatomy course from a relatively passive, faculty-centered, lecture-intensive learning environment to active, student-centered learning. We wanted to decrease our emphasis on lectures and increase emphasis on laboratory instruction and self-paced active learning based on web materials. Lecture length was reduced 50%. Concurrently, we developed a course web site that covered the required course materials comprehensively. It integrates the dissection manual, dissection videos, anatomy tables, clinical cases, practical and written practice questions, radiology, and surface anatomy. In the labs, we installed 16 networked computers, providing 1 computer for every 2 lab tables. The results of our educational efforts have been gratifying. For the past two years, we recorded the best average course scores within the past decade. The gross anatomy course rating for the past year is the highest within the past ten years. And despite some fears that faculty evaluations would suffer due to our reduced-lecture format, the average of overall faculty evaluations for the past three years has been the highest within the past decade.



## Abstracts

GEST, Thomas R, S. ANILESH\*, P. BALCENA\*, E. BATTS\*, J. BESS\*, W. BURKEL, W. CASTELLI\*, D. COOPER\*, G. CORTRIGHT, J. CURKENDALL\*, S. DEVANEY\*, G. DURKAPELOK\*, B. EGELAND\*, N. ELKIN\*, D. FISHER\*, S. GONZALEZ\*, O. HANSHAW\*, D. KAY\*, S. KIM,\* A. RAOOF, M. ROUBIDOUX\*, N. SAUNDERS\*, J. SMITH\*, D. SOMAND\*, D. SPEARMAN\*, T. STEIN\*, C. VEMURI\*, and J. WALTER\* Division of Anatomical Sciences, Department of Radiology, & Medical School Classes of 2001-2004, Ann Arbor, MI. Web-based learning materials that students actually use.

During the past 4 years, we have developed a web site for our medical gross anatomy course. This site is a comprehensive resource for all of the required course materials. It consists of an integrated presentation of the dissection manual, dissection videos, anatomical tables, clinical cases, cadaver medical histories, practice written and practical questions, radiology, and surface anatomy. The response to the web site has been extremely positive. In a survey of learning styles, the web site materials were judged as the most valuable resource for learning gross anatomy. On the course evaluation, the web site overall was judged 4.89, where 4 is "Valuable" and 5 is "Very valuable" in terms of learning gross anatomy. One component of the web site, the dissector answers, scored a perfect "5", or "Very valuable", in response to the question, "How valuable were the web-based dissector answers." We will report on our continuous efforts in development and refinement of this learning tool.

GIL, Y.C.\*, H.J. YANG\*, H.S. WON\*, H.J. JI\*, DS JANG\*, I.H. JUNG, and H.Y. LEE. Department of Anatomy and Brain, Korea 21 Project for Medical Science, Yonsei University College of Medicine, Seoul, KOREA. The subscapular artery and its relationship with the brachial plexus.

This study was performed to clarify the branches of the SSA and its relationship with brachial plexus. The data was recorded in 185 sides of 95 Korean cadavers. In 13.5%, the SSA was not observed and the circumflex scapular artery only arose from the third part of AA and the thoracodorsal artery (TDA) arose from the 1st or 2nd part of it. The SSA was originated from the third part of the AA (62.7%), from the second part (20%) or from the first part (3.8%). When it arose from the third part, it ran under the ulnar and the radial nerves, however it crossed over the medial cord or the ulnar nerve when it arose from the other part. In 41.6%, it made a common trunk with a circumflex humeral artery. In 30.3%, SSA had a common trunk with a

## Abstracts

lateral thoracic artery. This was more frequent when it arose from the 1st or 2nd part. The SSA was divided into two branches after running a mean distance of  $2.21 \pm 1.56$  cm. The main trunk gave branches to the subscapularis (60.5%), the descending trunk of the SSA had branches to the serratus anterior (75.7%) or to the subscapularis (15.7%) except TDA (100%).

GILROY, Anne M., and John M. COOKE. Department of Cell Biology, University of Massachusetts Medical School, Worcester, MA. Limbering up the limbs unit.

The study of limb anatomy presents some unique challenges. Students feel the burden of memorization of muscle names and functions but often fail to appreciate the complex nature of common movements. Yet the familiarity of the limbs makes it amenable to innovative learning modalities that are difficult to apply in other units. In an effort to complement the memorization of factual information with an understanding of synergistic function we have incorporated an optional interactive component into the unit's laboratory experience. Towards the end of the limbs study small groups of students are assembled in the medical center fitness center. This facility, utilized as a private fitness club and rehabilitation center, is located in close proximity to the anatomy labs and is available to us through the generosity of its administration. During a half-hour workout session the students identify specific active muscles and muscle groups. The sessions are fast-paced and fun, combining exercises from physical therapy, bodybuilding and martial arts training. The combination of intellectual stimulation and physical challenge makes this type of clinical correlation a memorable learning experience.

GOULD, Douglas J. and Brian R. MacPHERSON. Instructional Technology Development Group, Department of Anatomy and Neurobiology, University of Kentucky, Lexington, KY. The development and assessment of an online learning objective answer database.

The objective of the present study was to create and evaluate an on-line learning objective answer database. The goal of the answer database was to make information about, and/or answers to, learning objectives that students were provided with in their lecture notes available to them via the Internet. Our hypothesis was that students would: 1) be pleased that the answers to the learning objectives were provided in a fully accessible format; 2) that student performance would not suffer as a result of having the answer

## Abstracts

database readily available to them; and 3) that less instructor time would be spent discussing issues/questions in a repetitive fashion. The answer database was created using Filemaker Pro™4.1 and housed on Macintosh computers in faculty member's offices. The effectiveness of the database was evaluated over a 3-year period and compared with the previous 3-year period in which the database was not used. Evaluation methods included student and faculty surveys and numerical assessments of overall course and database rating and average course grades. Results indicate that there is no significant difference in student satisfaction and grades with or without the database, while faculty time spent in office hours and answering routine questions is decreased.

GRIFES\*, Robert M., Robert M. SULLIVAN\*, and Gene L. COLBORN. Ross University School of Medicine, NY, and the Medical College of Georgia, Augusta, GA. The ansa pectoralis: anatomy and applications.

Clinical reports of neurotization procedures for the upper limb have drawn attention to the need for clarification of the anatomy of the pectoral nerves. We are recommending that the name "ansa pectoralis" be adopted for the loop between them. Data from sixty-five brachial plexuses and pectoral regions provided the bases for this study. The lateral and medial pectoral nerves arise often from the anterior divisions of the superior, middle, and inferior trunks of the plexus – not from the cords, as described in many texts. The lateral pectoral nerve divides into a superficial branch and a deep branch. The superficial branch supplies only the clavicular head of pectoralis major. The deep branch supplies the sternal head of pectoralis major and forms a loop with the medial pectoral nerve which we have named the ansa pectoralis. The ansa pectoralis is formed immediately distal to the origin of the thoracoacromial artery in 100% of our cases, not in the first part of the axillary artery as described in most texts. Branches from the ansa supply both pectoral muscles.

HANSEN, John T., and Nancy S. CLARK\*. Department of Neurobiology and Anatomy, and Department of Medicine, University of Rochester School of Medicine and Dentistry, Rochester, NY. An integrated basic and clinical science course in the first four months of medical school: a three year perspective.

Rochester's Double Helix Curriculum (DHC) weaves basic and clinical sciences through all four years like the intertwining strands of the double helix molecule. In the DHC, the clinical strand occupies

## Abstracts

30% of the curricular time in Years I and II, and 70% in years III and IV, with the basic science strand representing the converse. In the Fall of Year I, our basic science interdisciplinary course in anatomy, embryology, histology and physiology (Human Structure and Function) and our introductory course in the basic interview, history, and physical examination skills (Introduction to Clinical Medicine) run concurrently over a 14-week period. Basic science material is presented each morning (lecture, PBL, labs), Monday through Friday, and clinical skills are learned two afternoons each week (demonstrations and applied workshops), Monday and Wednesday. On Friday afternoons, both courses share an Integration Conference that is centered on a patient presentation and is team-taught by basic and clinical science faculty. Examinations are administered every three weeks and include integrated questions (MCQ, essay, lab identifications and OSCEs) encompassing both HSF and ICM material. The HSF course focuses on basic science learning in a clinical context and the ICM course focuses on acquisition, management, organization, and presentation of medical information related to the history and physical exam. This concurrent learning establishes a concrete foundation in clinical problem solving which reinforces the application of scientific principles to clinical problems. Student feedback suggests that integration enhances learning and facilitates a holistic view of clinical problems unimpeded by the usual disciplinary boundaries.

HASAN, Izhar<sup>1</sup>, Simon WAPNICK<sup>2</sup>, Michael S. TENNER<sup>3</sup>, Raj MURALI<sup>1</sup> and William T. COULDWELL<sup>1</sup>. Departments of <sup>1</sup>Neurosurgery, <sup>2</sup>Cell Biology and Anatomy, and <sup>3</sup>Radiology, New York Medical College, New York, NY. Craniocervical anomalies (CCA) associated with vertebral artery dissection (VAD) in children(VAD); a clinical association.

VAD in children has been noted relatively infrequently in the literature. We recently reported the occurrence of VAD in a child with Klippel Feil syndrome<sup>1</sup>. This report prompted a literature review by the authors who found 80 children with VAD. It was noted that the commonest underlying predisposing factor was the presence of an associated CCA in 23. This presentation discusses the clinical features and presentation of these children who had both VAD and CCA. A Medline search with bibliographic review was performed for publications that reported patients <18 years old with posterior circulation ischemia, VAD, vertebral artery occlusion, and CCA. (1966-2001. We did not include vertebral artery disease unless there was unequivocal evidence of VAD or the report indicated that

## Abstracts

the underlying vascular abnormality was considered to be due to VAD. From a total of 1028 references, 23 cases were identified in 16 separate reports. Males (20) outnumbered females (3) (87%,  $p < 0.0001$ ), and ages ranged from 6 months to 17 yrs. The mean age at the time of presentation was similar in children with underlying CCA to the mean age of those without known CCA (8.8 vs 9.1 yr). Fourteen (61%) patients provided a history of neck or head trivial trauma or a sport related injury. The initial clinical presentation was preceded by a distinct episodic phenomenon in 14 (61%) patients. The duration of premonitory symptoms ranged from one day to several. The associated anomalies in children presenting with both CCA and VAD will be presented. X-ray of the cervical spine was performed in 17/23 (74%) with a flexion extension view obtained in 5/23 (22%). The most common site of VAD anomaly was in the C1-C2 vertebral level region 20/23 (87%). Unequivocal diagnosis of VAD (intimal flap) was confirmed in 9 (39%). Complete recovery was achieved in 4/12 (33%) patients who underwent surgical intervention. Conclusions: 1. A distinct neurovascular syndrome characterized by repeated transient ischemic attacks (TIA) due to CCA and VAD in children is identified. 2. The common cranio-cervical anomalies associated with VAD in children are arcuate foramen, Os odontoid related abnormalities, and Klippel-Feil syndrome. 3. In children presenting with CCA, the presence of VAD should be considered in the differential diagnosis of any new onset of unexplained posterior fossa infarction. 4. Children diagnosed with posterior circulation stroke, should have appropriate radiological studies including a neck x-ray, and MRA/ angiogram to rule out VAD secondary to CCA. Reference,

HENSON, O'Dell W., Jr., Jennifer M. BURGOON\* and Noelle A. GRANGER. University of North Carolina School of Medicine, Department of Cell and Developmental Biology, Chapel Hill, NC. Web-based materials for the enhancement of anatomical instruction - a project supported by the U.S. Department of Education, Fund for the Improvement of Secondary Education.

At the University of North Carolina School of Medicine three web-based projects have been designed to enhance the teaching of gross anatomy in medical, dental and allied health programs. The first is the production of 2-4 minute close captioned video modules that show steps used for exposure of structures in specific regions. These modules can be downloaded and arranged to match the sequences required for individual labs and/or courses. In the dissection instructions, attention is directed to landmarks and

## Abstracts

relationships that will be useful for the identification and understanding of structures in sections. The second project provides links between dissection and interpretation of structures in transverse body sections (CT, MRI and VHP images). Sequential transverse images through specific regions (in QT stacks) can be downloaded and studied. Instructions direct the user to the landmarks and associated structures that were observed in the cadaver. The third project deals with semitransparent 3D images of complex bony structures (simulated radiographs) that can be rotated to understand how images change as a function of angle and superimposition of parts. The impact of these projects on student learning is being evaluated by anatomy curricula at four universities: North Carolina, Morehouse, Dartmouth and San Diego State. (Sponsored by grant P116B010181 from the FIPSE foundation).

HOLTERMAN, Mark J., David L. BOLENDER, Maurice PESTICELLI\*, Gregory BLEW\*, Elizabeth LOCKETT, Adrienne NOE, Charles PAIDAS\*, Jeffery PENTECOST\* and Mark PULLEN\*. University of Illinois at Chicago, Chicago, IL, Medical College of Wisconsin, Milwaukee, WI, National Museum of Health and Medicine, Washington, DC, George Mason University, Fairfax, VA, Johns Hopkins Medical School, Baltimore, MD and Oregon Health Sciences University, Portland, OR. Embryology distance learning: calling all hands.

Embryology education is limited in many Universities and Medical Schools around the world for a number of reasons including the lack of trained qualified educators, limited curriculum time and a shortage of usable teaching tools. We have assembled a team of embryologists, clinicians, artists and computer networking experts to lay the groundwork for a technology supported solution to this problem. Starting with embryos of the Carnegie Collection supplied by the Human Development Anatomy Center, we have prepared a series of models and animations that depict many of the steps of the developmental process. We can then use these teaching tools in a variety of ways: 1) they can be distributed for a use by existing embryology educators in their respective embryology courses, 2) existing embryology courses can participate with other schools in a team teaching approach over the Next Generation Internet, 3) and entire course can be taught remotely. We plan to provide a demonstration of this approach to embryology education using network connections and our teaching tools. In addition, we will invite participation from AACA members to help in this educational endeavor.

## Abstracts

JERGENSON, Margaret A., Kenneth I. KNOWLES\*, and James H. HOWARD\*. Departments of Oral Biology and Endodontics, Creighton University School of Dentistry, Omaha, NE. Inferior alveolar nerve paresthesia associated with endodontic therapy.

Several cases of paresthesia in the distribution area of the inferior alveolar nerve (IAN) were noted in endodontic patients of the dental clinic at the Creighton University School of Dentistry. Paresthesia related to endodontic involvement or treatment of mandibular teeth has been reported in the literature, most commonly related to cases involving the mandibular premolar and molar teeth. This study was undertaken to determine the frequency with which this paresthesia occurs and to examine the role of the anatomy of the IAN. The study took the form of a review of the records of the endodontic department at the CU School of Dentistry and a literature review. The result showed that of the 5447 teeth treated over a six-year period, 710 were mandibular premolar teeth. The six reported cases of paresthesia in that group reflected an incidence of 0.84%. The intrabony course of the IAN contributes to this occurrence. These paresthesias were from various causes, all related to the confinement of the IAN within the limits of the mandibular cortical plates and the proximity of the nerve to the apices of the teeth, which produces a unique vulnerability, particularly in the premolar and first molar area.

JEVOOR, Praful S., Butchi R. POTTURI\*, and Sharad M. ANTIN\*, Department of Anatomy & Orthopedics, J.N .Medical College, Belgaum, INDIA. Congenital short femur - a case study.

A plain radiograph of 8 month old female child demonstrated marked hypoplasia of right femur, with absence of proximal part of the shaft, as well as head of the femur. There was associated acetabular aplasia. Magnetic resonance imaging showed, no associated soft tissue abnormalities such as hyperplasia, fibrosis or fusion of skeletal muscles. But muscles were seen to be shorter than their counter parts. During the limb bud formation and mesenchymal cell differentiation, influence of adverse factors like bacterial toxins, viral infections, toxic chemicals and hormones are known to cause the said malformations (Tachidizen, 1990), resulting in simple or complete hypoplasia of limbs. Though, clinically such uncommon congenital defects are classified as proximal femoral focal deficiency (Aitken, 1969), this study was carried out, as little documentation is available in such cases, relating to associated soft tissue anatomy. Besides, the etiological factors responsible for the defects, relevant points of clinical significance would be discussed.

## Abstracts

JEVOOR, Praful S., Butchi R. POTTURI\*, and Sharad M. ANTIN\*. Department of Anatomy & Orthopedics, J.N. Medical College, Belgaum, INDIA. Bilateral and congenital absence of radius - a case study.

A female child aged 4 months was observed to have congenital absence of radius in both the upper limbs. On examination both fore arms were short and bowed and hands were deviated towards radial side, probably due to lack of skeletal support. Unlike the ulnar styloid process, the radial styloid process was not palpable. A plain radiograph demonstrated complete absence of radius in both the forearms and also showed associated aplasia of trapezium, first metacarpal, and phalanges of the thumb of right limb and first metacarpal as well as phalanges of thumb in left limb. These congenital defects are attributed to damage of AER or mesenchymal tissues of upper limb bud, in the embryological stage(Heikal, 1959). These defects are also known as radial club, which occurs in 1 in 1,000,00 live births. They are often associated with other malformations like syndactyle, congenital scoliosis, and club foot. Functional loss could not be assessed as the child was in its infancy, yet the absence of both the radii would have influence on functional ability, as muscles arising from common extensor origin and radius, are either absent or hypoplastic. This can only be confirmed by MRI imaging. Besides the anatomical defects, clinical relevance would be discussed.

JONES, Kenneth H., and Robert M. DEPHILIP. Department of Anatomy & Medical Education, The Ohio State University, Columbus, OH. Expanding anatomy in the medical curriculum: clinical anatomy for the third year surgery clerkship.

The trend to reduce time for anatomy in the first year curriculum challenges anatomists to provide students with sufficient knowledge of anatomy to practice medicine, both as primary care physicians and as specialists. Here we report our effort to provide “need to know” clinical anatomy for 200 Med 3 students. Working with the Chair of Surgery, we tested a course that presented specific objectives in anatomy, which our surgeons considered essential for the Med 3 Surgical Rotation. We created “stations” at which dissections had been prepared to present specific anatomical structures and clinically important relationships for: 1) anterior neck - emphasis on tracheotomy, 2) root of the neck - subclavian vessels and central venous lines, 3) anterior abdominal wall – inguinal and femoral hernias, 4) extrahepatic biliary system, 5) GI arteries and portal system. A faculty member or Med 4 Surgery Honors student



## Abstracts

served as demonstrator at each station. The mandatory class was held for 4 hours during the second week of each 6-week rotation. 20-25 students per rotation were divided into smaller groups; each group rotated through all stations, spending about 30 minutes/station. Students' preferences for method of instruction and satisfaction with the pilot class were assessed by 2 surveys, using both Lickert scale and open-ended questions. Overall, students preferred a combination of demonstration by the instructor and "hands-on" work with the cadaver. Students were "very satisfied" with their learning experience (means of 1.4 - 1.6 on a scale of 1 – 5; 1 is the highest).

KUNICKI\*, Jacek, Bogdan CISZEK\* , and Paweł KRAJEWSKI\*. Department of Anatomy, Subdivision of Neurotraumatology, Department of Forensic Medicine, Medical University of Warsaw, Warsaw, POLAND. (Sponsored by K. Pietrasik). Microsurgical relationships between the veins of the posterior cranial fossa and the trigeminal nerve.

Vascular compression of the trigeminal nerve root has been considered as a main factor responsible for trigeminal neuralgia. The arterial compression of the trigeminal nerve is reported as the main cause of trigeminal neuralgia but there is a number of studies that confirm the possibility of trigeminal neuralgia caused by veins . Moreover venous compression of trigeminal nerve is a significant factor for recurrence after initial microvascular decompression. The purpose of this study is to establish the relationships of the venous vessels with the trigeminal nerve root in facial pain free population. A hundred trigeminal nerves of 50 fresh cadavers were examined. The veins of the posterior cranial fossa were perfused with colored latex in a retrograde direction to facilitate the dissection . The superior petrosal vein( SPV) complex was the main cause of a nerve-venous contact. In 69% of examined specimens the trigeminal nerve was in contact with a vein, the typical compression with deformity of the trigeminal nerve root was observed in 9 % of cases. The most often offending veins were the transverse pontine vein and the lateral mesencephalic vein. In four cases the trigeminal nerve was traversed by the tributary of the superior petrosal vein. Our findings show that contact between the cisternal segment of the trigeminal nerve and the SPV tributaries is common finding in pain free population.

## Abstracts

KUNICKI\*, Jacek, Bogdan CISZEK\* , Malgorzata BRZOZOWSKA\*, Paweł KRAJEWSKI \* and Kamil PIETRASIK. Departments of Anatomy, Subdivision of Neurotraumatology, Chair of Surgery, and Department of Forensic Medicine, Medical University of Warsaw, Warsaw, POLAND. The jugular tubercle: microsurgical topographic anatomy.

In the recent years extended (far) lateral approaches has become popular skull base approaches for accessing the lower clivus and craniocervical junction. The jugular tubercle (JT) resection is commonly found to be the basic part of different types of lateral approaches. However, the surgical anatomy of the fundamental steps of these approaches have been previously described, the anatomical description of jugular tubercle is still insufficient. The purpose of this study is to describe morphology and topographical anatomy of the jugular tubercle in relation to other surgically important anatomic structures in the region (foramen magnum, occipital condyle, jugular bulb, hypoglossal canal, vertebral artery and lower cranial nerves). Thirty cadaveric heads and 20 dried skulls were examined. The specimens were injected with colored latex for vascular system enhancement. Standard microsurgical techniques were used for dissections. Detailed measurements of osseous relationships of the jugular tubercle were performed. The results of our study determine usefulness of JT removal during extended lateral approaches Drilling the JT results in the significant increase of the surgical exposure and is closely related to the height of the Jugular tubercle which was 2.8 mm (1.0- 9.0 mm). Special attention was paid to evaluate the extent of JT removal during so called supracondylar trans jugular tubercle approaches.

LACHMAN\*, N<sup>1</sup>, K.S. SATYAPAL<sup>2</sup>, and E.A. VANKER\*<sup>3</sup>. <sup>1</sup>Department of Human Biology, Faculty of Health, Technikon Natal; <sup>2</sup>Discipline of Anatomy, School of Basic and Applied Medical Science, Faculty of Health Sciences, University of Durban-Westville, Durban, SOUTH AFRICA. Angiographic manifestation and anatomical presence of the intra-mural LAD: surgical significance.

The left anterior descending coronary artery (LAD) remains one of the coronary branches most frequently subjected to surgical manipulation. Frequently, the LAD deviates from its usual sub-epicardial position to follow an intra-myocardial course, either by traveling a significant length within the myocardium or beneath an arrangement of muscular slips. Although recognized as a distinct anatomical entity, the surgical significance of the intramural coronary artery and its branches has evoked much interest. With the trend

## Abstracts

towards minimal access surgery, the pre-operative identification of such anatomical variants of coronary artery disposition becomes increasingly relevant, if technical challenges that may be associated with its surgical presentation are to be abated. Whilst studies have been attempted, little has been achieved in terms of the precise identification of the course of these arteries angiographically. This study presents the findings of a correlative cadaveric and clinical investigation of the intra-mural LAD. Twenty un-embalmed hearts, free from surgical exploration were selected. The coronary system was injected with a barium solution and images of the heart were taken. A detailed micro-dissection followed. One hundred angiograms of patients presenting for cardiac surgery were compared with reports of surgical presentation of LAD. Results showed that in an intra-myocardial position, the LAD depicted a straight appearance on angiograms as opposed to a tortuous pattern typically observed in the sub-epicardial position. Whilst systolic narrowing of a coronary segment is considered to be an indicative sign of myocardial bridging, there is uncertainty in it being confirmatory. The findings of this investigation may contribute to a list of possible diagnostic indicators of myocardial bridging and provide valuable information for the surgeon, in the pre-operative work-up of the patient

LEE, Hyeyeon, Heejoon YANG\*, Youngchun GIL\*, Hyungsun WON\*, and Dongsu JANG\*. Department of Anatomy and Brain Korea 21 Project for Medical Science, Yonsei University College of Medicine, Seoul, Korea. Transverse facial artery and its relationship to the parotid duct and facial nerve.

To clarifying the origin and course of the transverse facial artery (TFA), ten sides of fresh cadaveric heads were dissected under the operating microscope. Transverse facial artery arose from the superficial temporal artery within the parotid gland. In 60% of the cases, a single TFA arose near the temporofacial division of the facial nerve and divided into the superior and inferior branches. In 30%, double arteries were observed and the inferior one arose at the level between two divisions of the facial nerve. In one case, four TFAs were found. There was a dense fibrous septum between facial nerve and transverse facial vessels. Large superior branch of the TFA ran between the zygomatic branch of the facial nerve and the parotid duct to supply this area. In 60% of the cases, a small inferior branch (or artery) crossed deep to the parotid duct within 15 mm from the gland margin. In 30%, a small branch of inferior TFA ran inferior to the parotid duct. In 90%, the interconnecting fiber of the

## Abstracts

buccal branch from the superior division crossed the duct and ran around it. In 60%, a small branch of TFA accompanied by the interconnecting fiber.

LONGATO\*, Stefano, Karl-Heinz KUENZEL\*, Felix AIGNER\*, Hubert MESSNER\*, Othmar GABER, Helga FRITSCH\*, Reto J. BALE\*, Thomas LANG\*, Thomas TRIEB\*, Michael RIEGER\*, Peter KOVACS\*, Werner JASCHKE\* and Sepp POISEL. University of Innsbruck, Institute of Anatomy and Histology, Department of Anatomy I, Innsbruck, AUSTRIA. Accurate adaptation of anatomical slices of the foot to correlated CT and MRI images by means of a stereotactic navigation system.

The issue of our investigations is the workout of accurate adaptation of anatomical 5 mm sections correlated to preceding coronal, sagittal and transversal CT and MRI slices by means of a stereotactic navigation system. For this purpose CT and MRI scans have been done on three formalin fixed feet of human cadavers. Eight external multimodal (CT/MRI) markers were attached to the cadavers. The datasets were transferred to the Stealth Station Navigation System (Medtronic Sofamor Danek, Boulder, USA). The CT and MRI datasets were superimposed to each other by means of paired-point matching based on the external markers. A dynamic reference frame was attached to the cadavers. After registration using the multimodal markers 5 mm slices of the cadavers were obtained and the actual sections were correlated to the preceding CT/MRI slices by using the probe of the navigation system. The results showed that anatomical sections can be identically compared with correlated CT/MRI slices by using stereotactic navigation. The morphologic knowledge of the anatomical structures is of great importance while using modern imaging systems within the framework of preoperative management of minimal invasive operations.

LONGATO\*, Stefano, Michael PIMPL\*, Werner NINDL\*, Sepp POISEL, Felix AIGNER\* and Lars KLIMASCHEWSKI\*. Institute of Anatomy and Histology, University of Innsbruck, Innsbruck, AUSTRIA. Biolistic transfection and morphological analysis of cultured sympathetic neurons.

The identification of genes involved in neuronal differentiation and neurite outgrowth has become a major field of interest for developmental neurobiologists. In our laboratory the functional significance of candidate genes is investigated in a primary neuronal cell culture system. To this end, the candidate gene is cloned and

## Abstracts

expression plasmids are constructed that are used for over-expression of the wild-type protein or inhibition of the endogenous protein by application of dominant-negative techniques. The plasmids are then introduced into cultured neurons followed by analysis of survival and neurite outgrowth. Because neuronal transfection and morphological analysis of a sufficient number of neurons is a time consuming task, we developed a protocol that allows rapid transfection and morphometry of sympathetic neurons using commercially available equipment and software. Applying the biolistic approach and computer-assisted morphometry about 10% of dissociated sympathetic neurons are consistently transfected and analyzed within 2 days. Enhanced green fluorescent protein (EGFP) or red fluorescent protein (DsRed) serve as markers for the cell body, axonal processes and growth cones including lamellipodia and filopodia. A detailed routine for quantitative morphometric image analysis using Metamorph<sup>®</sup> software is suggested and exemplified by comparing the effects of nerve growth factor (NGF) and dibutyryl cyclic adenosine monophosphate (dbcAMP) on neurite outgrowth of sympathetic neurons plated on collagen coated glass floor dishes.

LOUKAS Marios<sup>1</sup>, Artur Bartczak<sup>1,3\*</sup>, Michal Kamionek<sup>1\*</sup>, Mirek Kiedrowski<sup>1\*</sup>, Michal Stachura<sup>1\*</sup>, Martin FUDALEJ<sup>2\*</sup>, and Teresa WAGNER<sup>1\*</sup>.<sup>†</sup> Department of Pathology, Institute of Rheumatology,<sup>2</sup> Department of Forensic service, Warsaw Medical University,<sup>3</sup> Department of Pathology, Warsaw Medical University, Warsaw, POLAND. Infundibulosinus partition, a new structure of the right ventricle.

Apical ventricular septal defects (AVSD) are difficult to visualize and even more difficult to treat. We present a new understanding of the anatomic morphology and location of the infundibular apical recess or infundibular apex with the purpose of better understanding the position of apical septal defects and furthermore the option for new surgical treatment. 160 fresh human hearts were collected and dissected in such a way that we were able to visualize the right ventricular outflow and inflow sinus as well as the moderator band and the papillary muscles. We are able to show that in all hearts the apex of the right ventricular inflow is proximal to the outflow tract (infundibulum). There was a muscular partition (infundibolosinus partition), including the moderator band, between the inflow and the outflow apices. The outflow or inflow apex typically was further to the left and closer to the left ventricular apex and inferior and to the right of the infundibular apex. The apex of the infundibular recess was anterior and to the left of the moderator band. The two apices are

## Abstracts

separated by the infundibulosinus partition, which in some cases 80 (50%) exhibit some intertrabecular spaces. This new understanding of the existence of two apices in the right ventricle could be applied as basis for the closure of AVSD with a limited right ventricular apical infundibulotomy.

LOUKAS, Marios<sup>1</sup>, Mirek KIEDROWSKI<sup>1\*</sup>, Artur BARTCZAK<sup>1,3\*</sup>, Michal KAMIONEK<sup>1\*</sup>, Michal STACHURA<sup>1\*</sup>, Martin FUDALEJ<sup>2\*</sup>, Teresa WAGNER<sup>1\*</sup> <sup>1</sup> Department of Pathology, Institute of Rheumatology, <sup>2</sup> Department of Forensic service, Warsaw Medical University, <sup>3</sup> Department of Pathology, Warsaw Medical University, Warsaw, POLAND. The location and the morphology of the artery of Kugel in adult human heart.

The aim of this study was to describe, the morphology and the topography of the artery of Kugel (AK). The study was carried on 60 hearts, obtained from the routine autopsies performed in the departments of Rheumatology and Forensic Medical Service and Warsaw Medical University. Digital image analysis software program Lucia applied for the measurement of structures related with AK. AK has been identified in all hearts examined and three main patterns were recognized: A, in which the AK arose independently from the right coronary artery and moved upward to become an interatrial artery 36 (60%); B, in which the AK artery arose from left anterior descending and also moved upward to become an interatrial artery 21 (35%); C, in which AK arose from the circumflex and connected to whatever artery supplies the crux of the heart 3 (5%). The relative incidence of the three patterns together with the morphology and topography of the AK varied significantly with presence of an occlusion of the one of the major epicardial arteries. Interestingly in hearts with occlusion of proximal part of right coronary artery the arterial supply to AV node was mainly by the AK. This may suggest that AK may be one important collateral vessels restoring supply to the AV in compensation for the relatively reduced blood flow due to occlusion of one or epicardial arteries.

LOZANOFF, Scott, and Brandeis M. McBRATNEY\*. Department of Anatomy and Reproductive Biology, University of Hawai'i School of Medicine, Honolulu, HI., and Department of Anthropology, Harvard University, Cambridge, MA. The genetic basis of frontonasal dysplasia.

Frontonasal dysplasia results from a deficiency in medial nasal prominence merger. However, the genetic aberration leading to this malformation is unknown. The purpose of this study was to

## Abstracts

characterize the phenotype and genotype of the *Br/Br* mouse that displays frontonasal dysplasia. Analyses were performed by reciprocal matings of 3H1 *Br/+* adults and using 116 offspring from 31 litters delivered through Caesarian sections at gestational day 18. Results showed that offspring demonstrated three craniofacial morphologies including normal, midfacially retrognathic and median facial clefting in a 1:2:1 (+/+:*Br/+*:*Br/Br*) pattern consistent with an autosomal semidominant mode of inheritance. Whole mount staining and immunolocalization of type II collagen indicated that *Br/Br* mice consistently lacked a presphenoid. Karyotyping did not reveal major gross chromosomal aberrations, however, microsatellite analysis showed that *Br* localized to distal mouse chromosome 17 between D17Mit190 and D17Mit155. Results indicated that *Br* occurs in the same region as genes associated with holoprosencephaly suggesting that these two diseases may exist on opposite ends of a developmental spectrum. Supported by HCF 20012653.

LOZANOFF, Scott, Beth K. LOZANOFF\*, Mircea-Constantin SORA\*, Julie ROSENHEIMER, Marcus KEEP\*, Joshua JACOBS\*, Stanley SAIKI\*, Dale ALVERSON\*. Department of Anatomy and Reproductive Biology, University of Hawai'i School of Medicine, Honolulu, HI; SURFdriver Software, Kailua, HI; Department of Anatomy, Anatomical Institute, Vienna University, Vienna, Austria; Department of Medicine, University of Hawai'i School of Medicine, Honolulu, HI; Tripler Army Medical Hospital, Honolulu, HI, Department of Pediatrics and Obstetrics and Gynecology, University of New Mexico School of Medicine, Albuquerque, NM. Two-dimensional computerized modeling using plastinated human brain sections for Access Grid instructional delivery.

The TOUCH (Telemedicine Outreach for Unified Community Health) project was established as a collaborative virtual reality (VR) instructional project between the University of Hawai'i and University of New Mexico medical schools to provide Problem Based Learning (PBL) modules via the Access Grid (AG). Two- and three-dimensional anatomical models were developed to augment a VR presentation of a patient with an epidural hematoma. Animating anatomical relationships typically relies on artistic renderings for keyframing and these can be very time consuming to develop. Plastinated sections may provide a useful alternative to artistic renderings for providing key frames. The purpose of this paper is to describe a method for developing animations using plastinated sections. Coronal brain sections were obtained and processed with the P40 embedding system. The relevant plastinated coronal brain

## Abstracts

section was selected, digitized, rendered in Adobe Photoshop, loaded into Kai's SuperGoo and morphed. Resulting animations were viewed with QuickTime to which audio narration was added and uploaded for viewing on the AG. Animations were presented to students subsequent to the VR session and their usefulness was assessed using a standard PBL evaluation process. Results showed that animations improved students' comprehension of CNS changes that occur following uncal herniation. This method demonstrates how realistic anatomical animations can be generated quickly and inexpensively using plastinated brain sections. Supported by OAT HHS 2 D1B TM 00003-02.

MACIEJEWSKA<sup>\*</sup>, Izabela, Jacek KACZMAREK<sup>\*</sup>, and Wojciech PAWLINA. Medical University of Gdańsk, Poland and Department of Anatomy, Mayo Clinic and Mayo Medical School, Rochester, MN. Comparison of anonymous and non-anonymous responses in peer- and self-evaluations of dental students.

Peer and self-evaluations are crucial in the professional development of medical and dental students. These evaluations help students constructively evaluate their learning process and develop better approaches to self-directed study. They also evaluate skills and competencies (e.g., professionalism, communication skills) not readily assessed by traditional examinations. At the Medical University of Gdańsk Faculty of Medicine, Division of Dentistry peer- and self-evaluation was implemented in groups of four fifth-year dental students in clinical anatomy sessions. The evaluation consisted of questions that assessed the individual's own and their classmates' contribution to small-group discussions. In addition, students were asked to provide positive or negative feedback on their own and peer contributions to small-group dynamics. Approximately 50% of the students submitted their evaluations non-anonymously (NA) and 50% did not reveal their identity (anonymous group A). The self-evaluation ratings (on a scale of 1 to 5, with 1 being the lowest) of the group A (2.73) were significantly higher ( $p < 0.05$ ) than those of the NA group (1.93). The peer-evaluation ratings in the NA group (2.79) were also significantly higher ( $p < 0.01$ ) than the self-evaluation ratings (1.93). The difference between peer- and self-evaluation ratings in group A were not statistically significant.



## Abstracts

MacPHERSON, Brian R. Instructional Technology Development Group, Department of Anatomy and Neurobiology, University of Kentucky, Lexington, KY. Working effectively with a one-man Body Bequeathal Program.

The Body Bequeathal Program at the two institutions where the author has been employed have essentially been one-man operations - a "coordinator". A single individual, responsible to a designated faculty member, dealt with the public, did the paper work, embalmed the cadavers and ensured that the gross labs ran effectively. In that person's absence, the faculty oversight was the "go to" person should questions arise concerning donors. When the faculty oversight was also away, this responsibility trickled down through gross anatomy course directors. In an effort to at least be able to answer questions on a donor's status, a web-based database was constructed. The database contained all the information collected by the coordinator as required by law, in addition to many others - a total of 76 fields. Using the Web Companion feature of *Filemaker Pro*<sup>TM</sup> a password protected intranet-only accessibility program, hosted on a secure server, was used with a *Filemaker HomePage*<sup>TM</sup> interface that displayed only selected fields that were searchable through a number of general facts (*ie.* name, social security number, etc.). In addition to providing a quickly accessible source of information on all donors; past, present and future, it also allows us to collect data on various aspects of the Program, both donor as well as monetary-based.

MALAKHOVA, Olga, Kyle E. RAREY, Robert VANDER GRIEND, and Lynn J. ROMRELL. Department of Anatomy and Cell Biology and Department of Orthopaedics. University of Florida, Gainesville, FL. The impact of formative feedback during the first-year clinical anatomy course.

Based upon the small group learning activities in the laboratory, the first-year clinical anatomy course provides an optimal course to determine whether formative feedback enhances student learning early in the medical curriculum at the University of Florida College of Medicine. Midway through a sixteen-week course, students (n=108) were asked first to assess their level of performance in the following five competency categories: Core Discipline, Problem Solving, Health Care Team, Human Relationships and Communications, and Professional Behavior. For each competency, four descriptors were utilized to determine approximate level of achievement. Each student was asked to sit with a member of the course teaching faculty, who also independently assessed the student level of

## Abstracts

proficiency in each of the five competency categories. At the time of the meeting, the faculty member marked on the student formative feedback form, thereby providing evidence of agreement or disagreement of the stage of student's learning. Initial inspection of the formative-feedback forms indicate that the learner and teacher were congruent in their assessments. This implemented feedback method provides a greater interaction between the teacher-learner in identifying specific plans of remediation, particularly for those students at risk academically. Initial data also suggest that students performed at higher levels of proficiencies after formative feedback was given.

McWHORTER, David L. and Pamela P. THOMAS. Department of Anatomy, The University of Health Sciences College of Osteopathic Medicine, Kansas City, MO. The effects of an alternate dissection schedule on anatomy lab practical performance.

Many anatomy departments in medical schools throughout the world are using a variety of approaches (e.g., peer teaching, prosections) to improve the efficiency of laboratory time. The purpose of this study was to examine the effects of using an alternating dissection schedule on anatomy lab practical performance. Upper and lower extremity lab practical performance for students that dissected in every laboratory (EL group; N = 227) was compared to students that dissected every other lab (EOL group; N = 254) using a Student's t-test. For the upper limb part of the anatomy lab practical, the mean scores for the EL and EOL groups were 74.5% and 68.1%, respectively (P < 0.001). However, the mean scores for the EL and EOL groups on the lower limb portion of the anatomy lab practical were 75.9% and 75.6%, respectively. These preliminary data suggest that the use of an alternating dissection schedule had an equivocal effect on students, gross anatomy lab practical performance.

OCEL\*, Joseph J., Christopher M. WITTICH\*, Brian A. PALMER\*, Stephen W. CARMICHAEL, and Wojciech PAWLINA. Department of Anatomy, Mayo Clinic and Mayo Medical School, Rochester, MN. Benefits of the Gross Anatomy Teaching Assistant Experience.

During the first-year Gross Anatomy course, Mayo Medical School provides third-year students the opportunity to participate as teaching assistants (TAs). Their responsibilities include performing each dissection prior to lecture, instructing students during dissection, writing exam questions, and giving a lecture. To evaluate the effects of peer tutoring with regards to the teaching assistants, a

## Abstracts

survey instrument was developed. This instrument was sent to former TAs from the past 15 years to evaluate 3 major areas of possible influence: skill/knowledge development, academic development, and professional impact. Eighty-five percent of respondents indicated the experience helped during their third-year surgical rotation, while over 60% identified benefits during neurology, OB/GYN, and internal medicine rotations. The majority (64%) indicated they use knowledge gained from the experience regularly. In regards to skill development, communication skills were the most highly ranked area, with 86% of respondents indicating gains in lecture effectiveness and 97% in one-on-one teaching. Fifteen percent of respondents entered a surgical career field, roughly paralleling the non-TA medical student population (18%). The results concerning the influence of the experience on career development direct are less well established. However, the Gross Anatomy TA experience has perceived benefits with respect to clinical rotations, communication, and teaching skill development.

PATTERSON, Hugh A. and Jeffery A. TABAS\*. School of Medicine, Pathology, and Department of Anatomy, Emergency Department, San Francisco General Hospital, University of California, San Francisco, CA. Cadaver-based invasive procedures training for medical students.

Training medical students and residents to do invasive clinical procedure poses a number of difficult issues. Patients want to have the most experienced clinician doing the procedure not someone who is doing it for the first time. Medical students want to learn the procedures necessary to master their profession and yet know their own lack of expertise and fear the harm that might befall the patient. It is ironic that while these procedures have the greatest impact on patient outcome, and the highest risk of complications, they are performed most infrequently and without any formal training. For the past two years at UCSF we have piloted a cadaveric invasive procedures training lab for 3rd and 4th year medical students. The course has paired students with an attending physician to learn 5 emergent procedures. Unembalmed cadavers are used because tissue texture is closer to living tissue. The procedures are central venous access via the internal jugular and subclavian veins, femoral artery and vein access, tube thoracostomy, saphenous vein cutdown, intraosseous access, and emergency cricothyrotomy. For each procedure the students prepare a talk with a handout explaining the anatomical basis for the procedure to their classmates. Prosections are used to insure that important

## Abstracts

relationships are understood. After this introduction the attending physicians supervise students as they rotate through different locations to practice each procedure. The course is now become a scheduled selective in the curriculum.

PERSAUD, Vid. Department of Human Anatomy and Cell Science, University of Manitoba, Winnipeg, MB, CANADA. Ancient anatomy - Galen and earlier.

Prehistoric cave art and sculptors depict hunting scenes, animals, and human figures. Their significance remains a matter of speculation. Many surviving artifacts from this era reveal some anatomical knowledge and these have paralleled the cultural evolution of man. Diseases, "monstrous births", and descriptions of internal organs were recorded on clay tablets by Mesopotamian diviners, who also made models of organs for instructing their pupils. In ancient Egypt, medicine was relatively advanced. There are numerous anatomical terms and references to various parts of the human body, as well as descriptions of surgical procedures, in both the Ebers and Edwin Smith papyruses. Surgical procedures, based on anatomical principles, were carried out in ancient India and China. About 500 B.C., Alcmaeon of Croton discovered the optic nerves and pharyngotympanic tubes, and later Empedocles speculated on the functions of organs, ideas which led him to formulate a theory of humoral pathology. Hippocrates (460-377 B.C.) postulated that "anatomy is the foundation of medicine." He was familiar with human bones but not the internal organs. Hippocrates philosophical concept of the structure of the human body and causes of diseases has shaped the practice of medicine up to the modern era. Aristotle (384-322 B.C.), who laid the foundation of comparative anatomy, speculated about the structures of the human body from his observations of dissected animals. In Alexandria, Herophilus (300- ? B.C.) and Erasistratus (310 - ? B.C.) dissected more than 600 human bodies and recognized many parts of the body. Undoubtedly, the most celebrated anatomist of antiquity was the Graeco-Roman physician Galen (131- 201 A.D.) who dissected many species of animals. His voluminous writings had a profound influence on the evolution of anatomical knowledge until the early middle ages.

PETTERBORG, Larry J. School of Physical Therapy, Presbyterian Campus, Texas Woman's University, Dallas, TX. Team building and peer teaching in a gross anatomy course for physical therapy students.

## Abstracts

Contemporary health care is delivered by teams of individuals trained in a variety of specialties working together for the benefit of their patients. Every student training in a health care discipline must learn to function as a member of a team. In addition, health care providers need practice as educators and teachers. At our institution, new students begin their professional education with team building exercises that are then reinforced through peer teaching in the dissection laboratory. Students are randomly assigned to groups of 6-8 at orientation where they participate in team building exercises together. They then stay together as a team for the gross anatomy dissection course. Each team is divided into 2 groups; each group is then responsible for preparing and demonstrating half of the 28 class dissections. Dissection preparation periods are normally 3 hours long followed by another hour devoted to peer teaching. Since only half of the students are actively dissecting in any given lab period, there is more efficient use of time and resources. End of course evaluations and surveys provide strong evidence of student satisfaction with our team building and peer teaching approach to gross anatomy instruction. Our students work well together and learn better because they are partially responsible for the education of their classmates.

PHILO\*, Ron and Charleen M. MOORE. Department of Cellular and Structural Biology, The University of Texas Health Science Center at San Antonio, San Antonio, TX. Sources of anatomical knowledge in the works of Frida Kahlo.

The preeminent female Mexican artist Frida Kahlo rendered surprisingly accurate representations of human anatomy in her works. Frida was capable of near photographic depiction of her subjects but developed her unique style, sometimes categorized in the genre of Surrealism, to speak to the people of Mexico. As a child Frida contracted polio, and, as a result, her right leg was permanently atrophied. In 1925, at age 18, Frida suffered a near fatal injury in a bus-streetcar crash. Poor health consequent to her polio and accident affected Frida the rest of her life. During her convalescence Frida contemplated a career as a medical illustrator. It was at this time Frida began to paint. In 1928, Frida showed her work to Diego Rivera, who encouraged her to pursue an art career. The following year Frida and Diego married and became one of the most famous couples in Art History. In 1932, while in Detroit with Diego, Frida had a miscarriage at the Henry Ford Hospital. This was the seminal event for the incorporation of anatomy into her works. During her recovery Frida requested medical texts to study. Some of these texts remain in the Museo Frida Kahlo in Mexico City. Their

## Abstracts

influence, particularly that of *The Principles and Practice of Obstetrics*, Joseph B. DeLee, W. B. Saunders Company, is evident in subsequent works. As will be shown, her anatomical knowledge was incorporated in *The Miscarriage* 1932, *My Nurse and I* 1937, *The Two Fridas* 1939, *Flower of Life* 1943, *Moses* 1945, *Sun and Life* 1947. Anatomical allusions are present in other works, but those in *The Broken Column* 1944 are most striking. In that year a protracted decline in her health began. Frida's medical problems, including gangrene and amputation of her right leg, culminated in her death on July 13, 1954 at the age of 47.

PORTA, David J.<sup>1-2</sup>, Jeryl C. JONES<sup>\*3</sup>, Joel D. STITZEL Jr.<sup>\*4</sup>, Joseph M. CORMIER<sup>\*4</sup>, William J. HURST<sup>\*4</sup>, and Stefan M. DUMA<sup>\*4</sup>. <sup>1</sup>Department of Biology, Bellarmine University, Louisville, KY. <sup>2</sup>Department of Anatomical Sciences and Neurobiology, University of Louisville School of Medicine, Louisville, KY. <sup>3</sup>Virginia-Maryland Regional College of Veterinary Medicine, Blacksburg, VA, <sup>4</sup>Virginia Tech Impact Biomechanics Laboratory, Blacksburg, VA.

### A comparison of dissections with 3-D CT images of cadaver faces subjected to impact by baseballs.

Two fresh caucasian cadavers (male age 44 and female age 59- both of whom died of lung disease) were tested as part of a study to determine the validity of a computer model. A pneumatic-based canon propelled a baseball at a velocity of 60-70 mph targeted at the zygomatic arch. The impacts were recorded on high-speed video. After impact, the specimens were imaged via plain film radiographs and computed tomography recorded at 2 mm sections. The 2-D axial images were then fed to a computer system and reconstructed in three dimensions. 3-D CT has been promoted as a complementary manipulation of images that can aid in diagnosing facial trauma and planning subsequent surgery in the living. It has also been suggested as an aid to forensic post-mortem examination of homicide victims with facial fractures. While the 3-D CT reconstructions in a traumatized face provide a sometimes-stunning display of the skeleton, there are still many fragments and fracture lines that go undiagnosed when compared to a thorough dissection. The 3-D reconstructions are an excellent tool that will surely improve as technology advances (spiral CT, MRI, etc.). However, caution should be exercised as current reconstructions may underestimate fragmentation in blunt facial trauma.

## Abstracts

PRICE\*, Matthew R., Edward TILLET\*, Stephen G. NETTLETON, Robert D. ACLAND. Department of Anatomical Sciences and Neurobiology, and Department of Orthopaedics, University of Louisville School of Medicine, KY. Determining the relation of the axillary nerve to the shoulder joint capsule from an arthroscopic perspective.

The axillary nerve travels in close approximation to the shoulder joint capsule. Damage to the axillary nerve is a known complication of arthroscopic procedures involving the inferior glenohumeral ligament. To avoid damaging the axillary nerve, the surgeon needs an accurate understanding of its location as visualized from within the joint. Standard descriptions of the axillary nerve are unsatisfactory because they are based on open dissection which displaces the nerve; and because they describe the location of the nerve in relation to landmarks not visible from within the joint. We present a study on fresh cadavers that addresses the following questions: 1) where does the axillary nerve cross the inferior aspect of the shoulder joint capsule in relation to landmarks visible from within the joint; and 2) how close is the axillary nerve to the joint capsule as it passes inferior to it? The study is based on: 1) 10 dissections made from within the joint, exposing the axillary nerve through a window in the inferior capsule; and 2) 10 frozen specimens transected with a bandsaw in the coronal plane through the glenoid fossa. The study is currently in progress, and full data will be included in the presentation.

RAMSAROOP\*, Lelika, Bhugwan SINGH\*, Jaynathan MOODLEY\*, Prawesh PARTAB\*, and Kapil S SATYAPAL. Department of Anatomy, School of Basic and Applied Medical Sciences, University of Durban-Westville; Department of Surgery, Nelson R Mandela School of Medicine, Durban, SOUTH AFRICA . Anatomical basis for a successful upper limb sympathectomy.

In this clinico-anatomical study factors potentially responsible for unsuccessful ULS by the thorascopic route were evaluated. This study comprised two subsets: *i. Clinical:* 25 patients (n=50) underwent 2<sup>nd</sup> thoracic ganglionectomy for palmar hyperhidrosis. Factors predisposing to unsuccessful ULS were identified. *ii. Anatomical:* Neural connections of the 1<sup>st</sup> and 2<sup>nd</sup> intercostal spaces were bilaterally dissected in 22 adults (22 right; 21 left) [n=43 sides]. *Results :* *i. Clinical:* Alternate neural pathways (ANP) were noted in 9 cases (18%). In 3 asthenic patients (5 sides), fascia overlying longus colli muscle mimicked the sympathetic chain. The 2<sup>nd</sup> superior intercostal vein (SIV) on the right was located anterior to the 2<sup>nd</sup>

## Abstracts

thoracic ganglion on 6 (12%) sides and predisposed to troublesome bleeding in 2 cases; SIV was posterior in 19 sides (38%), posing no technical problem. On the left, the 2<sup>nd</sup> SIV was noted outside the field of dissection in all but 1 case. A successful outcome to sympathectomy was noted in all patients. *ii. Anatomical:* A spectrum of sympathetic contributions to the 1<sup>st</sup> thoracic nerve of the 1<sup>st</sup> intercostal space were noted in 79.1% [<sup>34</sup>/<sub>43</sub>] cases. These were categorized as Type A – 41.9% [<sup>18</sup>/<sub>43</sub>]; Type B (the classic nerve of Kuntz) – 18.6% [<sup>8</sup>/<sub>43</sub>] and Type C – 18.6% [<sup>8</sup>/<sub>43</sub>]. When present, the nerve of Kuntz was located between 2.3 – 15.7mm lateral to the 2<sup>nd</sup> thoracic ganglion. Fused stellate ganglion (86%) and an independent inferior cervical ganglion (16.3%) was always located above the 2<sup>nd</sup> rib. The 2<sup>nd</sup> thoracic ganglion was consistently located in the 2<sup>nd</sup> intercostal space. ANPs, though anatomically significant, have little clinical significance when a 2<sup>nd</sup> thoracic ganglionectomy is undertaken. Technical failures may be avoided if the surgeon is mindful of anatomical variations at surgery.

RAREY, Kyle E., Olga MALAKHOVA, Robert VANDER GRIEND\*, and Lynn J. ROMRELL. Department of Anatomy and Cell Biology and Department of Orthopaedics, University of Florida, Gainesville, FL. Five-card anatomy draw: a cumulative oral examination in the gross anatomy Laboratory.

The clinical anatomy faculty at University of Florida College of medicine used a year-end cumulative oral examination to determine student's level of anatomical knowledge and ability to apply such knowledge to clinical cases. The objective of this presentation is to describe the design and implementation of it. Since the clinical human anatomy course is taught regionally, five questions per region (n=5) were prepared. Each question was based upon a patient presenting with a given set of signs/symptoms. The student had to identify the anatomical structures involved and, secondly, explain the signs/symptoms or describe relevant embryological concepts. Questions were placed on note cards and placed in five stacks (regions). Thirty minutes were allocated for each student to take the oral examination. During the first five minutes, students had to draw a card (question) from each of the five stacks (regions). At the end of five minutes, a student could place one of the five drawn cards back. Students then had 20 minutes to answer four clinically related anatomy questions. Student feedback was extremely positive; students recommended more oral examinations. Oral examinations provide an alternative to assess students' anatomical knowledge without the use of prompts as in multiple-choice examinations.



## Abstracts

RAREY, Kyle E., Olga MALAKHOVA, Lynn J. ROMRELL, and Robert VANDER GRIEND\*. Department of Anatomy and Cell Biology and Department of Orthopaedics. University of Florida, Gainesville, FL. Peer feedback and self-assessment in a first-year anatomy course.

The first-year anatomy course is primarily a laboratory course in which students are assigned into teams of six to study regional human anatomy. For a given dissection, three of the six students dissect while the other three students review relevant prosections, cross-sections and osteology. Near the end of each laboratory period, all six students share information learned. The objective of including student self and peer assessments is to promote self-reflection and to provide peer feedback. Three times during the course, an individual student is asked to assess their ability and that of their peers to promote team learning. Students are asked also to identify an incident that demonstrates that they or a peer was effective in interacting with other members of the team and an incident in which they could have interacted more effectively. Results indicate that peer evaluations are higher in value as opposed to self-evaluations (peer evaluation, 4.3; self-evaluation, 3). Students are more critical of their effectiveness in team-directed learning. The majority of students indicated that the self-peer assessments were valued as part of their professional training.

RAREY, Kyle E, Olga MALAKHOVA, Robert VANDER GRIEND\*, and Lynn J. ROMRELL. Department of Anatomy and Cell Biology and Department of Orthopaedics, University of Florida, Gainesville, FL. Enhancing retention and recall of gross anatomy.

At the University of Florida College of Medicine, past students were assigned learning objectives of a given region and then are examined regionally without overlap. Students, in general, stated that after a unit examination, they “purged” such information and prepared to learn new information. In retrospect, it is interesting that we teach and test regionally, but expect our students to be competent about the anatomy of the whole body at the end of the course. Further, a comprehensive NBME subject exam is given which covers the entire human body and embryology, and students are expected to recall the collective anatomy of the human body for USMLE Step 1. The objective of this presentation is to discuss the whether the use of cumulative examinations facilitated students retention and recall. During this past academic year after the first unit examination, the teaching faculty created comprehensive written and laboratory examinations for the remaining two units. A

## Abstracts

comprehensive oral examination also was given. A NBME anatomy subject examination was administered; compared to scores in past years, students' percentile score was twenty-six units higher. The data suggest that cumulative examinations are useful education instruments in assisting students increase their levels of retention and recall of human anatomy.

REEVES, Rustin E., John E. ASCHENBRENNER\*, Rouel S. ROQUE\*, Robert J. WORDINGER\* and Harold J. SHEEDLO\*. Department of Pathology and Anatomy, University of North Texas Health Science Center, Fort Worth, TX. Integrating computers and technology with dissection in the human gross anatomy laboratory: Improving efficiency in the modern laboratory setting.

The need to increase efficiency of dissection in the modern gross anatomy laboratory has been the driving force behind the technological changes we have implemented over the past year. With the recent introduction of an integrated systems-based medical curriculum and a reduction in laboratory teaching hours, the anatomy faculty of the University of North Texas Health Science Center (UNTHSC) developed a browser-based dissection manual to fit these curricular changes and time constraints. At each cadaver workstation, Apple iMac computers were installed and the new dissection manual was loaded for student use. Structures assigned for dissection within the text of the manual were bolded, and then linked to digital images of anatomical structures and Netter human anatomy atlas illustrations. The browser-based dissector allows students to view actual images of structures prior to beginning each dissection. Although we have placed a high priority to computerize the gross anatomy laboratory at UNTHSC, we are still strong advocates of the process and importance of cadaver dissection. It is our belief that the combination of computers and dissection is a natural evolution of technology and creative teaching strategies specifically adapted for human gross anatomy laboratories of the 21<sup>st</sup> century. This strategy can significantly enhance students, dissection proficiency, increase the efficiency of laboratory dissections, and give anatomy faculty more quality laboratory instruction time.

RICHARDS, Alan T., Neil S. NORTON, Steve FENTON, and Thomas H. QUINN. Departments of Surgery, Oral Biology, & Biomedical Sciences, Creighton University, Omaha, NE. Lapsus lingulae: the peculiarities of the lingual artery.

Although the tongue appears to have an excellent collateral blood supply, occasional reports exist indicating that necrosis of the tongue

## Abstracts

may ensue after surgery on the tongue or a radical neck dissection. Few detailed descriptions of lingual arterial morphology exist. We therefore studied cadaver dissection and radiological images of the lingual region. We dissected a total of 38 lingual arteries in 21 specimens. The lingual artery branched directly from the external carotid in 65.8% of the cases and from a common trunk with the facial artery in 34.2% of the cases. When both sides of the head were available for dissection, we found that 17.6% had a direct lingual branch on one side and a common trunk on the other side, 52.9% had a direct lingual branch on both sides, and 29.4% had a common trunk on both sides. All of the arteries, whether lingual or common trunks, would form a loop around the greater cornu of the hyoid bone near their origins. If a common trunk occurred, it divided into the facial and lingual arteries 14.3mm after branching off the external carotid artery. As the lingual artery approached the hyoglossus muscle, a suprahyoid branch was observed. After passing 7.3mm beyond the posterior border of the deep surface of the hyoglossus, dorsal lingual arteries arose. At the anterior border of the hyoglossus, the lingual artery divided into a deep lingual branch and a sublingual branch. In 13.2% of the total arteries studied, the lingual did not divide into these two terminal branches, but continued as a series of smaller branches supplying the anterior tongue and sublingual gland. The presence of these variations as well as variations between the left and right halves of the same head indicate that further study of the surgical anatomy of the lingual artery are warranted.

RODRIGUES, Consuelo J, Jin H. YOO\*, and Aldo J. RODRIGUES Jr. Department of Surgery, Faculty of Medicine, University of Sao Paulo, Sao Paulo-SP, BRAZIL. Elastin point mutations in patients with inguinal hernia.

Although the etiology of the adult inguinal hernias are multifactorial, all groin hernias emerge at myopectineal orifice of Fruchaud, which is closed off by the transversalis fascia (TF) only. Our previous studies demonstrated structural and quantitative age-related changes of the elastic fibers in TF. Furthermore, we verified lower amounts of collagen and higher amounts of elastic fibers in TF of patients with direct inguinal hernia in relation to indirect ones. These results led us to speculate a genetic defect related to elastin synthesis explaining the participation of extracellular matrix in the genesis of groin hernias. Patients with diagnosed inguinal hernia (10 young and 10 aged) and 20 matched control were analysed for mutations in the elastin gene. Intronic primers were designed to

## Abstracts

amplify each of 34 exons from genomic DNA. Mutations were sought by single-strand conformation polymorphism. Where bands of abnormal mobility were seen, the relevant exon was automatically sequenced. Amplified DNA gave an abnormal band in exon 20 both in young and aged patients with inguinal hernia, which was not present in matched controls. Sequencing revealed a double base substitution (TTT @ TCC) in codon 404 in 78% and 50% of aged and young patients with inguinal hernia, and a single base substitution (AGT @ GGT) in codon 422 in all patients with inguinal hernia and in aged controls. These last point mutations was seen in 40% of young controls. It is possible that such genetic variation of elastin could result in an ensemble of molecules with altered interaction with microfibrillar component or increased turnover that cause disturbances of the TF playing a role in inguinal hernia genesis.

SAKAMOTO\*, Hirokazu, Keiichi AKITA\*, and Tatsuo SATO. Unit of Functional Anatomy, Tokyo Medical and Dental University School of Medicine, Tokyo, JAPAN. Anatomical analysis of the suprarenal arteries.

In 20 body-halves of ten adult cadavers the origin, course and distribution of the suprarenal arteries were examined by minute dissection. In addition to the typical superior and inferior suprarenal arteries, two arteries supplying the central area of the suprarenal gland were observed. (1) The middle suprarenal artery arose laterally from the side of the aorta level with the superior mesenteric artery and supplied the medial margin and the posterior surface close to the lower extremity of the gland. A branch of this artery took a deeper course in the space between the kidney and suprarenal gland to be distributed into the perirenal fat. During its course this branch gave off numerous twigs to the renal surface of the suprarenal gland. (2) A small artery originated from the aorta, inferior phrenic, or renal artery and entered the hilum of the gland from which the suprarenal vein emerge. This relatively constant artery was provisionally named "anterior suprarenal artery" after its entry into the anterior surface of the gland. The anatomy and relationships of the above-mentioned four suprarenal arteries are demonstrated.

SATO, Tatsuo, Hirokazu SAKAMOTO\*, Sadaaki HEIMA\*, Yoko TSUBOI\*, and Keiichi AKITA\*. Unit of Functional Anatomy, Tokyo Medical and Dental University Graduate School, Tokyo, JAPAN. Video demonstration of a dissection of the female pelvic lymphatics.

## Abstracts

In function-preserving operations of female pelvic organs, precise knowledge of the topographical anatomy of the lymphatics and their relationship to the surrounding structures is crucial. As the operational field is very limited in the pelvis, the structural relationships are difficult to view during surgery. Minute dissection from the lateral aspect after removal of the hip bones enables clear demonstration of the arrangement and distribution of the pelvic lymphatics, as well as the relationships to the autonomic nerves. We performed a minute dissection of the iliac and abdominal aortic lymphatic chains in an adult female cadaver and recorded the findings on video. The main focus is on the following items: (1) arrangement of the lymphatics in the vicinity of the iliac arteries and veins including those behind these vessels, (2) drainage of lymphatics from the neck of the uterus, urinary bladder and the lowermost portion of the ureter, (3) posterior lymphatics of the rectum, (4) tracing of lymphatics along the common iliac blood vessels to the paraaortic lymphatic chain, and (5) relationships of the lymphatics to the nerve plexuses and to the fascial structures.

SAXTON, Ernestina H\*, James D. COLLINS, Theodore Q. MILLER\*, Samuel S. AHN\*, and Alfred CARNES\*. Department of Radiology, University of California, Los Angeles, CA. Tremors, chest pain, syncope, hoarseness, visual floaters are unusual clinical symptoms associated with vascular obstruction in patients with thoracic outlet syndrome (TOS): MRI / MRA.

Bilateral magnetic resonance imaging (MRI) and angiography (MRA) display sites of brachial plexus compression in thoracic outlet syndrome patients. Patients with TOS commonly present with pain, numbness, tingling and weakness of the upper extremity (ies). We have evaluated patients with uncommon symptoms not thought to be associated with TOS: hoarseness; loss of singing voice; difficulty swallowing; unusual whooshing sounds in the ear; floaters and colored spots in the visual fields; jaw pain; tremors and involuntary shaking of the arms (legs in some patients); muscle twitches and spasms in the extremities; back pain; abdominal pain and fetid breath; paresthesias and pain in the feet and legs. Complaints were triggered or exacerbated by arm abduction external rotation. Patients were imaged on a 1.5 Tesla magnet (Signa; G.E.) in the coronal, transverse, transverse oblique, and sagittal planes, 4 mm slice thickness, 512 x 256 matrix size with saline water bags to enhance the signal to noise ratio. Abduction external rotation of the extremities and 2D TOF MRA sequences were obtained. This presentation displays sites of vascular compression in patients with:

## Abstracts

residual resected first rib after TOS decompression surgery; aberrant subclavian; straight back with narrowed thorax, and substernal thyroid and lipomas in right neck.

SCOTT, Samuel A., A. Joseph THRELKELD, and Anthony E. KINCAID\*. Department of Physical Therapy, Creighton University, Omaha, NE. Predictors of success in the anatomical science portion of a doctoral-level physical therapy curriculum.

Students in our physical therapy doctorate program take 13 credit hours in the anatomical sciences during their first term (clinical anatomy, kinesiology, and histology). In the admissions process, incoming GRE and GPA data are assumed to be predictive of academic success, and are thus given considerable weight. The purpose of this project was to quantitatively evaluate this assumption based on our five most recent student cohorts (N = 268) using a series of regression analyses. Incoming total GPA served as the best correlate of combined performance on standardized multiple-choice exams ( $r = 0.58$ ). Science GPA ( $r = 0.48$ ), total GRE (0.39), verbal GRE (0.12), and quantitative GRE (0.42) also correlated with student performance, but not as strongly. Correlations also occurred between performances in gross anatomy and histology ( $r = 0.76$ ); anatomy and kinesiology ( $r = 0.76$ ); and histology and kinesiology ( $r = 0.72$ ). These relationships were unaffected by year of program entry. In addition, correlations between each incoming academic criterion and academic performance were strongest among female students. These data suggest that undergraduate GPA, despite its lack of standardization relative to the GRE, is the best predictor of success in the anatomical science portion of this curriculum, especially among women.

SEIFERT, Mark F., and Ronald L. SHEW. Department of Anatomy and Cell Biology, Indiana University School of Medicine, Indianapolis, IN. Tele-illustration: new technologies to enhance teaching.

There are many approaches to teaching and almost as many technologies to support them. Presentation styles in most anatomy courses range from the simple use of overhead transparencies to the use of PowerPoint slides. The evolution of these presentation styles have their own inherent pedagogic advantages and disadvantages. Recent technological advances in LCD touch-sensitive panels, electromagnetic stylus pens, projection devices, and supportive software provide new opportunities for innovations in teaching. We will demonstrate an innovative hybridization of hardware and

## Abstracts

software tools that utilize a Wacom Technologies LCD tablet, bundled with Hitachi StarBoard Presentation Suite software, interfaced with a PC laptop computer and video projector. Any PowerPoint slide show can be executed by the ShareWizard Show program which provides the user a small on-screen toolbar containing an electronic pen and highlighter with a choice of multiple colors and line thicknesses. Notes and annotations can be written over the imaged materials with a stylus pen and saved at the end of a presentation for archival purposes. These novel tools benefit both instructor and learning by: 1.) drawing upon the strengths of commonly used presentation styles, 2.) supporting the principles of active learning, and 3.) providing instructors the opportunity to engage students having different learning styles, hence, enhancing teaching effectiveness.

SEVERSON, Arlen R., and Donna J. FORBES\*. University of Minnesota School of Medicine Duluth, Department of Anatomy and Cell Biology, Duluth, MN. NeuroTime, a computer-assisted learning tool for the neuroanatomy laboratory.

An interactive computer learning tool has been developed and is being used in the Neuroanatomy laboratory at the University of Minnesota School of Medicine Duluth. It is designed to facilitate the learning of neuroanatomical structures, their relationships and terminology. The Three-dimensional organization of the brain is studied using images of intact and dissected gross specimens together with a series of whole brain sections in the coronal, horizontal and sagittal planes. Magnetic resonance images (MRIs) of the brain help the students identify important neuroanatomical structures seen in this imaging modality that will be useful in their future clinical practice. An Identification Mode allows the student to click on the name of a structure so that the structure is indicated by a transparent, colored overlay. A Quiz Mode allows the student to assess their level of knowledge. Since this tool is delivered on CD-ROM for use on any Windows or Macintosh computer, students are able to study all gross specimens, brain sections and MRIs at any time and place that they have access to a computer. Responses to questionnaires completed by the medical students indicate that using NeuroTime is an efficient and effective way to study neuroanatomy. Many students prefer to use the computer program rather than attend scheduled laboratories where formalin-fixed and plastinized specimens are available. The students find that the program facilitates the integration of the neuroanatomical gross and sectioned

## Abstracts

material with the interpretation of MRIs. Instructors find that it is much more time efficient using the NeuroTime images for both the laboratories and exams. Since health science faculty and students outside of the School of Medicine Duluth have been interested in using this educational tool, the University has made it available through the Center for Technology Enhanced Education and Research (CTEER). A demonstration of the program is available at: <http://www.neurotime.com> (Sponsored by the MMF and UM-AHC).

SHERMAN\*, Jonathan H., and Gene L. COLBORN. Medical College of Georgia and the Departments of Cell Biology, Anatomy and Surgery, Augusta, GA. Absence of left inferior thyroid artery - clinical implications.

Medical student dissection of an adult male cadaver at the Medical College of Georgia revealed a variation of the left inferior thyroid artery in which its distribution to the thyroid gland was replaced totally by the right inferior thyroid artery. The inferior thyroid artery arises most commonly from the thyrocervical trunk, passes behind the carotid sheath, and supplies the inferior pole of the thyroid gland. The artery also typically runs anterior, between, or posterior to branches of the left recurrent laryngeal nerve. Absence of the left inferior thyroid artery occurs in 0.2% to 5.9% of cases. In thyroid surgery, it is imperative to identify the relationship of the inferior thyroid artery to the recurrent laryngeal nerve because the major complication of this type of surgery is nerve injury. Awareness of this and other significant variations of the surgical anatomy of the thyroid gland are vital for maintaining safety in thyroid surgery.

SONEIRA, Carlos F., and William R. HAVILAND\*. Departments of Clinical Science and Physical Therapy, University of Wisconsin-La Crosse, La Crosse, WI. The use of handouts and clinical cases in a gross anatomy course for allied health professions.

A questionnaire was developed in order to assess the students' opinion regarding the use of lecture handouts and clinical cases. Answers for all questions were recorded using a 1-to-5 Likert-type scale. Seventy-three students (49 females, 24 males) were surveyed. The sample was divided into four groups: physical therapy (38), physician assistant (12), nurse anesthesia (8), and occupational therapy (15). The majority of the students (93.1%) reported that handouts were well organized and contained accurate information, that the written material corresponded with the objectives of the course (94.5%), and that handouts helped them to follow and understand the lectures better (86.3%). Most of the students (90.4%)



## Abstracts

reported that the handouts were the main source of information they used for independent study. A large number of students (73.9%) felt that the use of clinical cases added meaning to the study of anatomy, and most of them (89%) reported the need to use the textbook to work through the questions of the cases. One-way ANOVA showed statistical differences between the responses of the four groups. The most significant trend observed was that nurse anesthesia students gave handouts and clinical cases lower scores than students in the other three groups. The use of handouts and clinical cases is a quality addition to our Gross Anatomy course and has been well received by the students.

SONEIRA, Carlos F, and William R. HAVILAND\*. Departments of Clinical Science and Physical Therapy, University of Wisconsin-La Crosse, La Crosse, WI. Anatomical variations of the digastric muscle: a report of two cases.

Anatomical variations of the anterior belly of the digastric muscle were found in two embalmed human cadavers during the dissection of the anterior triangle of the neck in a Gross Anatomy course. In the first case (female, white, 87 years old) the anterior belly of the right digastric muscle had two accessory bellies, which formed a triangle with the main anterior belly. Both accessory bellies attached to the middle portion of the mylohyoid muscle at the midline. The posterior accessory belly attached laterally to the intermediate tendon of the right digastric muscle. The anterior accessory belly had a mandibular attachment, just medial to the right digastric fossa. In the second case (female, white, 78 years old) there was a thin, rectangular muscle located between the anterior bellies of both digastric muscles and inferior to mylohyoid. Anteriorly, the fibers of this accessory muscle attached to the mandible between the right and left digastric fossae. Posteriorly, the muscle fibers did not reach the hyoid bone, but attached to the fascia connecting the anterior bellies of both digastric muscles.

STEFAN, Cristian. Department of Basic Sciences, Pikeville College School of Osteopathic Medicine, Pikeville, KY. Is there still a need for the use of wet specimens in the medical neuroscience course?

At a time when the very issue of dissection in the medical education is debated, the use of wet specimens in the Neuroscience courses is also questionable. Taking into consideration major factors like the impact produced by the expanding use of virtual reality in medical education and a general tendency in limiting/reducing the contact hours, we continuously adapted our Neuro lab component with the

## Abstracts

goal of increasing its relevance and efficacy. The key principles, highlighted by the planning, tuning, and evaluation process over several years, include: (1) devoting 7-8 two-hour sessions of labs with wet specimens in the first part of the course, which will be replaced with sessions of case studies in the second part, (2) supplementing, not replacing the study of wet specimens with valuable aids (printed, electronic, or video format), (3) dissection of brains being done exclusively by instructor(s), (4) approaching the morphology based on its relevant functionality and clinical significance, the same principle governing the testing system, (5) emphasizing clinical imaging correlations commencing with the first day of the course, (6) increasing the clinical relevance and solving problems skills by identifying and preserving pathological specimens, which are discussed in the lab, (7) assuring the delivery of an even core of information to the entire group of students by use of adequate audiovisual equipment in the lab, (8) scheduling the lab practical test at the middle of the course instead the end of it, and (9) reinforcing the material studied in the lab during patient simulation program sessions. In conclusion, timing, format, and integrative manner approach are essential in order to retain the use of wet specimens as a highly valuable resource in the Neuroscience course for medical students, along with using or developing virtual programs. They enhance the three-dimensional experience, increase the interest in the matter, provide a better appreciation of individual variability, and reinforce the respect for human body and life.

STEFAN, Cristian, William T. BETZ \*, Anca M. STEFAN \*, Department of Basic Sciences and Department of Family Medicine, Pikeville College School of Osteopathic Medicine, Pikeville, KY. Stepping forward regarding the integration between the clinical skills and gross anatomy courses.

The early integration of basic and clinical science courses remains a major goal in medical education. During the Fall Semester 2001, the structure and timing of the Clinical Skills (Introduction to Clinical Medicine) course was revised and adapted for a better sequential coordination with the Gross Anatomy course. The contact hours were not increased but redistributed and the changes in the Clinical Skills course included: (1) spreading the lectures over the entire Fall Semester, (2) adjusting the topic order where appropriate, (3) revising the format and objectives of the lab sessions, (4) testing the material in a more correlative manner, and (5) incorporating the review of anatomical concepts in computerized patient simulation

## Abstracts

PBL sessions with first and second-year students. The result was a smooth flow of information of material presented in the two courses. More than 80% of the topics were discussed in a sequential order starting with Gross Anatomy and followed, within 1-2 weeks, by the same topic in the Clinical Skills lectures and then in the Clinical Skills laboratory sessions. Having faculty teaching in both courses also created more continuity in the stream of applied information. Plans for further expanding and tuning the curricular integration between Clinical Skills and Anatomical Sciences in the next academic year include: (1) the review and remodeling of the Gross Anatomy course, which will also merge with the Developmental Anatomy, (2) strengthening the role of clinical imaging as an interdisciplinary link, and (3) continuing to center the educational emphasis on developing problem-solving abilities.

STEIN\*, Tamara A., Caren M. STALBURG\*, Thomas R. GEST, and William E. BURKEL. Division of Anatomical Sciences and Department of Obstetrics and Gynecology, University of Michigan Medical School, Ann Arbor, MI. Fourth year gross anatomy electives: clinically relevant courses for clinically prepared students. Traditionally undergraduate medical education is divided into pre-clinical and clinical years with basic sciences taught during the first years and clinical sciences taught during the latter years. In an effort to better integrate the basic and clinical sciences in undergraduate medical education, we have developed new fourth-year electives at the University of Michigan Medical School. These electives are intensive month-long courses in advanced clinical anatomy designed to address a specific region and to be taught within a clinical context. In addition to cadaveric dissection, clinical-correlate sessions are presented by faculty from a variety of clinical departments. In the fourth year, students have finished the core clinical clerkships and are well prepared and motivated to revisit gross anatomy in more depth while utilizing their newly developed clinical framework. Currently we have developed and taught four courses: Clinical Anatomy & Women's Health, Musculoskeletal Anatomy, Surgical Anatomy, and Head & Neck Surgical Anatomy. In both formal and informal evaluations, all of the courses have been very successful. This presentation will specifically address the Clinical Anatomy & Women's Health elective; outlining the curriculum and discussing the outcomes of competency-based assessment.

## Abstracts

STEWART\*, Fiona<sup>1</sup>, Gregory J. LESLIE<sup>2\*</sup>, and Richard H. WEST<sup>3</sup>.  
<sup>1</sup>Department of Anatomy and Histology, University of Sydney, NSW,  
<sup>2</sup>Departments of Surgery - Liverpool, Bankstown, Dubbo Hospitals,  
N.S.W. and <sup>3</sup>Royal Australasian College of Surgeons, Melbourne,  
Victoria, AUSTRALIA. (Sponsored by B.R. MacPherson). Gross topographical anatomy by dissection for basic surgical training candidates - development and implementation of a course at the University of Sydney.

The level of anatomical knowledge of medical graduates of new curricula courses, in Australia and other countries, in which gross topographical anatomy teaching by dissection has been abolished fails to meet the knowledge presumed by RACS's BST Part I Anatomy Examination. A whole body dissection course for remediative teaching of regional and applied gross topographical anatomy to Basic Surgical Trainees was developed and launched in N.S.W. by the authors. In December, 2000 First Australasian Gross Topographical Regional Anatomy by Dissection with Application course (trunk and neck) for RACS BST candidates; duration - five days; venue - University of Sydney; teaching - medical graduates representing major Sydney and regional teaching hospitals. Survey and candidate assessment confirmed the educational deficiency in regional gross topographical anatomy and demonstrated the learning value of this dissection course. Candidates recommended dissection of the whole body be offered in subsequent courses. RACS Part I Examination, 2001, yielded a 99% pass outcome at first attempt for participants of the course. In December, 2001, BST Dissection Course (whole body); duration - seven days; venue - University of Sydney; teaching - as previous. Candidate surveys of regional anatomical and relational knowledge - before and after the course confirmed the deficiency in knowledge and remedial value of this dissection course. Candidate's successful assessment outcomes at course-completion and their positive feed-back concerning the value of this dissection course as a learning and remediative experience was unanimously acknowledged.

THLIVERIS James A., Mark G. TORCHIA\*, Richard NASON\*, Steven AHING\*. University of Manitoba, Departments of Human Anatomy and Cell Science, Surgery, and Oral Pathology, Winnipeg, MB, CANADA. Intratumor vessel size distribution is a predictor of metastatic phenotype and tumor recurrence in patients with early stage squamous cell carcinoma of the oral cavity.

The goal of this project was to determine whether intratumor microvessel size-distribution, determined using CD-34 staining, could

## Abstracts

be a improved marker compared to microvessel density for metastatic phenotype and patient outcome in early oral carcinoma. Thirty one archived tissue samples were analyzed from patients with squamous cell carcinoma of the oral cavity and stained by H&E and for CD-34; a glycoprotein marker for endothelial cells. Microvessel density was calculated according to consensus methods. The largest dimension of each vessel diameter was determined using a calibrated reticle and was categorized into <10 mm (capillary), 10-25 mm (terminal arteriole, small venule), and >25 mm (arteriole or venule). Microvessel density was not related to tumor size, positive node status, number of positive nodes, tumor recurrence or patient survival. Percentage of large vessels (>25 mm) in a high power field increased with tumor size ( $p<0.05$ ). Patients with a high percent of smaller vessels (median split) were less likely to have positive nodes at the time of diagnosis ( $p<0.05$ ), while those with a high percent of larger vessels were more likely to have positive nodes at the time of diagnosis ( $p<0.03$ ). Higher large vessel percentage was associated with increasing tumor stage ( $p<0.05$ ). Patients with high percent of small vessels in their tumors had a longer time to recurrence (4.7 y vs 1.0 y,  $p<0.002$ ) and increased overall survival (90 mos vs 12 mos,  $p<0.001$ ). Microvessel size distribution in oral squamous cell carcinoma appears to be a useful predictor of metastatic phenotype and patient outcome.

TRELEASE, Robert B. Department of Pathology and Laboratory Medicine, UCLA School of Medicine, Los Angeles, CA. Computational anatomy: agenda for a newer frontier.

As one of the most ancient of sciences, anatomy traces its roots back through the ancient Greeks. Anatomical research tools have evolved over many centuries, encompassing dissection instruments, stains, microscopes, cameras and photography, radioactive tracers, digital imaging systems and others. While anatomy has long been considered an important and prominently reductionistic science, other disciplines have advanced biological structural and functional reductionism into exclusive domains. Molecular biology and its methods came to dominate biomedical research in the latter half of the twentieth century, and anatomists have seen their scientific interests subrogated to research focused primarily on subcellular processes. Thus, structural biology has come to indicate the study of functional macromolecules at the cellular level, and computational biology has been restricted primarily to the application of informatics methods to genomics and proteomics. While those who proudly call themselves anatomists have clearly excelled at cellular, molecular,

## Abstracts

and genetic research, there is a strong rationale for defining computational anatomy as a proper subdiscipline dealing exclusively with anatomical interests, especially those integrating information from supracellular, systemic, and organismal levels. In computational anatomy, important scientific advances continue to be made with informatics methods including image processing, visualization, virtual reality, structural database processing, networking, and artificial intelligence.

TUBBS, R. Shane\*, John C. WELLONS III\*, George SALTER, W. Jerry OAKES\*. Pediatric Neurosurgery, Children's Hospital, and Department of Cell Biology, University of Alabama at Birmingham, Birmingham, AL. Fenestration of the superior medullary velum for the trapped fourth ventricle.

We have developed a novel approach for the potential fenestration of the trapped fourth ventricle utilizing the superior medullary velum (valve of Vieussens). Trapped fourth ventricles, which are often seen in the pediatric hydrocephalic population, are surgically troublesome entities to address. A right craniotomy was performed in ten adult cadavers with no gross intracranial pathology and the superior medullary velum fenestrated to the quadrigeminal cistern with the aid of an endoscope. This technique was performed easily in all cadaveric specimens. With endoscopy, no vascular insult was appreciated either before or after fenestration of the superior medullary velum. These preliminary findings demonstrate that fenestration of the superior medullary velum may provide a good alternative to the present therapy of shunting trapped fourth ventricles and could become a potential method for avoiding many of the complications often ensuing fourth ventricular shunting. Although anatomically a dangerous area, we feel with careful endoscopy the superior medullary velum can be easily accessed. This technique now requires clinical trials to reveal its efficacy in treating the trapped fourth ventricle.

WALKER, James J., J. Leslie BOOTH\*, James F. KIMBROUGH\*, and Amy S. RECKTENWALD\*. Lafayette Center for Medical Education, Purdue University and Indiana University School of Medicine, West Lafayette, IN. Creation of a technologically enhanced educational environment: Augmentation of existing resources for teaching human gross anatomy and embryology.

The long-term goal of this project is to create a comprehensive ensemble of Technologically Enhanced Educational resources to help students learn Human Anatomy. Our major objective is to

## Abstracts

create an interesting and effective learning environment that will facilitate the student's ability to understand and retain useful information. We have done this by providing them with access to challenging and information-intensive electronic learning resources that maximize the integration of basic and clinical sciences. Thus far we have developed three major components that serve as the foundation of our efforts; (1) *Anatomy Interactive* (<http://www.anatomy-interactive.org>) Web portal that provides worldwide access an comprehensive array of anatomy-related resources via the Internet; (2) The *Interactive Notes (i-Notes)* series (*Human Gross Anatomy and Embryology* and *NeuroNotes*) of electronic course notes offered via CD ROM and; (3) *Difficult Concept Series (Interactive Cranial Nerves)* of CD ROM's dealing with problematic topics in anatomy. We have also developed an initial series of instructional animations (using Macromedia's *Flash*) covering heart development and gut rotation and a new series of short, interactive learning modules using *Viewlet* technology (*Qarbon, Inc.*). These modules are designed to provide a dynamic user interface for students to independently study topics such as anatomy pre-laboratory exercises and clinical correlation concepts. The major goal of this project is to create a topic-specific interactive learning environment that serves as a national/international medical education resource. We predict that the greatest impact of these educational materials will be to provide users with efficient access to high quality, information-intensive resources dealing with Human Anatomy. Each of these projects is aimed at creating a comprehensive, dynamic educational environment that enhances the effectiveness of learning while producing fast, scalable, and functional learning resources that are used regularly. (Sponsored by a grant from the Indiana University School of Medicine)

WEIGLEIN, Andreas H., Peter UMFÄHRER\*, Gert SANTLER\*, and Klaus PREIDLER\*. Institute of Anatomy, School of Dentistry, MRI Institute, Karl-Franzens University Graz, AUSTRIA. Mandibular nerve block - anatomical study of a modified technique.

Mandibular nerve block anesthesia is a frequently used routine dental procedure. Exact knowledge of the target area's anatomy and its possible variations is the prerequisite for a successful application of any technique for mandibular block anesthesia. In a head specimen the infratemporal fossa and the pterygomandibular space were dissected from medial to expose the possible pathway of the injection needle. After definition of the needle's pathway dyed plastic solution was injected in eight head specimens using a modified Gow-

## Abstracts

Gates technique. The distribution of the "anesthetic" was evaluated both by cryogenic sectioning and by anatomical dissection. Furthermore, in three volunteers contrast medium deposits were evaluated by MR-studies and three-dimensional reconstructions. The distribution of the injected "anesthetic" showed a certain regularity in both anatomic and MRI studies; in all cases the inferior alveolar and the lingual nerves were embedded, and in 50 % of cases also the buccal nerve was surrounded. The modified Gow-Gates technique shows advantages, which are due to the more cranial location of the anesthetic solution compared to Fisher's technique. Because of its universal applicability, which is independent of both patient's age and tooth-status, it constitutes a highly recommendable and promising alternative.

WHITWORTH\*, Richard H. JR., Tracey LEGROS\* and Peter DEBLIEUX\*. Department of Cell Biology & Anatomy and Department of Emergency Medicine, LSU Health Sciences Center, New Orleans, LA. (Sponsored by W.J. Swartz). Introduction of clinical procedures to freshman medical students using fresh cadaveric material.

Increased emphasis has been placed on introducing medical students to clinical aspects of medicine as early as possible. For the past two years, first year medical students at LSUHSC have participated in cadaver procedure laboratories during the first semester as a supplement to the regular Medical Gross Anatomy course. Three specialized laboratories enable these students to perform specific emergency procedures on fresh cadaveric specimens. Emergency Medicine staff explain the anatomical basis of selected clinical procedures and demonstrate them to groups of approximately 40 students. These procedures include lumbar puncture, endotracheal intubation, chest tube placement, pericardiocentesis, and Foley catheter insertion in a male and female. The procedures selected for instruction involve the anatomical areas concurrently being dissected in the Medical Gross Anatomy course so that important correlations can be made between the gross anatomy and the clinical procedure. Following the faculty demonstration each student individually performs the procedure under the close supervision of the instructor. These procedures are performed on fresh cadaveric specimens which contributes to the clinical realism for the students. Student evaluations rate this experience very high. This hands-on, small group experience is an excellent means of demonstrating the anatomical basis of clinical medicine to first-year students.



## Abstracts

WINDHOFER\*, Christian, Erich BRENNER, Chritoph PAPP\*, and MORIGGL, Bernhard. University of Innsbruck, Institute of Anatomy and Histology, Innsbruck, Department of Plastic and Reconstructive Surgery, Hospital Barmherzige Brueder, Salzburg, AUSTRIA. The descending branch of the inferior gluteal artery and the posterior femoral cutaneous nerve: basic anatomy, interdependence and relevance for flap surgery.

The structures addressed play an important role in performing flap surgery in the distal part of the gluteal region. Surprisingly, no detailed description of their relationship is available as existing papers are mainly clinical studies and present with low numbers. Our anatomical study includes 118 gluteal regions of both sexes (mean age: 78a). The descending branch of the inferior gluteal artery (IGA) was present in the vast majority of cases (91,5%), constantly giving rise to at least one cutaneous branch ( which runs around the lower border of the gluteus maximus muscle). In case of absence of the former, the latter either came from the circumflex femoral arteries or from a perforator of the deep artery of thigh. In 78 specimens (72%), the descending branch of the IGA and the posterior femoral cutaneous nerve (PFCN) ran in a common sheath of connective tissue. Nerve loops around the descending branch of the IGA formed by the PFCN were present in 29%. Considering the results of our study we conclude that in the distal part of the gluteal region a fasciocutaneous flap can be reliable lifted on a cutaneous offspring of the descending branch of the IGA. However, the considerable range of variation of the PFCN in the gluteal region (especially as far as various nerve loops are concerned) may reduce moderately the arc of rotation of a local flap. Apart from very few cases of nerve perforation, this problem does not occur in case of performing a free flap.

WINESKI, Lawrence E.,<sup>1</sup> Perry RIGGINS,<sup>2\*</sup> Rebecca A. SEALAND.<sup>2\*</sup> Department of Anatomy & Neurobiology<sup>1</sup>, Division of Information Technology Services<sup>2</sup>, Morehouse School of Medicine, Atlanta, GA. T.I.P.S.: A computerized study guide for the temporal, infratemporal, and pterygopalatine regions.

The temporal, infratemporal, and pterygopalatine regions of the head are challenging topics to anatomy students because of the combination of (1) The spatial relationships of the regions themselves, and (2) The need to understand the functional relationships of the structures that distribute through these regions. We have produced an interactive study guide to these areas, in CD-ROM format. This utilizes scrolling text, selected (edited) images

## Abstracts

from LifeART Medical Clip Art Grant's Atlas 10<sup>th</sup> edition (Lippincott Williams & Wilkins, copyright 2000, permission granted), original animations, and photo and video clips (Apple Quicktime Viewer 5.0 required) of anatomical specimens. The program is organized around seven units: (1) Anatomical regions, (2) The masticatory apparatus, (3) Innervation, (4) Vasculature, (5) Self-testing, (6) Text and image library, (7) Glossary. Beta testing included independent student use of the CD in place of a traditional lecture on this material. Student response has been overwhelmingly positive. They particularly like the combination of still- and video-imaging, and the independence this format provides. Overall, they feel the CD allows more effective use of their time and enhances their learning of the material. However, student opinions are more mixed as to whether the CD should be used as a substitute for a classroom lecture vs. a supplement to a traditional lecture.

WON H.S.\*, I.H. CHUNG\*, J.S. PARK\*, C.S. OH\*. Department of Anatomy and Brain Korea21 Project for Medical Science, Department of General Surgery, Yonsei University College of Medicine, Seoul, Korea, Department of Anatomy, Sungkyunkwan University, School of Medicine, Suwon, KOREA. Morphologic variations of the thyroid isthmus and its clinical significance.

This study was performed to identify the morphologic characteristics of the isthmus in one hundred cadavers. The average distance from the inferior margin of the cricoid cartilage to the superior and inferior margins of the isthmus were  $4.9\pm 3.7\text{mm}$  and  $20.8\pm 5.8\text{mm}$ , respectively. The average length between the superior and inferior margins of the isthmus was  $15.9\pm 5.8\text{mm}$ . The thyroid isthmus was classified into four types. In Type I, the lateral lobe and isthmus of thyroid gland could be distinguished clearly (30.0%). In Type II, the two parts could be distinguished, but the width of both lateral lobes was narrow. In Type III, the inferior margin of the isthmus and the lateral lobe made a line (33.0%). In Type IV, the isthmus could not be distinguished because both lateral lobes were combined (6.0%). The isthmus located between the 1st and 3rd rings, between the 2nd and 4th rings were 18.0%, and 22.0%, respectively. We observed that the inferior margin of the isthmus located below the 4th tracheal ring was 13.0%. The location of the isthmus was described between the 2nd/1st and 4th tracheal rings in many anatomical texts. These data might help to reduce the possible injury of the thyroid isthmus during the tracheostomy.