



# Effectiveness of an Electronic Gross Anatomy Dissector for First Year Medical Students

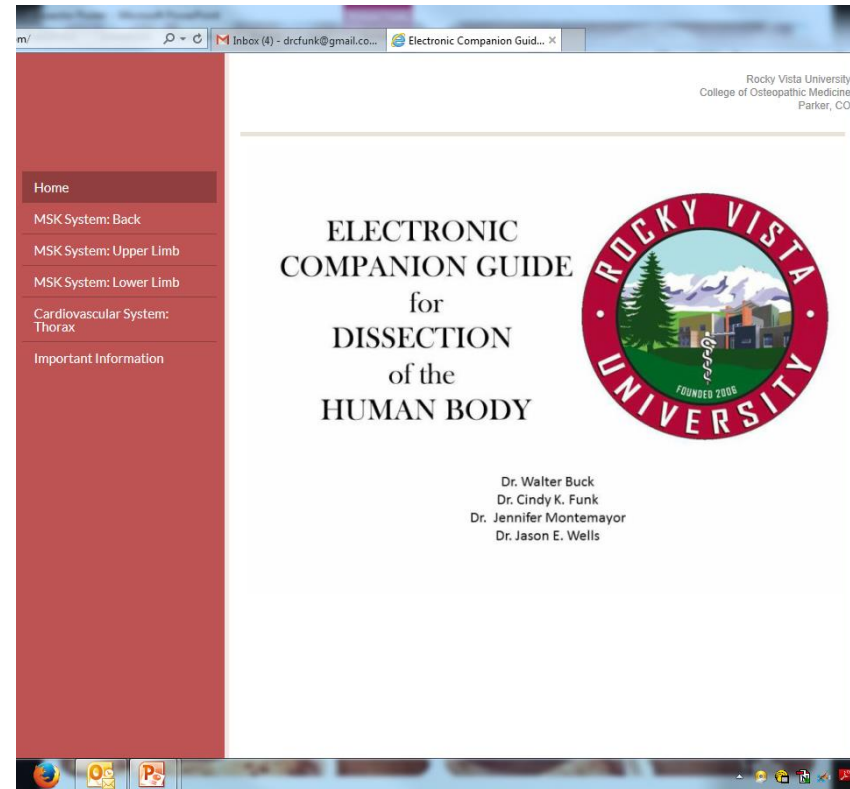
Funk, C.K., Montemayor, J.R., Wells, J.E., and Buck, W.B.  
Rocky Vista University, College of Osteopathic Medicine, Parker, CO 80134

# INTRODUCTION

1. A new educational tool was created by Rocky Vista University faculty with the intent of enhancing student learning through preparation for cadaver dissection and review of anatomical structures prior to practical examinations.
2. The new dissection guide is an electronic, online version of our printed dissection manual with real images of cadaveric structures linked to dissection directions for anatomy lab.

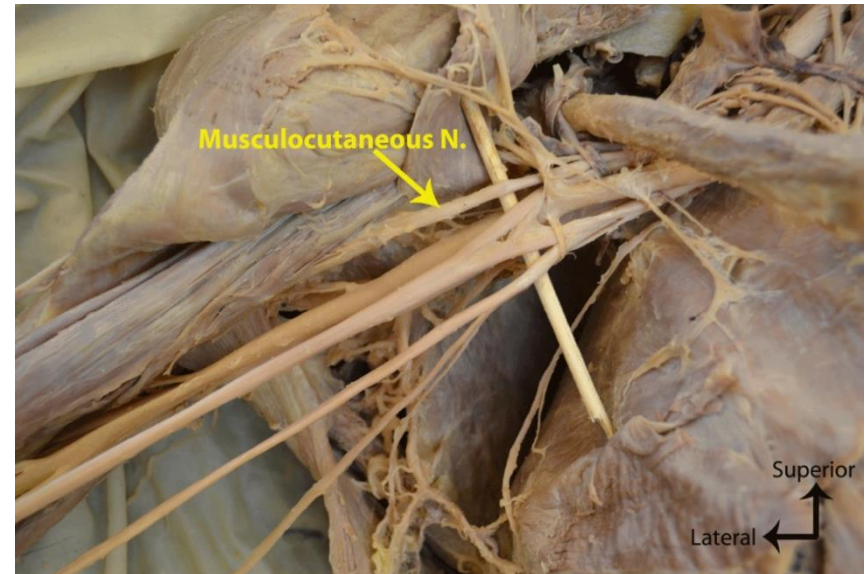
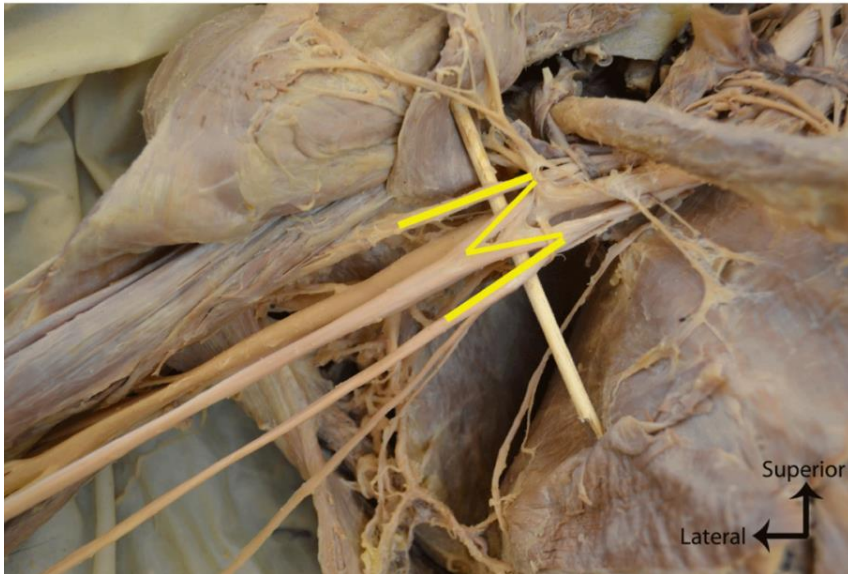
## Suboccipital Triangle:

1. Locate the **occipital artery** coursing **deep** to the splenius and superficial to the semispinalis as it passes superolaterally toward the occipital region of the scalp. If possible, clearly define and retain this structure on one side.
2. Return to the semispinalis capitis muscle. Using a #22 or 23 scalpel blade, make a **vertical** incision along the nuchal ligament between the two opposed **semispinalis capitis** muscles. Carry this incision from the skull above to approximately the seventh cervical vertebra below and in the midline to the depth of the skull and spinous processes. **Do not be afraid to make this incision as there are no structures located on the midline in this area.**
3. Using your thumbs, carefully pry the two semispinalis capitis muscles **laterally** until you can palpate the underlying spinous processes. Starting at CV7 (vertebra prominens) and moving cranially, palpate **all** cervical spinous processes. What do you notice about the character of the last palpable spinous process? This should be the spinous process of CV2. Identify the **semispinalis cervicis** muscle as it ends at CV2; it is pointing to the suboccipital triangle located directly **superiorly**.
4. **Beginning medially and moving laterally, carefully shave** the semispinalis capitis from the skull. As you separate it from the nuchal ligament and reflect it inferiolaterally to gain access to the suboccipital region, you should notice a connective tissue interval under which are located the suboccipital muscles. **Also**, look for the **greater occipital nerve (dorsal ramus C2)** piercing this muscle medially. Once you locate this nerve, follow it on the **deep** surface of the semispinalis capitis muscle. Buried in this tough connective tissue layer, it will first course **superficial** to the **obliquus capitis inferior** and then disappear **inferior** to this same muscle. **Preserve as much of this nerve as possible.**



## METHODS

1. Pro-section of cadaver by anatomy faculty and fellows.
2. Created photographic images of cadaver tissue to go along with written dissector steps.
3. Added animations using Adobe Photoshop CS5.1
4. Hyperlinked animated images to online dissection manual (<http://www.rvuanatomy.com/>)



## EVALUATION

1. Compared subjective and objective data from two classes of first year medical students. The Class of 2015 (n=165) had no access to the electronic dissector (only had access to the printed). The Class of 2016 (n=165) had access to both printed and electronic dissectors.
2. Subjective (student feedback) data show that students preferred the electronic dissector to the printed dissector (data not shown).
3. Student feedback also revealed that students used the electronic dissector for a greater amount of time for: preparation for lab and for quizzing purposes (data not shown).

## EVALUATION

1. Compared subjective and objective data from two classes of first year medical students. The Class of 2015 (n=165) had no access to the electronic dissector (only had access to the printed). The Class of 2016 (n=165) had access to both printed and electronic dissectors.
2. Objective data (anatomy practical grades) demonstrated an improvement on the very first anatomy practical for the class which utilized the dissector.

