

American Association of Clinical Anatomists




American
Association
of Clinical
Anatomists

39th

ANNUAL MEETING

F O R T W O R T H ♦ T E X A S

JUNE 13-17, 2022



hsc

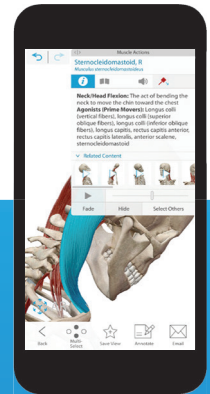
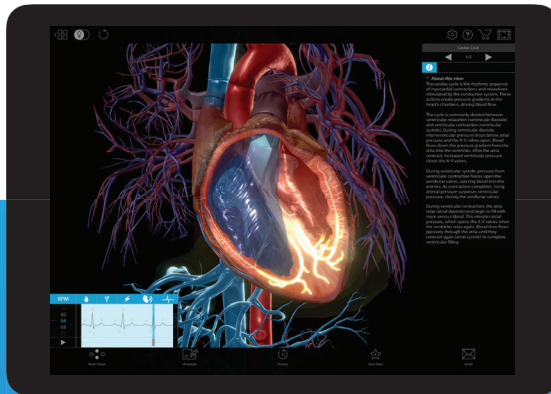
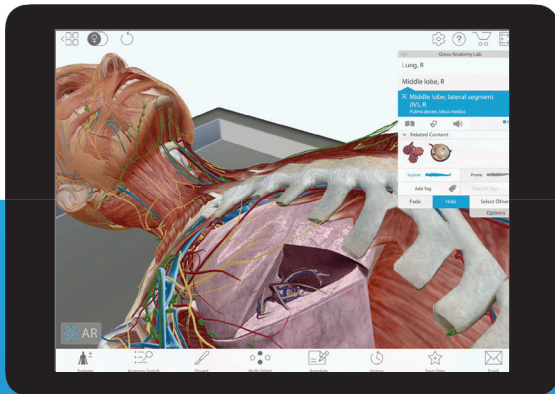


BioSkills of
North Texas

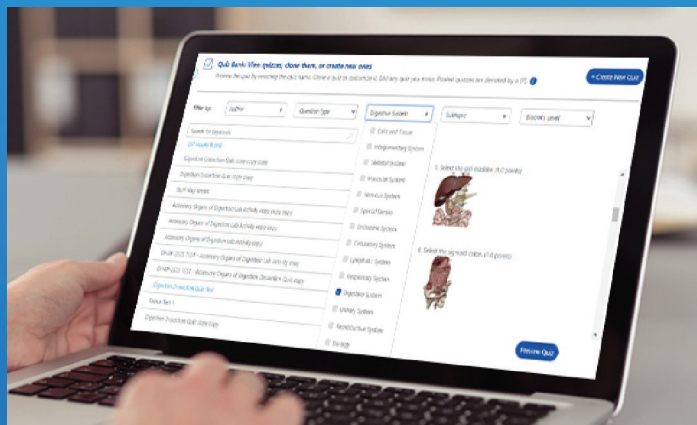
www.clinical-anatomy.org



Taking Virtual & In-Person Learning to New Heights



Visually engaging 3D + AR human anatomy and physiology content that's increasing grades and saving professors time.



Our LMS Courseware maps to any textbook, features Canvas deep integration and Blackboard single sign-on, and allows professors to autograde A+P labs, annotate 3D models, assign immersive dissection quizzing, custom share links on web (PC/Mac) and mobile, and so much more.

Be sure to visit us during the Exhibitor Session
June 14 - 16 at Booth #7

To request a free trial, scan here:



VISIBLE BODY

Dear Fellow AACA Members,

The University of North Texas Health Science Center at Fort Worth (HSC) is proud to host the 39th annual meeting of the American Association of Clinical Anatomists, June 13 – 17, 2022 and we look forward to welcoming you to Fort Worth. The meeting sessions will take place in The Worthington Renaissance Hotel in downtown Fort Worth (FW), which is surrounded by dozens of restaurants, bars, and art and entertainment districts. The post-graduate course will be hosted by the BioSkills of North Texas on the HSC campus about 3 miles west of the hotel. For those of you who wish to partake in some sightseeing while you are here, the following information plus the AACA meeting website will help you plan. Feel free to contact us with questions.

Weather – June can be hot. Average highs - 94F (34C), lows - 72F (22C). Average June rainfall is 3.6 inches.

Transportation – Dallas Fort Worth International Airport (DFW) is located 23 miles northeast of downtown Fort Worth. TexRail will take you from DFW to Fort Worth Central Station in about 45 minutes, with a 10-block taxi/Uber ride to the hotel. From the airport, taxis (~\$49), Uber, and Lyft (~\$33) are the fastest options. Renting a car is very convenient and driving is easy in Fort Worth. The airport supports all the usual rental car companies. The hotel provides self-parking or valet parking at reasonable rates.

Hotel Accommodations – The meeting will take place at The Worthington Renaissance Fort Worth Hotel. <https://www.marriott.com/en-us/hotels/dfwdt-the-worthington-renaissance-fort-worth-hotel/overview/>

Points of Interest – Come early and stay after to enjoy the history, art and architecture of Fort Worth and surrounding areas. One event we would like to highlight is the Finals for the Van Cliburn International Piano Competition from June 14-18 each night at the Bass Hall about 2 blocks from the hotel. If interested, tickets can be purchased at <https://www.basshall.com/>

- Sundance Square is a 35-square block shopping and entertainment district located in the heart of downtown Fort Worth. This includes the Worthington Hotel where guest will be staying.
- Dining, shopping, clubs, comedy shows, piano bars all encompass the downtown district. All within walking distance (or Uber if needed) of the hotel. Downtown FW is clean and safe for late night enjoyment.
- The Fort Worth Stockyards is a unique entertainment district that once was the area of town where cattle from all over Texas were driven to market. Cattle drives daily. <https://www.fortworthstockyards.org>
- The Cultural District (adjacent to UNTHSC) has four major museums for great entertainment
- The Texas Rangers MLB team plays the Houston Astros June 13-15. Tickets <https://www.mlb.com/rangers/tickets>
- Great biking/hiking trails along the Trinity River just off downtown (2-3 blocks north of hotel)
- Visit Fort Worth – guide for dining and entertainment in Fort Worth:
<https://www.fortworth.com/Fort-Worth-Events-Festivals-Music-Sporting-Events>

Post-Graduate Course – June 17, 2022. The post-graduate course will take place on the HSC campus in the new BioSkills of North Texas laboratory on Friday. The course is designed to appeal to anatomists and clinicians.

Welcome to Fort Worth!

Rustin Reeves and Cara Fisher

Center for Anatomical Sciences

*The University of North Texas Health Science Center at Fort Worth
AACA 39th Annual Meeting local hosts*



President's Report

June 13–17, 2022
AACA Annual Meeting

PO Box 2945
LaGrange, Ga 30241
Ph: 706-298-0287

www.clinical-anatomy.org

Welcome to Texas and our first in-person annual meeting for the AACA since 2019. Our MOPP (Meeting Organization and Program Planning) committee and our hosts at the University of North Texas Health Science Center have prepared a warm welcome and scientific, organizational, and social sessions that will be full of useful information and will provide ample opportunities to grow your network of academic contacts. If you are a new member of the AACA, don't be shy to make contacts with our older established members. And whether you are a new AACA member or not, I encourage you to become active in your association. Attend the meetings of our committees and special interest groups and consider joining those that align with your professional interests.

And speaking of our special interest groups and standing committees, they have been busy and productive during the past year. Thanks to all of the AACA members who have devoted their time and energy to the work that our committees have performed.

I hope you had a chance to visit the AACA booth at the Experimental Biology meetings in Philadelphia in April. Our booth presence there was intended to make FASEB attendees aware of the opportunities to grow a person's network of professional contacts that membership in AACA offers. Be sure to tell your colleagues how beneficial membership in the AACA can be.

We greatly appreciate the support of our vendors and corporate sponsors. As a member of AACA, please express your gratitude of this support to our sponsors. Thanks to our friends and colleagues at Association Services Group. The tremendous support of AACA that Caitlin Hyatt, Jennifer Whitlow, Kendra Tyner, and the rest of the ASG crew provides is greatly appreciated. And finally, thanks to Rob Spinner, who assumed Presidency of the AACA during a daunting period, and whose steady-handed guidance kept our association afloat and on course through the stormy seas of the COVID pandemic.

Thomas R. Gest, Ph.D.
President

The AACA believes that each conference attendee should be treated with respect and dignity and that any form of sexual harassment is a violation of human dignity. The AACA condemns sexual harassment and maintains a "zero - tolerance" for sexual harassment. All conference attendees have the right to participate and learn free of sexual harassment. The AACA will take all reasonable efforts to prevent and promptly correct instances of sexual harassment. Any conference attendee who believes himself or herself to be a victim of sexual harassment is encouraged to report the information to the Program Secretary.

AACA on Social Media



Like Us on Facebook!



News



Events



Connect

Like AACA on Facebook to stay up-to-date on all the latest news and events and to connect with other members.



American Association of Clinical Anatomists

Visit <https://www.facebook.com/aacapage/> or scan the code with your phone!



Follow us at the AACA LinkedIn Page



To stay up to date with the news



Discover new job opportunities



Connect to other members

Go to <https://www.linkedin.com/company/american-association-of-clinical-anatomists>

Or scan with your phone using any QR code reader



Tweet with Us!

@AACAnatomy



@AACAnatomy is the Association's official Twitter account

We use Twitter to increase engagement with our Membership, professionals, and the public.

Join us on Twitter!

New to Twitter?

Use these steps to make an account!

1. Go to www.twitter.com
2. Click Log-in
3. Select Sign Up under "New to Twitter?"
4. Create username and password
5. Sign Up!
6. Find our account [@AACAnatomy](https://twitter.com/AACAnatomy) and follow
7. Tweet away! Share tweets all meeting long using the conference hashtag **#ClinAnat22**

Already on Twitter?

Follow [@AACAnatomy](https://twitter.com/AACAnatomy) and share conference tweets using the hashtag **#ClinAnat22!** Feel free to tweet anything that interests you during the conference – sessions, events, what you learn, posters, social gatherings, meetings, photos, etc. You can also tweet anytime using the hashtag **#ClinAnat.**



Ask your colleagues if they have a Twitter account. Follow AACA members and colleagues to make our Twitter community even stronger!


Pick up your "I Tweet" ribbon at the registration desk!

Table of Contents

Exhibitors	1
Meeting Sponsors	4
Scientific Program.....	5
Honored Member – Cornelius Rosse, MD, DSc	9
Presidential Speaker – Malika Fair, MD, MPH	10
Committee Meeting Descriptions (Open to All)	11
Committee Symposium Descriptions	13
Anatomy Career Connections Reception	17
Annual Business meeting Agenda.....	18
Annual Business meeting Minutes – Virtual	19
Officers of the AACA Council	22
Clinical Anatomy – the Official Journal of AACA.....	23
Committee Reports.....	24
Anatomical Services Committee	
Ad hoc Diversity Inclusion and Equity Committee	
Bylaws Committee	
Brand Promotion and Outreach Committee	
Career Development Committee	
Clinical Anatomical Terminology Committee	
Educational Affairs Committee	
Journal Committee	
Listserv Report	
Membership Committee	
Meeting Organization and Program Planning Committee	
Nominating Committee	
Abstract Listing by Author	
Platform Presentations.....	34
Poster Presentations	41
Tech Fair Presentations	71



FOLLOW US ON
INSTAGRAM



 @aacanatomy



PRIMAL PICTURES
POWERING ANATOMY.TV 




Partnering to deliver next generation anatomy solutions

The world's first and most trusted, medically accurate & flexible 3D digital anatomy and physiology tools

Visit primalpictures.com or email info@primalpictures.com to learn about Primal's market-leading interactive models, videos & learning resources

Ethically-Sourced, Plastinated Specimens from von Hagens Plastination.

- ✓ Silicone Plastinates
- ✓ Sheet Plastinates
- ✓ Anatomy Glass
- ✓ Blood Vessel Configuration
- ✓ Skeletons & Skulls
- ✓ Bespoke Specimen Dissection



 **Anatomic Excellence**

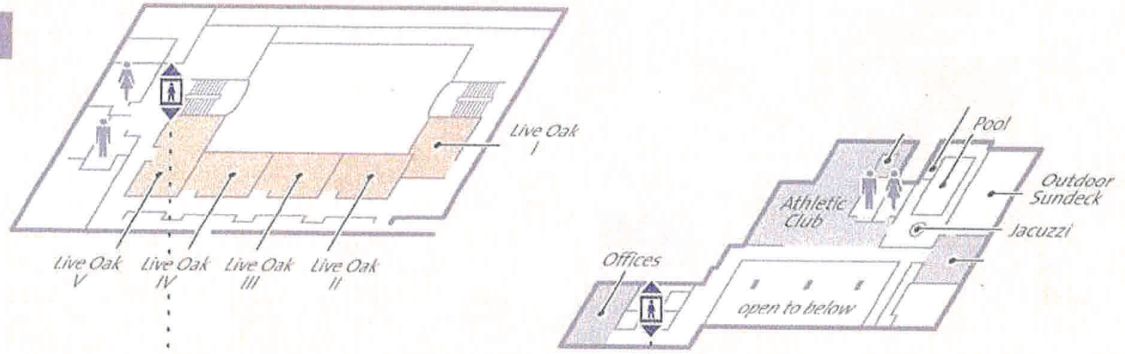

von Hagens
Plastination
REAL ANATOMY FOR TEACHING

www.anatomicexcellence.com

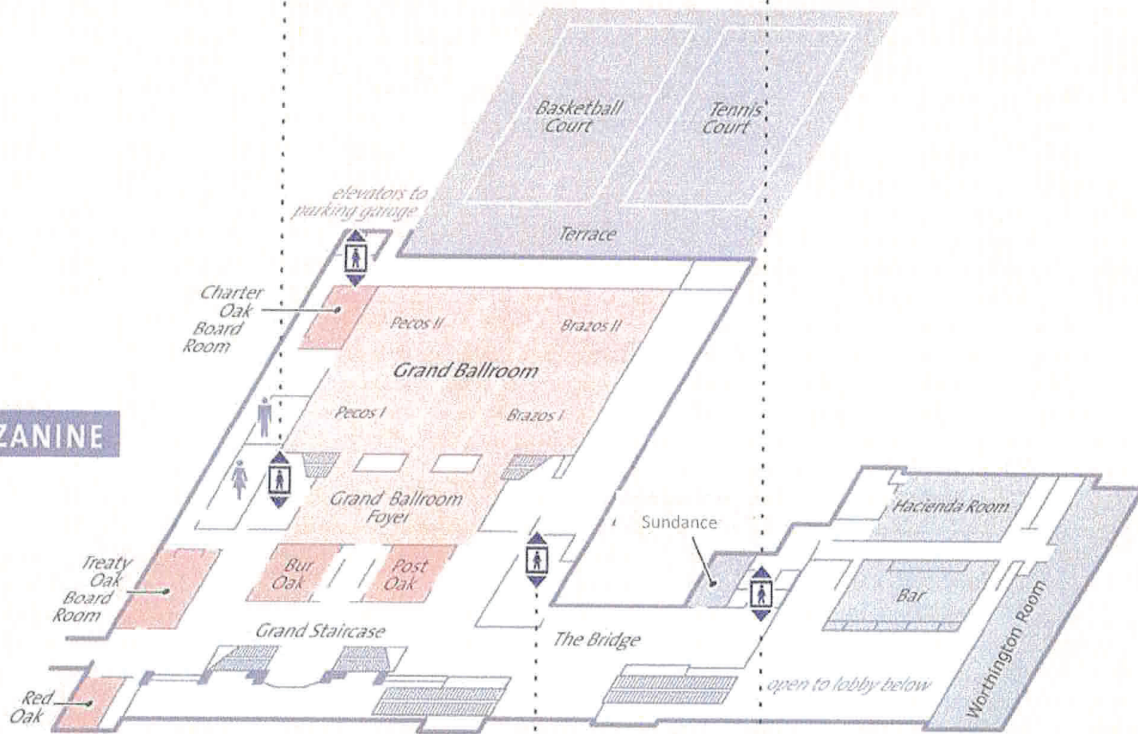
Visit us at Booth #10

Map of Meeting Space

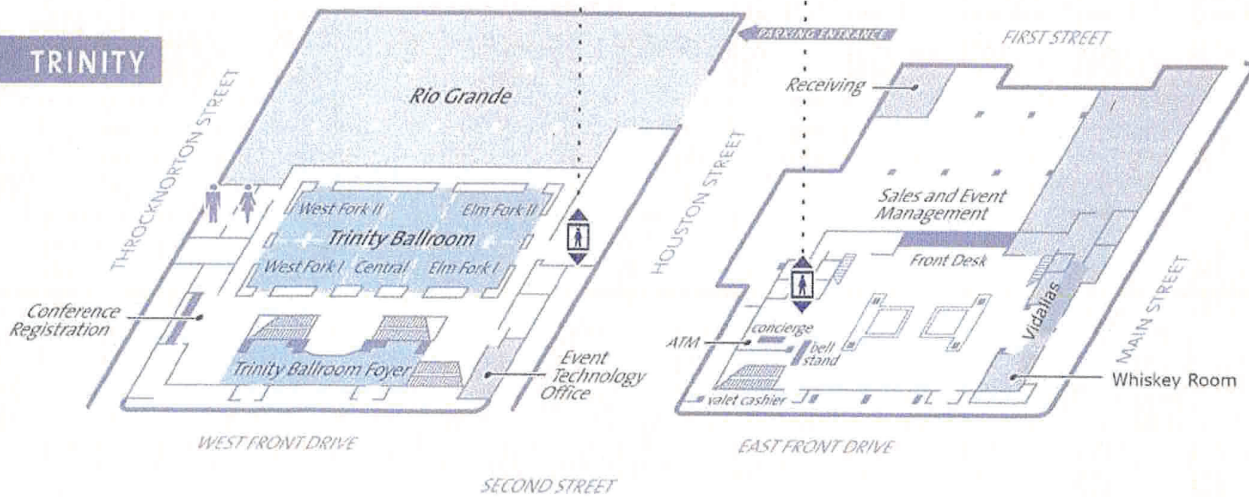
LIVE OAK



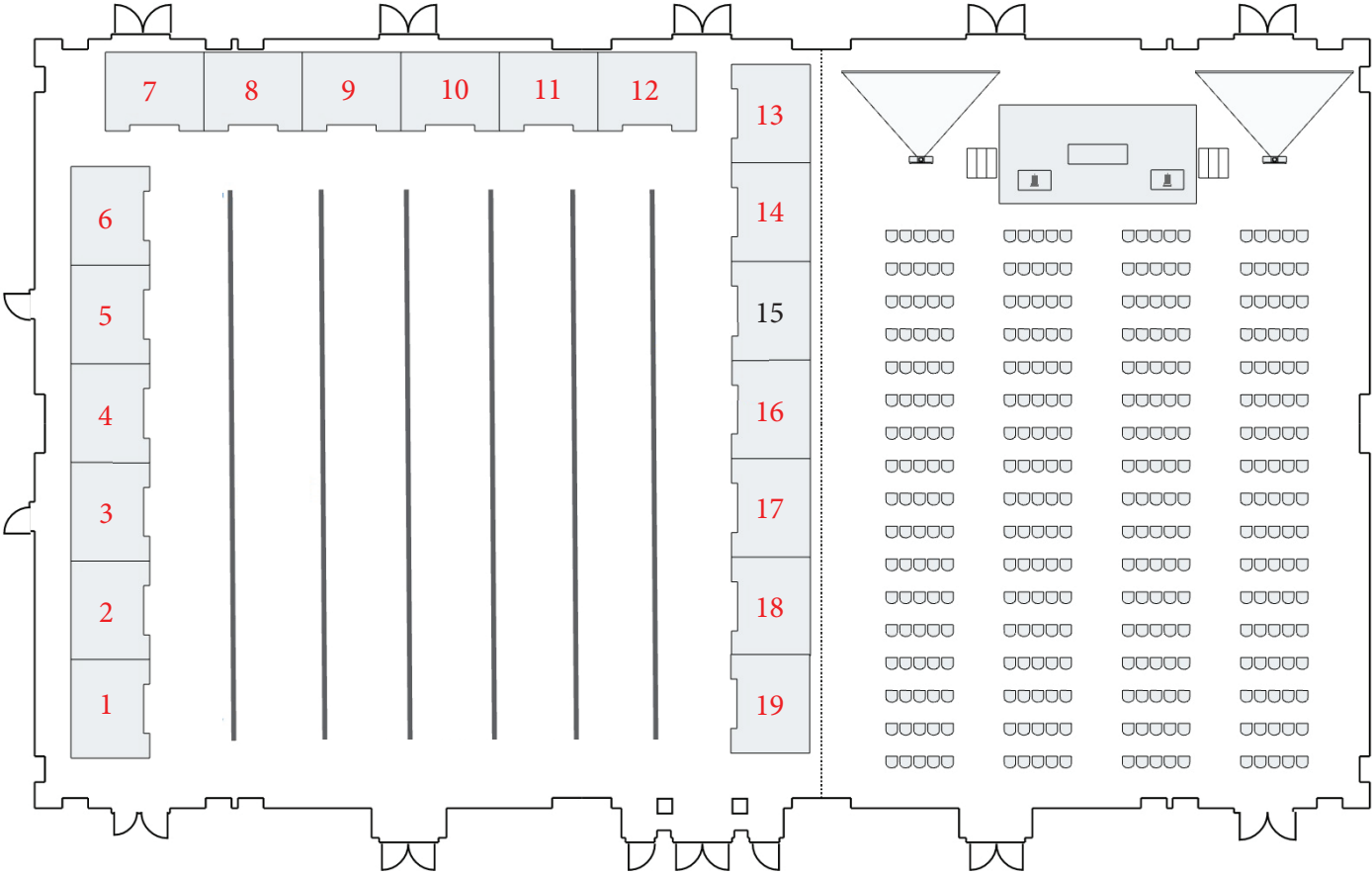
MEZZANINE



TRINITY



Numbered Exhibit Diagram



Booth 1: Wolters Kluwer
 Booth 2: 3D Organon
 Booth 3: Primal Pictures
 Booth 4: Fascia Research Society
 Booth 5: Mopec
 Booth 6: Mopec
 Booth 7: Visible Body
 Booth 8: Dodge
 Booth 9: 4D Anatomy
 Booth 10: Anatomic Excellence/
 von Hagens Plastination

Booth 11: Touch of Life Technologies
 Booth 12: Touch of Life Technologies
 Booth 13: Mortech Manufacturing
 Booth 14: Go Green Solutions Group
 Booth 16: Global AnatomyX
 Booth 17: Elsevier
 Booth 18: Elsevier
 Booth 19: Elsevier

Sponsors/Commercial Exhibitors

Generous donations and/or commercial exhibitor fees paid by the following companies and organizations have substantially reduced the Association's expenses in presenting this meeting.

You are encouraged to visit the exhibits available for viewing in Pecos & Corridor.

Exhibit hours:

11:00 am - 5:00 pm Monday (set up)

7:30 am – 12:00 pm and 1:00 pm – 5:00 pm Tuesday

7:30 am – 12:00 pm and 1:00 pm – 5:00 pm Wednesday

7:30 am – 11:00 am Thursday

TEAR DOWN is from 11:00 am – 4:00 pm on Friday (all exhibitors must be vacated from the hall at 4:00 pm)

The hall will be closed for lunch for one hour each day (12:00 – 1:00 PM).

LIST OF EXHIBITORS *as of 5.5.2022*

3D Organon | Medis Media Pty Ltd

Booth #2

Unit 11, Township Drive
Burleigh Heads, Queensland 04220
Australia
www.3dorganon.com

3D Organon's multi-award-winning software platform facilitates accelerated learning and teaching in medical sciences and anatomy across desktop, mobile, and virtual reality devices. The new 2022 edition of 3D Organon includes over 12,000 anatomical structures across 15 body systems, showcasing new features such as imaging, ultrasound simulation (for pc-powered VR), histology slides, pathology images, embryology images, refactored body actions, new microscopic models and new environments among others and it is available in 16 languages.

4D Interactive Anatomy

Booth #9

Terez korut 38., 2. em., 223.
Budapest
Hungary
www.4danatomy.com

4D Interactive Anatomy brings you real specimens that you can dissect online, anywhere, anytime.

Anatomic Excellence, LLC | von Hagens Plastination

Booth #10

22 Angel Oaks Dr
Savannah, GA 31410
USA
www.anatomicexcellence.com

Anatomic Excellence, LLC is the exclusive, full range agent for Dr. Gunther von Hagens Plastinated Human Tissue Specimens in the USA, Canada & Caribbean. We are committed to working with our customers to help them to establish a collection of ethically prepared specimens that meets both the anatomical needs of your program and enhances learning opportunities for your students.

Dodge

Booth #8

9 Progress Road
Billerica, MA 01821
USA
www.dodgeco.com

Embalming chemicals, instruments, and urns

Elsevier

Booth #17, #18, and #19

1600 John F Kennedy Blvd. Suite 1600
Philadelphia, PA 19103
USA
<https://www.elsevier.com/education/welcome-3d4medical>

For more than 135 years, Elsevier has specialized in health science content across the entire curriculum, ensuring students, faculty, and institutions have access to reliable and relevant information. As the premier health science information provider, Elsevier attracts the leading authors and editors in their fields. Our content is shaped for diverse teaching and learning purposes, providing students and educators with a wide range of options for achieving successful outcomes.

Fascia Research Society

Booth #4

16192 Coastal Hwy
Lewes, DE 19958
USA
<https://fasciaresearchsociety.org/>

Dessemination of fascia related science.

continued on next page

**Global AnatomicX
Booth #16**

8850 NW 20th Street
Miami, FL 33172
USA

www.globalanatomix.org

Global AnatomicX - Anatomy Brought to Life
Highest quality anatomical specimens, for education and research.

Preservation process to increase human cadaveric: Visualization and Longevity.

**Green Solutions Group
Booth #14**

2085 Gold Knob Road
Salisbury, NC 28416
USA

www.gogreensolutionsgroup.com

Non-toxic embalming solution and tissue fixative.

**Mopec
Booth #5 and #6**

800 Tech Row
Madison Heights, MI 48071
USA

www.mopec.com

Mopec provides American-made equipment and supplies to anatomy laboratories, pathology labs, animal research facilities and medical examiner facilities. Founded in 1992, Mopec solutions are among the very best as demonstrated by the vast number of installations in America's top healthcare institutions and universities. Our reputation is built on decades of superior customer service specializing in consultation and customization. Mopec is committed to designing and manufacturing ergonomic equipment to enhance your lab's safety, flexibility and productivity.

**Mortech Manufacturing
Booth #13**

411 North Aerojet Avenue
Azusa, CA 91702
USA

<https://mortechmfg.com/>

Mortech Manufacturing is a comprehensive one-stop-shop, providing quality postmortem equipment, supplies and mortuary walk-in coolers to laboratory facilities around the world. Through top-notch manufacturing and state-of-the-art equipment, Mortech will provide any facility with the professional quality service you need and expect. ISO 9001:2015 certified | NSF certification | Leed Green | UL | CE standards | MADE IN THE USA

**Primal Pictures
Booth #3**

1st Floor Tennyson House - 159-163
Great Portland St
London, W1W5PA
United Kingdom
www.primalpictures.com

Powering Anatomy.tv, Primal Pictures is the only complete and medically accurate digital human 3D model based on real body scans and imaging data. For more than 30 years, Primal's pioneering and award-winning software has been used by millions of educators, students, and practitioners in over 1,500 institutions across more than 150 countries. Primal's best-in-class products engage and inspire, answering the need for better understanding of human anatomy to promote and advance health science and medicine.

**Touch of Life Technologies
Booth #11 and #12**

12635 E. Montview Blvd., Suite 350
Aurora, CO 80045
USA

www.toltech.net

Touch of Life Technologies (Toltech) is a full solutions provider for anatomical hardware and software. Through a broad range of solutions, Toltech enables users to expand the learning experience in and out of the lab or classroom. Decades of research and development have culminated in the VH Dissector platform which enables students and educators around the world to interact with real human anatomy on a variety of devices from collaborative multi-touch tables to iPads and AR and VR devices.

**Visible Body
Booth #7**

493 Old Connecticut Path, Ste 501
Farmington, MA 01701
USA

www.visiblebody.com

3D Anatomy and Physiology Programs

**Wolters Kluwer
Booth #1**

2001 Marker Street
Philadelphia, PA 19103
USA

www.lww.com

Wolters Kluwer Health is a leading global provider of information and point of care solutions for the healthcare industry. Our solutions are designed to help professionals build clinical competency and improve practice so they can make important decisions on patient care. Our leading product brands include Audio-Digest, Lippincott, Ovid®, UpToDate®, and others.

2022 Annual Meeting Sponsors

Gold Level Sponsor

**PRIMAL
PICTURES**
POWERING **ANATOMY.TV**



Silver Level Sponsor



Silver Level Sponsor



Ruby Level Member Sponsorship



Lawrence Wineski, Ph.D.

Interested in becoming a member sponsor donor? Visit the AACA website for more details.

PROGRAM

Monday, June 13th

TIME	LOCATION	ACTIVITY DESCRIPTION	ADDITIONAL INFORMATION
7:00AM – 2:30PM	Bur Oak Room	AACA Council Meeting	Invitation Only Meeting
12:00PM – 5:00PM	Grand Ballroom Foyer	Conference Registration	
2:45PM – 5:30PM	Various Locations	Tour of The University of North Texas Health Science at Fort Worth (UNTHSC)	All those that indicated attendance on the registration form are welcome to attend.
2:45PM – 3:00PM	The Worthington Renaissance Hotel	Loading Bus(es)	
3:00PM – 3:20PM	Various Locations	Bus(es) leave The Worthington Renaissance Hotel and Travel to the Anatomy Laboratories at UNTHSC at Fort Worth	
3:20PM – 3:25PM	UNTHSC at Fort Worth	Unload Buses at UNTHSC at Fort Worth	
3:25PM – 4:00PM	Anatomy Laboratories at UNTHSC at Fort Worth in RES Building	Tour of the Anatomy Laboratories	
4:00PM – 4:05PM	Various Locations	Walk to UNTHSC at Fort Worth Atrium of IREB Building	
4:05PM – 4:50PM	Atrium of IREB Building UNTHSC at Fort Worth	Social with Snacks	
4:50PM – 5:00PM	UNTHSC at Fort Worth IREB Building	Loading Bus(es)	
5:00PM – 5:30PM	Various Locations	Bus(es) leave UNTHSC at Fort Worth and Travel to The Worthington Renaissance Hotel	
5:30PM – 6:30PM	Post Oak Room	Judges' Orientation Meeting	Invitation Only Meeting
6:30PM – 7:30PM	Terrace	Anatomy Career Connections – Hosted by the CDC	All Are Welcome
7:30PM – 9:00PM	Terrace	Opening Reception	All Are Welcome

Tuesday, June 14th

TIME	LOCATION	ACTIVITY DESCRIPTION	ADDITIONAL INFORMATION
7:30AM – 5:00PM	Grand Ballroom Foyer	Conference Registration	
7:30AM – 9:00AM	West Fork/Trinity Central	Education Affairs Committee (EAC) Meeting with Breakfast	All Are Welcome
7:30AM – 9:00AM	Pecos & Corridor	Continental Breakfast with Exhibitors	All Are Welcome
7:30AM – 5:30PM	Grand Ballroom Foyer	Silent Auction Open	All Are Welcome
9:15AM – 9:30AM	Brazos 1 & 2	Welcome by AACA President, Dr. Thomas Gest Welcome from University of North Texas Health Science Center at Fort Worth, Dr. Jonathan Tune	All Are Welcome
9:30AM – 10:30AM	Brazos 1 & 2	Presidential Speaker Malika Fair, MD, MPH	All Are Welcome
10:30AM – 11:00AM	Pecos & Corridor	Coffee Break with Exhibitors	All Are Welcome
11:00AM – 12:00PM	Brazos 1 & 2	Platform Presentations Session 1 – Upper Limb	All Are Welcome
12:00PM – 1:00PM	Worthington	<i>Clinical Anatomy</i> Editorial Meeting	Invitation Only Meeting
12:00PM – 1:30PM	West Fork/Trinity Central	Brand Promotion and Outreach Committee (BPOC) Meeting with Lunch	All Are Welcome. Separate, pre-purchase of lunch required.
1:30PM – 2:45PM	Brazos 1 & 2	Anatomical Services Committee (ASC) Symposium	All Are Welcome
3:00PM – 4:00PM	Pecos & Corridor	Poster Session 1 with Exhibitors and Coffee	All Are Welcome
4:15PM – 5:45PM	Brazos 1 & 2	Platform Presentations Session 2 - Education	All Are Welcome

Wednesday, June 15th

TIME	LOCATION	ACTIVITY DESCRIPTION	ADDITIONAL INFORMATION
7:30AM – 5:00PM	Grand Ballroom Foyer	Conference Registration	
7:30AM – 9:00AM	West Fork/Trinity Central	Clinical Anatomical Terminology (CAT) Committee Meeting with Breakfast	All Are Welcome
7:30AM – 9:00AM	Pecos & Corridor	Continental Breakfast with Exhibitors	All Are Welcome
7:30AM – 5:30PM	Grand Ballroom Foyer	Silent Auction Open	All Are Welcome
9:15AM – 10:30AM	Brazos 1 & 2	Platform Presentations Session 3 – Thorax and Head & Neck	All Are Welcome
10:30AM – 11:30AM	Brazos 1 & 2	Poster Session 2 with Exhibitors and Coffee	All Are Welcome
11:45AM – 1:15PM	West Fork/Trinity Central	Career Development Committee (CDC) Meeting with Lunch	All Are Welcome. Separate, pre-purchase of lunch required.
1:30PM – 2:45PM	Brazos 1 & 2	Tech Fair Presentations	All Are Welcome
3:00PM – 4:00PM	Pecos & Corridor	Poster Session 3 with Exhibitors and Coffee	All Are Welcome
4:15PM – 5:00PM	Brazos 1 & 2	Platform Presentations Session 4 – Pelvis and Lower Limb	All Are Welcome
6:00PM – 8:00PM	Brazos 1 & 2	Anatomy Trivia with Snacks and Beverages	All those that registered for the Anatomy Trivia Event and paid the separate fee.

Thursday, June 16th

TIME	LOCATION	ACTIVITY DESCRIPTION	ADDITIONAL INFORMATION
7:30AM – 5:00PM	Grand Ballroom Foyer	Conference Registration	
7:30AM – 9:00AM	West Fork/Trinity Central	Anatomical Services Committee (ASC) Meeting with Breakfast	All Are Welcome
7:30AM – 9:00AM	Pecos & Corridor	Continental Breakfast with Exhibitors	All Are Welcome
9:15AM – 10:30AM	Brazos 1 & 2	Educational Affairs Committee (EAC) Symposium	All Are Welcome
10:30AM	Grand Ballroom Foyer	Silent Auction Closes	All Are Welcome
10:30AM – 11:30AM	Pecos & Corridor	Coffee with Exhibitors	All Are Welcome
11:30AM – 1:00PM	Worthington	Lunch for New Award Committee Decisions	Invitation Only Meeting
1:00PM – 4:30PM	Grand Ballroom Foyer	Pay and Pick Up Items for Silent Auction	All Are Welcome
1:15PM – 2:15PM	Brazos 1 & 2	Diversity, Equity, and Inclusion Committee (DEIC) Meeting	All Are Welcome
2:30PM – 3:30PM	Brazos 1 & 2	AACA Member's Business Meeting	All Are Welcome Only members may vote.
3:45PM – 4:30PM	AACA New Council Meeting	Worthington Room	Invitation Only Meeting
5:00PM – 6:00PM	Reception	Terrace	Included in registration. Guests required to pay an additional fee.
6:00PM – 8:00PM	Dinner with Awards	Brazos & Corridor	Included in registration. Guests required to pay an additional fee.

Friday, June 17th

TIME	LOCATION	ACTIVITY DESCRIPTION	ADDITIONAL INFORMATION
7:15AM – 7:30AM	The Worthington Renaissance Hotel	Loading Bus(es) at the Worthington to travel to UNTHSC at Fort Worth	
7:30AM – 4:00PM	UNTHSC	Post-Graduate Course on Hand Transplantation at UNTHSC at Fort Worth	All those that registered for the Post-Graduate Course and paid the separate fee.
4:00PM – 4:30PM	UNTHSC	Bus(es) leave UNTHSC at Fort Worth and Travel to The Worthington Renaissance Hotel	

Honored Member 2022

The American Association of Clinical Anatomists
Recognizes and Awards Honored Membership to

Cornelius Rosse, MD, DSc



Cornelius Rosse, MD, DSc, is a professor emeritus at the University of Washington. He received his medical education and training at the University of Bristol in England and, after joining the faculty of the Department of Anatomy, he was awarded a PhD degree for his research work in hematopoiesis and a Doctor of Science degree in biomedical informatics. He transferred to the Department of Biological Structure at the University of Washington in 1967, later becoming its chairman. He taught anatomy and embryology in a variety of courses to students and trainees in healthcare programs, ranging from undergraduates to surgical residents at the University of Washington and as a visiting professor at the Royal College of Surgeons (London). After being named “Outstanding Teacher” in five consecutive years in the UW School of Medicine, he was declared “Teacher Superior in Perpetuity” to open up the award to other faculty. Subsequently, he received the Distinguished Teacher Award of the University of Washington and of the American Association of Medical Colleges. He was appointed to the advisory board of the latter institution and served as a member and later as chairman of the Step 1 Test Development Committee of the National Board of Medical Examiners. He is an author of four textbooks and 10 electronic publications related to anatomy as well as of several journal articles concerned with anatomy education.

Over the years, Rosse’s research was supported by grants and contracts from the National Institutes of Health (National Cancer Institute and National Library of Medicine), the Department of Energy and the Department of Defense (Defense Advanced Research Agency or DARPA). Among the close to 200 publications resulting from this support some relate to cell production and differentiation in the immune and hematopoietic systems, while the majority pertain to biomedical informatics, an area in which Rosse has made his salient contributions. The latter entail the establishment of Structural Informatics (in partnership with James Brinkley), a subdiscipline of biomedical informatics, which addresses the challenges posed by the computable representation of the spatial and symbolic components of anatomical science. The spatial component was realized through the Digital Anatomist program, which pioneered the interactive 3D representation of parts of the body and served as the impetus for the National Library of Medicine’s Visible Human and DARPA’s Virtual Soldier projects. The Foundational Model of Anatomy represents the symbolic component of anatomical science as a principled ontology created and readable only through computational methods. It is the result of world-wide collaboration between anatomists, computer and information scientists, ontologists and philosophers. The FMA is distinct from traditional anatomical knowledge sources in that it serves as a reference ontology for application developers in clinical practice and biomedical research.

While his previous publications appeared predominantly in bioinformatics and AI journals, during his retirement Rosse is preparing contributions to Clinical Anatomy to promote the engagement of anatomists in the development of educational applications capable of supporting inference and reasoning.

Previous Honored Member Award Recipients

1984 - W. Henry Hollinshead*
1985 - Chester B. McVay*
1986 - Donald James Gray*
1987 - Russell T. Woodburne*
1988 - Oliver Beahrs*
1989 - N. Alan Green*
1990 - Frank H. Netter*
1991 - Ralph Ger*
1992 - M. Roy Schwarz
1993 - Carmine D. Clemente*

1994 - Keith L. Moore*
1995 - Ray J. Scothorne*
1996 - Robert A Chase
1997 - Tatsuo Sato
1998 - John E. Skandalakis*
1999 - Donald R. Cahill*
2000 - Sandy C. Marks, Jr.*
2001 - David G. Whitlock*
2002 - Robert D. Acland*
2003 - Arthur F. Dalley, II

2004 - John V. Basmajian*
2005 - Ian Whitmore
2006 - Peter H. Abrahams
2007 - Gary Wind
2008 - T.V.N. (Vid) Persaud
2009 - Richard S. Snell
2010 - Raymond F. Gasser
2011 - Harold Ellis
2012 - Ronald A. Bergman
2013 - John Hansen

2014 - Victor M. Spitzer
2015 - Carol E. Scott-Conner
2016 - Carlos Machado
2017 - James D. Collins*
2018 - Anne Agur
2019 - Robert Anderson
2020 - Stephen W. Carmichael
2021 - Susan Standing

* deceased

Presidential Speaker

Malika Fair, MD, MPH



“Critical Steps to Advance Racial Equity in Medicine”

Dr. Fair will describe promising practices for clinicians, scientists, and administrators to eliminate racism in medicine broadly and apply these principles to clinical anatomy. During her talk she will provide helpful strategies for initiating, enhancing, and sustaining efforts to create anti-racist, equitable and inclusive work and learning environments.

Biography:

Malika Fair, MD, MPH is the Senior Director of Equity and Social Accountability at the Association of American Medical Colleges (AAMC). Dr. Fair develops programs and initiatives with multidisciplinary partners and local communities to advance equity, racial justice, population health, and accountability through a continuous equity improvement lens. Within the AAMC Strategic Plan, Dr. Fair leads one of the 10 action plans for the AAMC: Equipping Academic Medicine to be More Inclusive and Equitable. Within this action plan, Dr. Fair oversees the plan to address and eliminate racism within Academic Medicine. Her work assists the academic medicine community in becoming anti-racist leaders who acknowledge and understand systemic racial inequities and cultivate evidence-based policies and practices that promote racial justice and equity in our communities, education and research institutions, and health care systems.

Dr. Fair is also an Associate Clinical Professor in the Department of Emergency Medicine of The George Washington University. She is the Vice Chair of the Advisory Board of the Griffith Leadership Center within the University of Michigan School of Public Health and Department of Health Management and Policy and serves on the Fiscal Control Board of Directors for United Medical Center in Washington, DC. In 2019, Dr. Fair was selected to serve on the Mayor’s Commission on Healthcare Systems Transformation for the District of Columbia and to be included in the 40 Under 40 Leaders in Minority Health by the National Minority Quality Forum. Dr. Fair completed her residency training and chief residency at Carolinas Medical Center in Charlotte, NC. She received her medical and Master of Public Health degrees from the University of Michigan and Bachelor of Science from Stanford University.

Committee Meeting Descriptions

(Open to all – not restricted to members of the committee)

Anatomical Services Committee Breakfast Meeting

Thursday, June 16th from 7:30 – 9:00 AM

Open to All Attendees

The Anatomical Services Committee (ASC) meeting is a great place to learn about what ASC does and how you can get involved. We will be discussing ASC business and electing a new member of the committee. Our business meeting will include bylaws changes this year. If you would like to be a member of ASC, or know someone who would, please come to the meeting and nominate them. As a current member, you can self-nominate!

Our symposium titled, “Modern Preservation Techniques & Maintaining Donor Quality Across Diverse Programming” is a panel discussion welcoming Camryn Hawkins, PhD, and Shawna Rodabaugh, MBA. Learner outcomes in the anatomy laboratory experience require a diverse repertoire of preservation techniques. This panel addresses modern techniques to help expand and optimize the donor for use in anatomy laboratories. Our discussion promises to be very exciting for all levels of our anatomy laboratory experiences.

For our “Lessons Learned” segment this year, Amanda J. Collins, MPH from the University of Massachusetts T.H. Chan School of Medicine will present, “Help me Medical Examiner – You’re Our Only Hope.” A reflection on how to ensure donor identity when the donor medical history is not consistent with dissection findings.

The ASC meeting is a perfect forum to “Ask an Expert”. This meeting is filled with experts on all aspects of body donation, from technical preparations to ethics, and policies to PPE. Your colleagues bring years of experience to the table, making our meeting a great place to find information and network. Following the meeting, we hope that members and attendees can continue networking over breakfast. Committee members can always be reached by email if you have any concerns or questions throughout the year. We are even open to Zooming if you prefer.

Come to the ASC meeting to listen or to be part of the conversation by sharing your experiences. We hope to see you there!

Eileen Kalmar, Academic Co-Chair
Amanda Mittelstadt, Technical Co-Chair

Brand Promotion & Outreach Committee Lunch Meeting

Tuesday, June 14th from 12:00 – 1:30 PM

Open to All Attendees

Join the Brand Promotion and Outreach Committee (BPOC) for our lunch session “Anatomy Outreach that is Within Reach” on June 14th at 12:00-1:30 pm. A panel of AACA members will share their personal experiences running anatomy outreach programs with a variety of audiences. Want to hear about common challenges and different models of delivery? Want to take home some tips for running a successful Anatomy Outreach event for your institute? Don’t miss out on this event and make sure to add the BPOC Lunch to your registration!

Career Development Committee Lunch Meeting

Wednesday, June 15th from 11:45 AM - 1:15 PM

Open to All Attendees

The Career Development Committee (CDC) will host a lunch meeting that engages attendees and CDC committee members in an informal Q & A discussion. This lunch meeting is a perfect forum to ask your colleagues questions about promotion and networking. The CDC not only offers a diverse panel with members in various stages of their career, but AACA members bring years of experience to the table, making our lunch meeting a great place to share information and network. Come to the CDC lunch meeting to listen or take part in the conversation by sharing your experiences.

During the meeting we will be electing a new member to join the CDC. Anyone interested in career development is encouraged to run. The lunch meeting is open to all members.

continued on next page

Ad-Hoc Diversity, Equity, and Inclusion Committee (DEIComm) Meeting

Thursday, June 16th from 1:15 – 2:15 PM

Open to All Attendees

The ad hoc Diversity, Equity and Inclusion Committee meeting is a chance to learn about the committee and how you can get involved. We will be reporting on our achievements and outlining our future plans, including transitioning to full committee status. After this, the meeting will focus on the skills involved in being a good advocate:

- Defining – What is advocacy and where does it occur, for yourself, students, course, institution, and beyond?
- What attributes make a successful advocate? Lessons from our committee members.
- How can we communicate with individuals who share different opinions from our own?

Educational Affairs Committee Breakfast Meeting

Tuesday, June 14th from 7:30 – 9:00 AM

Open to All Attendees

The topic for the 2022 EAC Breakfast meeting is “Let’s Talk About the Scary Stuff: Purposeful Inclusion of Diversity into Anatomy Curricula”

Topics concerning diversity and inclusion are currently being taught in anatomy curricula, purposefully or unconsciously. Deliberate teaching of diversity exposes students to various cultural and social groups, preparing them to become better citizens and clinicians. In the EAC breakfast meeting, participants will discuss ways in which they are intentionally including diversity in their anatomy curriculum and areas in which they may need more support.

At the end of the session participants will achieve the following objectives:

1. Articulate the importance of implementing diversity and inclusion topics in anatomy curricula.
2. Identify examples of diversity topics that can be incorporated into anatomy curricula.
3. Network with other educators currently integrating purposeful diversity ideas.

Clinical Anatomical Terminology Committee Breakfast Meeting

Wednesday, June 15th from 7:30 - 9:00 am

Open to All Attendees

The breakfast meeting of the Clinical Anatomical Terminology Committee (CAT) will provide an overview of the activities of the CAT and its subcommittees, an opportunity to hear from its members and to join to them (via election), and an entertaining and informative anatomical terminology quiz. Members of the top scoring team (up to 4) will each win an enhanced eBook version of the 42nd edition of Gray's Anatomy, courtesy of Elsevier (<https://www.uk.elsevierhealth.com/grays-anatomy-9780702077050.html>). So come and join us and test your grasp of our anatomical language! The agenda for the breakfast meeting is as follows:

- Introduction to the AACA CAT Committee (5 minutes)
- Overview of CAT Subcommittee Activities (15 minutes)
- Elevator Pitches from Nominees and Elections (20 minutes)
- Terminology Quiz via Cahoot, with prizes for the winning team (45 minutes)
- Announcement of election results and welcoming new members (10 minutes)

Committee Symposium Descriptions

Anatomical Services Committee Symposium

Tuesday, June 14th from 1:30 – 2:45 PM

Open to All Attendees

"Modern Preservation Techniques & Maintaining Donor Quality Within the Anatomy Laboratory"

Our symposium titled, "Modern Preservation Techniques & Maintaining Donor Quality Across Diverse Programing" is a panel discussion welcoming Camryn Hawkins, PhD, and Shawna Rodabaugh, MBA. Learner outcomes in the anatomy laboratory experience require a diverse repertoire of preservation techniques. This panel addresses modern techniques to help expand and optimize the donor for use in anatomy laboratories. Our discussion promises to be very exciting for all levels of anatomy laboratory experiences.

Shawna R. Rodabaugh

Director of Curriculum for Pierce Mortuary Colleges

Biography: Shawna Rodabaugh has been a licensed mortician for 20 years. In that time, she has served as a funeral director and embalmer for several funeral homes, manager of a chain of funeral homes in Michigan, investigator for the Montcalm County Office of the Medical Examiner, anatomy instructor at Ferris State University, Director of Anatomy for Central Michigan University's College of Medicine, self-employed service embalmer, and Program Coordinator of Anatomy and Embalming for Fayetteville Technical Community College's Funeral Service Education program. She is formerly licensed in Michigan and Florida, and currently licensed in North Carolina.

Shawna earned her associate degree in applied science, bachelor degree in mortuary science, bachelor degree in technical management, master of business administration with a minor in project management, and is completing her PhD dissertation for a degree in higher education policy and law.

Shawna owns a consulting business, Rodabaugh Mortuary Education and Consulting, where she has worked with several entities to provide continuing education in embalming, and teaches an anatomical preservation and dissection course for continuing education at Fayetteville Technical Community College. She works closely with the American Board of Funeral Service Education, serving on the curriculum review committee for microbiology and embalming, is currently serving on the overall curriculum committee in charge of implementing national curriculum standards, and has worked with the International Conference of Funeral Service Examining Board to help create the new National Board Exam for licensure in funeral service.

Shawna has several publications, including contributions to the Michigan Funeral Director's Association Journal, Clinical Correlate Cases (cardiopulmonary) for the CMU College of Medicine, contributing author to the textbook "Embalming, History, Theory and Practice", sole author of Embalming Laboratory Manual, Kendall Hunt Publications, and is currently in the process of writing "Anatomical Preservation and Ethical Use of Donors", Tuesday Evening Publications, "Anatomical Preservation and Dissection Manual", Kendall Hunt Publications, and "Guidebook, North Carolina Apprentice Training Manual", Kendall Hunt Publications.



continued on next page

Shawna's research includes the development of application protocol for non-toxic anatomical preservation solution, the development the only instructional program in the US to teach Surgical Reality embalming methods, utilizing ammonium nitrate, the development of standardized protocol for formaldehyde/phenol based anatomical preservation, and currently beginning testing on COVID positive anatomical donors, to determine if ethanol-based preservative solutions will disarm the virus.

She has appeared as a guest on several podcasts, including "Dead Girls Talking", "Undertaking, the Podcast", "The Open Casket Podcast", "Teaching in Higher Ed" and has presented to the League for Innovation on "New Approaches to Online Teaching", AACA on "Methods of Anatomical Preservation and Ideal Applications for Each Methodology", and North Carolina Commission of Anatomy "Green Embalming in Anatomical Settings". She is currently under consideration for a position on the North Carolina Board of Funeral Service.

Camryn Hawkins, PhD - Cleveland Clinic

Biography: Camryn Hawkins, PhD, is currently the Director of Histology at the Cleveland Clinic and an Assistant Professor of Surgery at the Cleveland Clinic Lerner College of Medicine of Case Western Reserve University. She completed her PhD in Anatomy from the Ohio State University in Columbus, OH. Before beginning her graduate work in 2015, Dr. Hawkins worked as a licensed funeral director and embalmer for a family-owned funeral home in the Columbus area. As a graduate student, she served as a graduate teaching assistant within the Division of Anatomy at the Ohio State University. She had the opportunity to work with numerous student populations including: undergraduate, graduate, medical and dental students. She was the recipient of two Candle Apple Humanism in Medicine awards, the Margaret Hines Scholarship, and a student travel award from the Human Anatomy and Physiology Society national conference. Her dissertation research focused on the utilization of different embalming solutions in an undergraduate curriculum and how they impacted student performance on laboratory practical examinations.



She completed her PhD in 2021 and was recruited by the Cleveland Clinic Lerner College of Medicine at Case Western Reserve University. Dr. Hawkins works with first- and second-year medical students teaching both histology and anatomy, and the physician assistant students at Mount Union University. At the Cleveland Clinic, Dr. Hawkins currently serves as the Histology Thread Leader, a member of the Basic Sciences Committee, an interview for the Admissions Committee, and as Co-Director of the Body Donor Program.

Committee Symposium Descriptions Continued

Educational Affairs Committee Symposium
Thursday, June 16th from 9:15 - 10:30 AM
Open to All Attendees


"Continuing Integration Of Anatomy For Clinical Application And Practice"

While clinical sciences have generally been integrated into the anatomy preclinical curriculum; integration of anatomy into the clinical curriculum has been a challenge. In the EAC symposium, participants will be introduced to the best practices for continuing integration of anatomy pertaining to course structure, curriculum development, and program evaluation. Participants will hear these perspectives from a diverse array of speakers spanning from clerkship directors, anatomy educators, and practicing allied health professionals. At the end of the session participants will achieve the following objectives:

1. Reflect upon the challenges inherent in delivering anatomy longitudinally to future clinicians.
2. Gain insight on various methods by which anatomy can be integrated into the clinical curriculum.
3. Consider the various processes used to determine important anatomic concepts relevant to clinical application and practice.
4. Discuss possible ways in which evaluation of integration could occur.

Marsha Rutland, PT, Sc.D., MEd, OCS, COMT, CSCS, C-DN
Professor of Physical Therapy, Hardin-Simmons University

MARSHA RUTLAND, PT, Sc.D., MEd, OCS, COMT, CSCS, C-DN is a professor of Physical Therapy at Hardin-Simmons University DPT program. She received her BS in Physical Therapy (University of Texas Health Science Center- Dallas ,1979), Master of Education (Hardin-Simmons University, 2002) and an Sc.D. in Physical Therapy (Texas Tech University,2008). She is certified as an APTA Orthopedic Clinical Specialist (OCS) (2003, 2013) and has her certification as an IAOM orthopedic manual therapist (COMT)(2007). Additionally, she is a Certified Strength and Conditioning Specialist (2003) and a IAOM Certified Dry Needler (C-DN). Dr. Rutland has 42 years of clinical experience in a variety of settings, with mainly outpatient orthopedics x last 20+ years. She was a Clinical Instructor for 20 years and was recognized in 2002 by the Texas Consortium for Physical Therapy Clinical Education, Inc. as an outstanding Clinical Instructor. Her teaching responsibilities include Clinical Anatomy I and II, Diagnostic Imaging, and Healthcare Management. Dr Rutland received the William R. Gould Memorial Outstanding Physical Therapy Faculty Member Award from the Texas Physical Therapy Association (2011), Award for HSU Teaching Excellence (2014) and received the HSU Faculty Member of the Year award in 2021. Dr. Rutland's research interests' center around anatomy, orthopedic assessment, hypermobility, and treatment issues.



continued on next page

Mary Orczykowski, PhD
Lecturer IV, University of Michigan Medical School

Mary Orczykowski is a faculty member in the Division of Anatomical Sciences at the University of Michigan Medical School where she contributes to teaching in undergraduate, dental, and medical curricula. She serves as the director of Anatomy 510 (undergraduate laboratory teaching experience) and co-director of M2 Anatomy with Dr. David Brzezinski. Together with Dr. Brzezinski, she has worked to integrate review of M1 foundational anatomy and introduction to foundational head and neck anatomy in a one-week anatomy intensive that is part of the M2 Surgery Clerkship. Additionally, Mary teaches in M4 Residency Preparation Courses for students applying into OBGYN and Orthopedic Surgery.



William Rennie, MD
Hofstra University

William Rennie, MD is an emergency physician and a clinical anatomist, combining these disciplines in the practice of medical education. He is a graduate of the Oregon Health and Sciences University School of Medicine with training and certification in primary care, clinical anatomy, and emergency medicine. In 2009, Dr. Rennie was among the first handful of educators recruited by the Dean of the Hofstra Northwell School of Medicine and was instrumental in the development of multiple aspects of the school's innovative curriculum. Since the School of Medicine's opening in 2011, he has served as co-director of "From the Person to the Professional: Challenges, Privileges and Responsibilities" (CPR) which includes certification of medical students as Emergency Medical Technicians, providing them with opportunities for authentic patient care experiences beginning in the first two months of medical school. Dr. Rennie also has served as the primary developer and co-director of "Structure", a course which combines and integrates the structural sciences of Anatomy, Embryology, Histology, Pathology and Medical Imaging into a single learning experience, continuing throughout the first two years of medical school. Additionally, Dr. Rennie helped design, implement and co-directs the four-year curriculum in bedside ultrasonography as well as the GALEN program which brings basic structural science to each of the clerkships in the third year. He continues to teach physical diagnosis, is active in the development and assessment of medical simulation exercises and has championed the discipline of Clinical Reasoning and its deliberate practice in multiple venues. Dr. Rennie has been a regular contributor to national and international organizations and journals representing Emergency Medicine, Ultrasound, Anatomical Sciences, and Medical Education. He is a charter member of the Academy of Medical Educators and has been awarded for teaching excellence on multiple occasions.



Anatomy Career Connections - Hosted by the CDC

Anatomy Career Connections Reception **Monday, June 13th from 6:30 – 7:30 PM** **Open to All Attendees**

The Career Development Committee (CDC) will host a welcoming reception “Anatomy Career Connections Reception” on the first day of the meeting for any members, regardless of the stage of their career, to foster connections among junior and senior anatomists. The reception is primarily directed at individuals looking to foster connections in the anatomy teaching and research communities. The format of the reception will consist of several seasoned anatomy ‘hosts’ who will engage in conversation with a group of 8-10 attendees. Additionally, the hosts will facilitate introductions among attendees throughout the conference to foster connections between anatomists with similar backgrounds and needs.



Annual Business Meeting

Agenda

Thursday, June 16th, 2022

Fort Worth, Texas

PO Box 2945
LaGrange, Ga 30241
Ph: 706-298-0287

www.clinical-anatomy.org


CALL TO ORDER: 2:30 pm

Approval of Minutes of 2021 Annual Business Meeting (ABM) and the 2022 ABM Agenda

1. **President's Report** – *Thomas Gest* – 10 minutes
 - a. 2022 Election Results
 - b. 2023 Election – Positions open to the AACA Membership in 2023
 - a. President-elect (1)
 - b. Secretary (1)
 - c. Special councilor – Allied Health (1)
 - d. Councilors-at-large (2)
 - c. Presidential Committee Appointments
 - d. State of the Association
2. **Treasurer's Report** – *Anthony D'Antoni* – 5 minutes
3. **Membership Committee Report** – *R. Shane Tubbs* – 5 minutes
 - a. Remembrance of Deceased Members – *Sarah Greene* – 1 minute
4. **Journal Committee Report** – *Marios Loukas* – 2 minutes
 - a. Report on *Clinical Anatomy* – *Marios Loukas* – 7 minutes
5. **Meeting Organization & Program Planning Committee Report** – *Jennifer Burgoon* – 10 minutes
 - a. Report of 2022 Annual Meeting Committee
 - b. Future Meetings:
 - i. 2023 AACA Annual Meeting, Orlando, FL
 - ii. 2024 AACA Annual Meeting, New York, NY – Estomih Mtui
 - iii. 2025 AACA Annual Meeting, Seattle, WA – Shane Tubbs & Joe Iwanaga
6. **Committee Elections¹** – *Thomas Gest* – 15 minutes
 - a. Election of Members-at-Large for Nominating:3 vacancies
 - b. Bylaws Committee:2 vacancies
 - c. Financial Affairs Committee:1 vacancy
7. **Annual AACA Awards** – *Thomas Gest* -5 minutes
 - a. Honored Member Award 2022 – Cornelius Rosse, MD, DSc
8. **Old Business** – 2 minutes
9. **New Business** – 3 minutes

ADJOURNMENT: 3:30pm

¹ The Special Interest Group (SIG) Committees (Brand Promotion and Outreach, Educational Affairs, Career Development, Clinical Anatomical Terminology, and Anatomical Services) elects' members at their committee meetings.



Annual Business Meeting Minutes

Thursday, July 1st, 2021
Virtual Zoom Meeting

PO Box 2945
LaGrange, Ga 30241
Ph: 706-298-0287

www.clinical-anatomy.org

CALL TO ORDER:

1. Approval of Minutes/Agenda

3:01 pm

3:01pm

- a. 2020 Annual Business Meeting (ABM) minutes
 - i. Jennifer Burgoon moved to approve, Craig Goodmurphy second
 - ii. Voted – approved
- b. 2021 ABM Agenda
 - i. Shane Tubbs moved to approve, Tom Gest Second
 - ii. Voted – approved

2. President's Report (Robert Spinner)

3:02pm

- a. Thanks to outgoing Council Members
- b. Reviewed 2021 Election Results
- c. Presidential Committee Appointments
 - i. Reviewed Elected and Presidential Appointees
- d. State of the Association
 - i. We have a strong, engaged membership, successful accounts, and Journal impact factor over 2.0. With the challenges of COVID, many major changes needed to occur, which impacted activities of the association. These decisions were made to keep members and the society safe. We worked together and adapted and transformed with enthusiasm and collectively to reorganize and think innovatively.
 - ii. Our virtual meetings had a record number of attendees, with a combination of live and prerecorded symposia, networking and social events, exhibitors, and our banquet.
 - iii. One goal was to highlight the clinical in clinical anatomy to benefit patients and learners. The keynote speaker, as well as other presentations, helped to support this goal.
 - iv. Another goal was to strengthen relationships with other societies. We have successfully created relationships with HAPS, BACA, IFAA, and the Macedonian Society.
 - v. Many skills that we have learned across the year will be applied in the future. We have learned to work in a virtual environment while maintaining creativity and working together. Future regional meetings may remain virtual.
 - vi. Council, the Executive Committee, MOPP, Committees and our ad-hoc DEI Committee, and ASG have made this all possible.
 - vii. A potential hybrid model of meetings will need to be considered in the future, as we plan for our 2022 and 2023 meetings.

3. Treasurer's Report (Anthony D'Antoni)

3:14pm

- a. Summary of accounts
- b. One goal was to oversee growth over \$1 million, which was accomplished last year. Losses in 2020 related to decision to not charge for meeting.
- c. This year virtual meeting has projected gain of \$10,000.
- d. From 2015-2020, on average, we have gained a little over \$2000 for regional meetings.
- e. We may turn regional meetings from in person to virtual.
- f. Data for membership dues for 2021 is underestimate, as year is not over.
- g. Journal budget, profit margin from 2020-2021 is considerable.
- h. Virtual Council meetings has benefitted us financially.
- i. Virtual meetings and web revenue also have the potential for financial benefit. Please reach out with ideas for web revenue.
- j. Given uncertainty of pandemic, the association did quite well.

continued on next page

- 4. Membership Committee Report (Thomas Gest) 3:19pm**
- a. Reviewed membership types and numbers
 - b. Discussed the possibility of expanding affiliate membership
 - c. Membership-wise, our numbers are looking good, as we will likely have more memberships in the last 6 months of the year. Please encourage colleagues to join.
- 5. Remembrance of Deceased Members (Sarah Greene) 3:23pm**
- 6. Journal Committee Report (Marios Loukas) 3:24pm**
- a. Submissions this year were highest in the history of the journal. Huge increase in the number of downloads of articles. These are from a range of topics from educational to clinical, with some relating to COVID, integration of clinical anatomy, and image viewing. The primary source of finding articles is now a Google search.
 - b. Our current impact factor is 2.414, which is up 22% from last year.
- 7. Report of Editor-in-Chief of Clinical Anatomy (R. Shane Tubbs) 3:27pm**
- a. We had the largest number of submissions in the history of the journal this year, with well over 700 submissions.
 - b. Most submissions have come from the US, along with Turkey, China, India, and the UK, demonstrating this is an international journal. There has also been a large increase in the number of downloads of articles, which have been mostly from the US, UK, Australia, Canada, and other European countries.
 - c. Reviewed some of the most downloaded articles.
 - d. We have a 10-year contract with Wiley and are about 5 years into this contract.
 - e. Special issue projects were decreased related to COVID, but they are working on getting these back on track in 2022.
 - f. Thanks to reviewers, co-editors, and authors.
- 8. Meeting Organization & Program Planning Committee Report (Jennifer Burgoon) 3:29pm**
- a. Report of 2021 Annual Meeting Committee - focused on Planstone platform, submission guidelines, and reviewer guidelines. Looked for IRB approval on abstracts. Cancelled in-person to move to virtual status. We recognized that networking was missing last year and added more social activities this year.
 - b. Continue looking at posters, platforms, and symposia through tomorrow. Coffee Talk tomorrow on Fort Worth, CAT committee Lunch, Discussion on Teaching During COVID. Still can go to silent auction, which helps to fund scholarships.
 - c. Reviewed Abstracts and Registration
 - i. There were 52 published posters and 17 not published.
 - ii. Currently 284 people registered for meeting.
 - d. MOPP Members (committee chairs) were involved in conference planning.
 - e. Thanks to meeting managers. Yasmin will be rotating off, an email was sent out for interest in becoming a meeting manager – applications are due tomorrow.
 - f. Future Meetings:
 - i. Regional meeting - virtual Hosted by Nirusha at Mayo on 11/6
 - g. 2022 AACA Annual Meeting, Fort Worth, TX. – Rusty Reeves and Cara Fisher
 - i. Dates of 2022 meeting: 6/13-6/17 2022
 - ii. Discussed the different schools and programs at Fort Worth
 - iii. Center for Anatomical Sciences – encompasses all schools, body donor program
 - iv. Described clinical lab space & anatomy lab space, and donor program
 - v. Downtown at Fort Worth at Worthington Renaissance Hotel at Sundance Square
 - vi. Discussed the area and social activities (museums, restaurants, shopping, etc.)
 - vii. Described post-graduate course – Surgical Anatomy of Hand Transplantation. Steven Moran from Mayo Clinic will be leading this session (6/17).
 - h. 2023 AACA Annual Meeting, Orlando, FL
 - i. 7/9-7/12 2023 at Hilton Orlando at Beuna Vista Palace
 - i. 2024 AACA Annual Meeting, New York, NY – Estomih Mtui
 - i. Dates TBD
 - j. 2025 AACA Annual Meeting, Seattle, WA – Shane Tubbs
 - i. Dates: 6/16-6/19 2025
 - k. Looking for hosts for virtual meetings and future annual meetings. Please reach out if interested.
 - l. Please complete Post-Conference Survey.

9. Committee Elections (Robert Spinner)

3:34pm

- a. Election of Members-at-Large for Nominating: 3 vacancies
 - i. Nominated in advance: Homaira Azim (present), Ritwik Badya (not present), Efrain Miranda (not present), Jailenne Quinones (not present), Miguel Angel Reina (not present)
 - ii. Nominated during meeting: Sarah Keim, Peter Ward
 - iii. Each nominee introduced themselves.
 - iv. Robert spinner moved to accept 3 members
 - v. Lela Giannaris seconded
- b. Bylaws Committee: 2 vacancies
 - i. Nominated in advance: Craig Goodmurphy (present), Adam Kolatorowicz (present), Nirusha Lachman (withdrew), Christina Lewis (not present), Rebecca Pratt (not present), Sailabala Vanguri (not present), Peter Ward (withdrew), Sara Williams (not present)
 - ii. Nominated during meeting: None
 - iii. Each nominee introduced themselves.
 - iv. Motion to close nominations - David Porta
 - v. Seconded
- c. Financial Affairs Committee: 1 vacancy
 - i. Nominated in Advance: Eileen Kalmar (present), Jonathan Millard (not present), Diana Pettit (not present), David Porta (present), Daniel Topping (not present), Sailabala Vanguri (not present)
 - ii. Nominated during meeting: none
 - iii. Each nominee introduced themselves.
 - iv. Motion to close - Carol Lomneth
 - v. Second - Rusty Reeves
- d. Brand Promotion and Outreach Committee: 3 vacancies
 - i. Eiman Abdel Meguid (present), Jessica Immonen (present), Mohammed Khalil (present), Diana Pettit (not present), Rebecca Pratt (not present), Jailenne Quinones-Rodriguez (not present), Kumar Satish Ravi (not present), Elizabeth Spudich (not present), Sailabala Vanguri (not present)
 - ii. Nominated during meeting: Saskia Richtor, Kelsey Picha
 - iii. Each nominee introduced themselves.
 - iv. Motion to close – Lela Giannaris
 - v. Seconded
- e. Link for voting was shared.
 - i. Nominating: Homaira Azim, Sarah Keim, Peter Ward
 - ii. Bylaws – Craig Goodmurphy and Adam Kolatorowicz
 - iii. Financial Affairs: Eileen Kalmar
 - iv. Brand and Promotion: Saskia Richter, Jessica Imemnen, Kelsey Picha

10. Old Business

3:58pm

- a. Announced Trivia Night Winner

11. New Business

4:05pm

- a. Transfer of the gavel – Robert Spinner/Thomas Gest.

ADJOURNMENT: 4:06pm

2021 – 2022
Officers of the AACA Council

President – Thomas R. Gest, Ph.D.

President-Elect – R. Shane Tubbs, Ph.D.

Secretary – Sarah J. Greene, Ph.D.

Treasurer – Anthony V. D’Antoni, D.C., Ph.D.

Past-President – Robert J. Spinner, MD

Program Secretary – Jennifer M. Burgoon, Ph.D.

Councilors

Kathleen Carol Bubb, MD

Joe Iwanaga, DDS, Ph.D.

Gilbert M. Willett, Ph.D., PT, OCS

Koichi Watanabe, MD, Ph.D.

Nirusha Lachman, Ph.D.

Estomih P. Mtui, MD

Vaughan Lee, Ph.D.

Kazzara Raeburn, MD

James Coey, MD

Clinical Anatomy

The Official Journal of the American Association of Clinical Anatomists, the British Association of Clinical Anatomists, the Australian and New Zealand Association of Clinical Anatomists, and the Anatomical Society of Southern Africa.

Editor-in-Chief – R. Shane Tubbs

Editor Emeritus – Stephen W. Carmichael

AACA Senior Editor – Robert J. Spinner

AACA Co-Editors – Anthony V. D’Antoni, Thomas R. Gest, Joe Iwanaga,
Marios Loukas, Susan Standing

BACA Editor – Philip Addis

Assistant BACA Editor – Jenny Clancy

ANZACA Editor – Stephanie Woodley

ASSA Editor – Graham Louw

Founding Editors: Ralph Ger and Ray J. Scothorne

Editorial Board – 2022

Associate Editors

Marwan F. Abu-Hijleh
Keiichi Akita
Mahindra Kumar Anand
Robert H. Anderson
Nihal Apaydin
Ronald L.A.W. Bleys
Peter Dangerfield
Raffaele De Caro
Beom Sun Chung
Aaron S. Dumont
Fabrice Duparc
Georgi P. Georgiev
Duncan Lee Hamilton
Mi-Sun Hur
Soichiro Ibaragi
Ikuo Kageyama
Mohammed Khalil

Hee-Jin Kim
Nirusha Lachman
Chelsea M. Lohman Bonfiglio
Vishy Mahadevan
Tarik Massoud
Joanna Matthan
Stuart McDonald
Ali Mirjalili
Garrett Moore
Shumpei Mori
Alan Moulton
Richard Newell
Roelof-Jan Oostra
Friedrich Paulsen
Michał Polgaj
Łukasz Olewnik
Daisy Sahni

José Ramón Sañudo
Elias Rizk
Daisy Sahni
José Ramón Sañudo
Louise Scheuer
Thomas Shiozawa-Bayer
Albert van Schoor
Justin T. Tretter, Cincinnati, OH,
USA
Richard Tunstall, Warwick, UK
Jerzy Walocha, Kraków, Poland
Koichi Watanabe, Kurume, Japan
Peter L.T. Willian, Chesire, UK
Adam B. Wilson, Chicago, IL, USA
Lu Xu, New Orleans, Louisiana,
USA
Shengbo Yang, Zunyi, China

Managing Editor – Isaiah Tubbs
me.clinicalanatomy@gmail.com

Production Editor – Reeni Sunder
sreeni@wiley.com

Committee Reports

Anatomical Services Committee
Ad hoc Diversity Inclusion and Equity Committee
Brand Promotion and Outreach Committee
Bylaws Committee
Career Development Committee
Clinical Anatomical Terminology Committee
Educational Affairs Committee
Journal Committee
Listserv Report
Membership Committee
Meeting Organization & Program Planning Committee
Nominating Committee

Anatomical Services Committee Report

Members of the Anatomical Services Committee will be present at the Welcome Reception on Monday, June 13, from 7:30 pm to 9:00 pm. AACA meeting attendees interested in anatomical services are encouraged to attend, meet the committee members, and learn what we do and how to get involved.

Our symposium titled, “Modern Preservation Techniques & Maintaining Donor Quality Across Diverse Programing” is a panel discussion welcoming Camryn Hawkins, PhD, and Shawna Rodabaugh, MBA. Learner outcomes in the anatomy laboratory experience require a diverse repertoire of preservation techniques. This panel addresses modern techniques to help expand and optimize the donor for use in anatomy laboratories. Our discussion promises to be very exciting for all levels of our anatomy laboratory experiences.

The Anatomical Services Committee Breakfast Meeting will be held on Thursday, June 16, 7:30 am to 9:00 am.

Annually, our committee elects a new member from our at-large AACA membership. Please submit your nomination to any ASC member in advance. Self-nominations are welcome if you are interested in running for our open ASC position.

The agenda for this year’s meeting features our popular Lesson Learned session where real case studies in academic donation programs will be presented and Ask an Expert where questions concerning anatomical donation programs will be posed and advice solicited from AACA colleagues in attendance at the session.

Other agenda items include a report on the work of the ASC during the last year and a discussion of current topics, future meetings, and symposia. Active AACA members will also be electing a new ASC member. All meeting attendees are welcome!

Details of the ASC meeting are at: <http://clinical-anatomy.org/AnatomicalServicesCommitteeMeeting>.

For our “Lessons Learned” segment this year, Amanda J. Collins, MPH from the University of Massachusetts T.H. Chan School of Medicine will present, “Help me Medical Examiner – You’re Our Only Hope.” A reflection on how to ensure donor identity when the donor medical history is not consistent with dissection findings.

The ASC meeting is a perfect forum to “Ask an Expert”. This meeting is filled with experts on all aspects of body donation, from technical preparations to ethics, and policies to PPE. Your colleagues bring years of experience to the table, making our meeting a great place to find information and network. Following the meeting, we hope that members and attendees can continue networking over breakfast. Committee members can always be reached by email if you have any concerns or questions throughout the year. We are even open to Zooming if you prefer.

Come to the ASC meeting to listen or to be part of the conversation by sharing your experiences. We hope to see you there!

Eileen Kalmar, Academic Co-Chair

Amanda Mittelstadt, Technical Co-Chair

ASC Membership

Presidential Appointees:

2019-2022: Eileen Kalmar, Ohio State University, Academic Co-Chair Eileen.kalmar@osumc.edu

2020-2023: Nirusha Lachman, Mayo Clinic College of Medicine Lachman.nirusha@mayo.edu

2021-2024: Sebastian Cotofana, Mayo Clinic College of Medicine Cotofana.sebastian@mayo.edu

continued on next page

Elected Members:

2019-2022: Kelsey Byers, Indiana University ktbyers@iu.edu

2020-2023: Amanda Collins, University of Massachusetts T.H. Chan School of Medicine, Amanda.Collins@umassmed.edu

2021-2024: Amanda Mittelstadt, High Point University, Technical Co-Chair amittels@highpoint.edu

Ex Officio:

James Coey, St. George's University - ASC Special Councilor jamescoey@me.com

Ad-Hoc Diversity, Equity, and Inclusion Committee (DEIComm)

Members:

Yasmin Carter (Chair)
Chelsea Lohman Bonfiglio
Amanda Collins
Thomas R. Gest
Edgar R. Meyer
Haley L. Nation
Jonathan J. Wisco

Created in 2020, the Ad-Hoc Diversity, Equity, and Inclusion Committee (DEIComm), committee is charged by the AACA with promoting and fostering a culture that values diversity, equity, and inclusion in clinical anatomy. The charges of this ad hoc committee are as follows:

1. Surveying and evaluating AACA membership, statements, and activities on issues affecting diversity, equity, and inclusion in the clinical anatomy profession and
2. Identifying gaps and making recommendations to:
 1. Raise awareness and provide education on the importance of diversity and inclusion in the profession
 2. Promote outreach and mentorship
 3. Identify resources for training
 4. Support a forum for discussion on diversity and inclusion.

Current DEIComm Activities

The committee met monthly to discuss the needs of the membership, proposed budgets, awards, and future projects. At the 2021 AACA annual meeting, we presented an interactive poster at the 2021 conference entitled "The Sum of Our Voices: Toward Achieving Diversity, Equity, and Inclusion in the AACA" aimed at member outreach and promoting discussion of diversity. Towards goal four – we hosted a coffee talk during the 2021 meeting to introduce the goals of the committee to the association members. We presented an analysis of the current demographics of the membership and proposed new, more appropriate ways of surveying the membership to collect more accurate biographical information. To build relations with other associations we submitted a poster to the IFAA Anatomy Festival 2-021 which was focused on Inclusion, Diversity, and Accessibility. We have begun a proposal to the council for a diversity-focused award to highlight the incredible work of our diverse membership. In the next election cycle, we hope to move from an ad-hoc to a full committee.

Brand Promotion & Outreach Committee

Presidential Appointees:

2021-2024: Soo Kim, University of Saskatchewan, Chair, soo.kim@usask.ca

2021-2024: Nena Mason, Rocky Vista University, nmason@rvu.edu

2021-2023: Mikaela Stiver, University of Toronto, mikaela.stiver@mail.utoronto.ca

Elected Members-at-Large:

2021-2024: Jessica Immonen, University of Nevada Las Vegas, jessica.immonen@unlv.edu

2021-2024: Kelsey Picha, A.T. Still University, kpicha@atsu.edu

2021-2024: Saskia Richter, University of Delaware, richter.sask@gmail.com

Annual Report

Brand Promotion and Outreach Committee (BPOC) is responsible for the promotion, development, and maintenance of strategic initiatives of the Association with the overarching aims of expanding membership and increasing global reach. The BPOC is responsible for planning and overseeing fundraising efforts and associated travel awards for the Annual and Regional Meetings, managing the Association's social media presence, developing ongoing promotional materials and initiatives, and supporting outreach initiatives or opportunities.

During the past year, the BPOC continued to be busy with our promotional activities. In the fall, we helped the Anatomical Service Committee host a CART session. The speaker was Kelsey Byers who is the Director of Mortuary Services for Indiana University School of Medicine. In the spring, we hosted another CART session with our own AACA president, Dr. Thomas Gest. Both sessions were well attended. Our committee also spent time updating our social media and travel award guidelines. Given the success of our t-shirt design contest from last year, we organized another event for the 2022 annual meeting. In addition, as a new official Standing Committee for the AACA, we were excited to plan for our first lunch session for the annual meeting focusing on "Anatomy Outreach that is Within Reach".

The BPOC has continued to create promotional materials for various events throughout the year and grow our presence on social media platforms (current followers: Twitter >3100, Facebook >2200, Linked in >450, Instagram >45). We also continue to support regional meetings; the AACA regional meeting was on November 6, 2021, and was hosted by the Department of Clinical Anatomy, Mayo Clinic. We thank everyone for their support!

Bylaws Committee

Presidential Appointees:

Kathleen Bubb, Chair (2020-2022)

Mathangi Gilkes (2020-2022)

Ameed Raouf (2020-2022)

Elected Members:

Craig Goodmurphy (2021-2022)

Adam Kolatorowicz (2021-2022)

The Bylaws Committee makes recommendations to the Council on amendments to the Bylaws. The committee held videoconference meetings every third Sunday of the month. It submitted its version of AACA Bylaws revisions that will be up for a vote at the 2022 meeting. The proposed amendments were undertaken to better align the bylaws, with both actual and best practices, as well as to reflect important changes that have occurred in our AACA organizational structure.

Why change the bylaws? Weren't the old ones good?

The old bylaws were fine, but as always, needed some revisions to better reflect not only best practices but to align our expectations of how we as an association engage with the bylaws and best practices. Sometimes our practices and procedures need to be brought in line with both actual and intended practices to accurately reflect the values and practices of the association through a change in the bylaws.

continued on next page

What's changed?

The only changes have been made to Article VIII: Committees. We received an amendment by the Anatomical Services Committee which included the transition to a single chair. We also clarified the terms of service of members and chairs of each of the standing committees.

In addition to the proposed amendments, we created an official AACA Bylaws Committee Google Drive folder as a repository for previous work of the committee and to allow for synchronous and asynchronous work on bylaws and related projects. This will help with the continuity of work as members come and go from the committee. We began work on an AACA Bylaws Awareness Project and investigated feasibility of outreach with the Brand Promotion and Outreach Committee. We hope to better engage the membership with how our association functions. Finally, we began a review of the Bylaws posted on the AACA website.

If you are interested in serving and want to learn more about how our association works then please attend the annual business meeting where we will elect two new members.

Career Development Committee

The Career Development Committee (CDC) supports the career growth and advancement of clinical anatomy knowledge for an individual at any stage of their career. The CDC encourages high quality anatomical research and educational scholarship through responsibilities such as judging student posters (Sandy C. Marks, Jr Award), platform presentations (Ralph Ger Award), and hosting a reception at the annual meeting (Anatomy Career Connections Reception).

Over the past year, committee members met monthly to plan for the events of the annual meeting. For the June 2022 meeting the CDC will host two events, a lunch meeting and a welcoming reception called the Anatomy Career Connections Reception. The purpose of this reception is to foster connections between members looking for guidance on career advancement.

If you are interested in serving, have a passion for mentoring, or have innovative ideas to promote career growth, please consider becoming a member of the CDC. We will be electing one new member at our lunch meeting.

Presidential Appointees

2019-2022: Kirsten Moio, k-moio@northwestern.edu, Chair

2020-2023: Quentin Fogg, quentin.fogg@unimelb.edu.au

2021-2024: Rekha Kar, karr@uthscsa.edu

Members Elected at Annual SIG Meeting of Committee

2019-2022: Adam Wilson, adam_wilson@rush.edu

2020-2023: Padma Gadepally, gadepadm@isu.edu

2021-2024: Amanda Troy, atroy@rvu.edu

Clinical Anatomical Terminology Committee

The Clinical Anatomical Terminology (CAT) Committee will hold a breakfast meeting open to all attendees! The meeting will provide an overview of the activities of the CAT and its subcommittees, an opportunity to hear from its members and to join to them (via election), and an entertaining and informative quiz related to anatomical terminology. Members of the top scoring team (up to 4) will each win an enhanced eBook version of the 42nd edition of Gray's Anatomy, courtesy of Elsevier (<https://www.uk.elsevierhealth.com/grays-anatomy-9780702077050.html>). So come and join us and test your grasp of our anatomical language! The agenda for the breakfast meeting is as follows:

- Introduction to the AACA CAT Committee (5 minutes)
- Overview of CAT Subcommittee Activities (15 minutes)
- Elevator Pitches from Nominees and Election of two new members (20 minutes)
- Terminology Quiz*, with prizes for the winning team (45 minutes)
- Announcement of election results and welcoming new members (10 minutes)

* We will use the Kahoot! app for the game if you wish to download it ahead of time (<https://kahoot.com/home/mobile-app/>).

Follow the CAT Committee on Twitter @AACAnatomy_CAT for more updates on the breakfast meeting and for practice trivia questions!

Educational Affairs Committee

Purpose of Committee: The Educational Affairs Committee (EAC) shall promote the teaching of clinical anatomy, track national and international curricular trends and changes, and develop educational initiatives that will benefit the Association's members, health care professionals, the education community, and the general public. The Committee disseminates data and recommendations for best practices for all aspects of anatomical education as it relates to clinical practice. The Committee shall plan and implement the Educational Affairs Symposium when scheduled by the Meeting Oversight and Program Planning Committee. The Committee shall consist of six (6) members, each serving a three (3) year term. The President-Elect shall appoint one (1) member in the second year of his/her term, and the President shall appoint one (1) member in the first year of his/her term. One (1) member shall be nominated and elected by the Active Members in attendance at its annual open meeting.

During the 2021-2022 monthly EAC meetings, discussions focused on a variety of topics including: core learning objectives and anatomy syllabi, low technology educational tools, integrating anatomy workshops into clinical curricula, the importance of different learning styles (eg. COLT and Kolb), innovative tools to keep students engaged in active learning, etc. While numerous topics were discussed and researched, the committee chose to focus on two for the upcoming symposium and breakfast meeting at the AACA conference.

During the 2022 AACA conference, EAC will host a symposium entitled "Continuing Integration of Anatomy for Clinical Application and Practice". Participants will be introduced to the best practices for integrating anatomy into the clinical curriculum. This will include discussions on course structure, curriculum development, and program evaluation. Participants will hear these perspectives from a diverse array of speakers spanning from a clerkship director (Dr. William Rennie, Associate Professor of Science Education and Emergency Medicine at Zucker School of Medicine at Hofstra), anatomy educator (Dr. Mary Orczykowski, Lecturer III at University of Michigan), and health science professor (Dr. Marsha Rutland, Professor of Physical Therapy at Hardin-Simmons University).

During the 2022 AACA conference, EAC will also host a breakfast meeting entitled "Let's Talk About the Scary Stuff: Purposeful Inclusion of Diversity into Anatomy Curricula". Dr. Yasmin Carter (UMass Chan Medical School) will help lead a discussion on the role of basic science courses in establishing students' foundational knowledge in diversity and inclusion. Various ways of introducing diversity and inclusion topics into the anatomy curriculum will be demonstrated.

We invite you to participate and share your experiences related to the integration of anatomy into the clinical curriculum and the role of diversity and inclusion in anatomy curricula. For those interested in getting more involved, during the breakfast meeting on Tuesday June 14th we will be electing a new member to the Educational Affairs Committee. Looking forward to seeing you!

EAC Members:

Presidential Appointees 2018-2024:

2018-2022: Priti Mishall (priti.mishall@einsteinmed.org)

2019-2022: Eustathia Lela Giannaris (EustathiaLela.Giannaris@umassmed.edu)

2020-2023: Dolgor Baatar (Dolgor.X.Baatar@kp.org)

2021-2024: David Brzezinski (dbrzezini@med.umich.edu)

Members-at-Large Elected at Annual SIG Meeting of Committee:

2021-2024: Kathy Pappas (kpappas2@springfieldcollege.edu)

2020-2023: Haley Nation, Chair (Nation@uthscsa.edu)

Journal Committee Report

Committee Members: Robert Spinner, Tom Gest, Marios Loukas, Anthony D'Antoni, Kazzara Raeburn (Presidential Appointee, Andy Maldonado (Wiley), Peter Dangerfield (ex officio; Editor BACA), Shane Tubbs (Editor-in-Chief).

The Journal has continued to break new records over the last year. These include publishing cutting-edge papers with high citations and an increased numbers of downloads. The Journal continues to be a leader in its field and is attracting both international authors and a worldwide audience. The current impact factor has been the highest in the history of the Journal at 2.4.

Listserv Report

AACA's Education Issues Listserv was moved from the mail server at Einstein to being hosted on Google Groups in February of 2016. There are currently 1,128 subscribers to AACA's Listserv. From May 1, 2021 to April 1, 2022 there were 22 subjects posted. To the right of this report is a table of those posts that received the most responses.

AACA Education List

Total Subscribers (as of 4/1/22) = 1128

Monthly Email Activity from 5/1/22-4/1/22

May '21 = 0

June '21 = 1

July '21 = 1

August '21 = 1

September '21 = 2

October '21 = 3

November '21 = 4

December '21 = 2

January '22 = 2

February '22 = 3

March '22 = 3

April 1, '22 = 0

Total Emails = 22 Total Replies = 3

<p>Most Commented upon Threads:</p>
--

<p>PLASTINATION Online Meeting, April 26-29th, 2021 - (2)</p>
--

<p>AERI 2022 is Now Accepting applications! - (1)</p>
--

Membership Committee

President-Elect – R. Shane Tubbs

Past President – Robert J. Spinner

(2020 – 2022) Presidential Appointee – James Foster

(2021 – 2023) Presidential Appointee – Skyler Jenkins

The membership committee is pleased to state that 132 new members have joined the AACA from July 25, 2021, to April 1, 2022. The total number of active members in the association is 554.

AFFILIATE

Raj Sam

Somin Jo

Julie-Ann Nguyen

ASSOCIATE PRINT COPY

Carrie Wallace

ASSOCIATE POST-DOC ELECTRONIC

Mark Unger

Elizabeth Cho

Rafika Munawara Ayub Khan

ASSOCIATE ELECTRONIC

Lokesh Coomar

Nathan Rizk

Hana Abualadas

Ayla Siddiqui

Jason Hubener

Allison M. Martin

Taylor Robertson

Lauren Balentine

Michael Baum

Benjamin Johnson

Brittney Link

Minh Pham

Taylor Coffman

Wayne Ngo

Celine Talley

Chandler Dykstra

Paige Stratton

Alexa Fritsch

Megan Kalinowski

Abigail Limov

Courtney Miller

Pavel Gonzalez

Sonali Rathod

Ryan Anderson

Nawsin Baset

Brandon Gonzalez

Grishma Pradhan

Steve Abraham

Airada Bricker

Tooba Husain

Alexander In

Alexa P. Kelly

Conner Lynn

Jacob Moore

Sirai Ramirez

Ryan Schiller

Ferris Zeitouni

Mitchell Couldwell

Hannah Curry

Kara Fadanelli

Kassidy Heitzmann

Lena Khachik

Sara Khan

Courtney Lewis

Vidur Marwaha

Joseph Mercho

Joseph O'Brien

Amirhassan Parvizi

Maureen Purcell

John Sakowski

Amanda Warner

Taylor Craig

Jonathon Hines

Swai Mon Khaing

Donald Lester

Loeto Magang

Brooke Martin

Indya Thompson

Haeryun Ahn

Hyo-Sang Ahn

Hyungkyu Bae

Suneeti Dash

Kyu-Lim Lee

Jiongzhen Piao

Jonathan Guihurt

Soobin Kim

REGULAR ELECTRONIC

Trisha Waldman

Patrick Frank

Bonny Ford

Francisco Reina

Erica Malone

Melissa Zolnierz

Sumathilatha Sakthi Velavan

Chandana Bhargavi

Colleen Cheverko

Tony Pinazza

Jiepei Zhu

Ahmad Imam

Michael Jones

Mehandi Mahajan

Camryn Hawkins

Liana Wooten

Sadie McConner

Balachandar Kathirvelu

Piero Antonio Zecca

Helena Schmitt

Rachel Menegaz

Tafline Arbor

Amy Shank

Judithe LaBarge

Alexis Kendrick

Bertha Amirtha Deva

Rathinam

Keishirou Kikuchi

Carleen de Leon

Scott Maddux

Rosaysela Santos

Alexander Evins

Ryan Knigge

Nicole Robinson

Orhan Arslan

Michael Turnwald

Heba Labib

Cameron Bassett

Emily Klopp

Mary Moon

Jay Bauman

Christopher Ferrigno

Matthew Kling

Katherine Dougherty

Nitsa Topale

Sasha Lake

Claudia Cárceles Román

Stefanie Attardi

Sasha Lake

Skyler Jenkins

Deon Forrester

REGULAR – PRINT

Geetika Mittal

Vikas Jain

Dr. Manoj Kumar

Dominic Severino

Samir Anadkat

Zygmunt Domagala

REGULAR (ANATOMICAL SERVICES) – ELECTRONIC

Jamie Moore

Alisa Richardson

REGULAR (ANATOMICAL SERVICES) – PRINT

Jacqueline Flores Otero

continued on next page

Meeting Organization & Program Planning Committee

Members:

Special Interest Committees

Anatomical Services Committee (ASC), Co-Chairs – Eileen Kalmar & Amanda Mittelstadt

Brand Promotion and Outreach Committee (BPOC) – Soo Kim

Career Development Committee (CDC), Chair – Kirsten Moisio

Clinical Anatomical Terminology Committee (CAT), Co-Chairs – Chelsea Lohman-Bonfiglio & Richard Tunstall

Educational Affairs Committee (EAC), Chair – Haley Nation

Meeting Managers (Formerly Known as Annual Meeting Committee Co-Chairs)

Melissa Quinn 2021-2022

Sarah Keim-Janssen 2022-2023

Amberly Reynolds 2023-2024

Local Hosts

Rusty Reeves & Cara Fisher – 2022

Estomih Mtui & Anthony D'Antoni – 2024

R. Shane Tubbs & Joe Iwanaga – 2025

ASG Representatives (Contracted Professional Organization Management Company)

Caitlin Hyatt, Executive Director

Jennifer Whitlow, Assistant Executive Director

Kendra Tyner, Program Coordinator

Executive Committee

Thomas Gest, President

R. Shane Tubbs, President-Elect

Robert Spinner, Past President

Anthony D'Antoni, Treasurer

Sarah Greene, Association Secretary

Jennifer Burgoon, Program Secretary & MOPP Chair

This report is being filed on April 18, 2022. The information contained herein is the most accurate available as of this date. I am completing the first year of my 3-year term as Program Secretary, after serving a previous 3-year term as Program Secretary and a 2-year term as a Meeting Manager.

During the 2021-2022 year, the Meeting Organization and Program Planning (MOPP) Committee has been working diligently to bring you an in-person annual meeting at the Worthington Renaissance Hotel in Fort Worth, Texas from June 13-17, 2022, the first in-person meeting for the AACA since 2019 in Tulsa, Oklahoma. Planning began immediately following the 2021 Virtual Conference, the society's second virtual annual meeting ever, by a thorough review of the post-conference surveys. During the year, the MOPP Committee held conference calls during the second week each month. This year we welcomed the Chair of the Brand Promotion and Outreach Committee (BPOC) as an official member of MOPP, a result of the membership's vote to change the association's bylaws in the spring of 2021. This addition to MOPP was key, as the BPOC's tasks and endeavors often are tied to conference activities. Also on the calls monthly were the two local hosts for the 2022 Annual Meeting, specifically Rusty Reeves and Cara Fisher from the University of North Texas Health Science Center.

The 2022 AACA Annual Conference and the program you are reading are the direct result of the tireless effort of the MOPP Committee and through the exceptional professional support of ASG. Special thanks to Caitlin Hyatt, Kendra Tyner, Jennifer Whitlow, Melissa Quinn, Sarah Keim-Janssen, and Amberly Reynolds whose work behind the scenes on behalf of the MOPP Committee has made the 2022 AACA Annual Conference possible.

This year's meeting is certainly an energizing experience and one that we hope all attendees will enjoy. First, the Tech Fair has returned for the first time since the 2018 Atlanta meeting. Next, we have also brought back many positive aspects of the 2021 Virtual Conference. For example, all member presentations (i.e., platform, Tech Fair, and poster) will still be available to conference attendees in the virtual setting (i.e., Planstone), a great benefit to those judging posters and a perfect way to

preserve the exceptional work of our members. Again, attendees will be able to provide feedback for all these presentations via Planstone. It is our hope that this will again offer a virtual forum for collegiality that will also be experienced once again at the in-person portion of the Annual Meeting.

Also, back again from the 2021 Virtual Conference is the wildly successful Trivia Night – this time in-person! A special thanks to Peter Ward for his work developing questions, planning the layout, and hosting the 2021 Virtual Trivia Night. This year’s Trivia Night is being developed and run by a team lead by Peter Ward. Members of this team include Sarah Keim-Janssen, Bobbi Morgan, and Rebecca Pratt. A special thanks to all individuals involved.

Finally, realizing the importance of the Annual Meeting, a company (i.e., Feathr) was hired for the first time to assist in the advertising of the 2022 Annual Meeting. Feathr worked to provide digital advertising and email campaigns, all with feedback analytics including conversion tracking.

Preliminary Planning for Future AACA Meetings

One of my goals for the MOPP Committee is to have in place early the future AACA Annual Conferences. Thus far, we have been able to plan the following:

- 2023 Annual AACA Meeting to be held at the Hilton Orlando Buena Vista Palace in Orlando, Florida July 9 – 12, 2023.
- 2024 Annual AACA Meeting to be held at Weill Cornell Medicine in New York, New York June 17-21, 2024 and hosted by Estomih Mtui and Anthony D’Antoni.
- 2025 Annual AACA Meeting to be held at the Hyatt Regency Bellevue in Seattle (Bellevue), Washington June 16 – 19, 2025 and hosted by R. Shane Tubbs and Joe Iwanaga.

If you are interested in hosting a regional and/or annual meeting, please contact me via email (jennifer.burgoon20@gmail.com).

Abstract Submissions

Each year, the MOPP Committee reviews all its documents, including the Abstract Submission Guidelines, in an effort to improve clarity. The AACA works to accept completed, original, previously unpublished work that has IACUC and IRB approval, if applicable.

The table below shows the recent trends regarding abstracts, attendance, and presentations at our conferences:

Meeting Stats	2022 Fort Worth	2021 Virtual	2020 Virtual	2019 Tulsa	2018 Atlanta	2017 Minneapolis	2016 Oakland	2015 Vegas
Initial Abstract Subs	97	78	141	97	147	135	195	147
Returned for Format	38	0	15	16	13	10	32	51
Late-Breaking Subs	15	18	15	11	15	10	4	21
Total Rejections	7	9	6	3	2	1	23	24
Registrants	96*	338	437	290	350	345	350	338
Platform Presentations	17	12	27	20	24	16	18	22
Tech Fair Presentations	7	0**	0**	0**	7	7	5	3
Publishable Posters	66	51	104	63	98	97	115	78
Non-Publishable Posters	15	17	19	11	29	22	26	43

*Registration for the 2022 AACA Annual Scientific Conference is ongoing, and this number is as of April 18, 2022.

**No Tech Fairs were held during the 2019-2021 AACA Meeting as not enough abstracts were submitted to necessitate the session. Additionally, virtual meetings do not provide the hands-on opportunities the in-person meetings achieve, which are needed for this event to be successful.

In closing, please let the MOPP committee know of any improvements we can make to the conference through emailing those listed above and/or completing the post-conference survey. As always, we are striving to provide you with the best conference possible.

Nominating Committee Report

The Nominating Committee consists of presidential appointees Jonathan Wisco (Chair) and Kimberly Topp, and elected members-at-large Homaira Azim, Sarah Keim, and Peter Ward. On November 1, 2021, the Committee met for the first time on a conference call; the main aim of the discussion was to identify a diverse group of candidates from active members of AACA. Over the subsequent three months, the committee deliberated over the candidates' qualifications and contributions to our association, then determined finalists to contact for interest in nominations. After receiving confirmation, a slate of candidates was sent to Sarah Greene, the Association Secretary. Each candidate was directed to send a copy of their CV and candidacy statement to the committee and to the association in care of Caitlin Hyatt, the Executive Director.

Abstracts – Platform Presentations

* Accepted for Electronic Publication in *Clinical Anatomy*
(Listed by presenting author last name)

PLATFORM SESSION 1

*LIN, Dustin C.¹, Alexander IN², Vincent Y. BARIBEAU³ and Jonathan J. WISCO¹.¹Department of Anatomy and Neurobiology, Boston University School of Medicine, Boston, MA, 02118, USA; ²Virginia Tech Carilion School of Medicine, Roanoke, VA, 24016, USA; ³Department of Anesthesia, Critical Care and Pain Medicine, Beth Israel Deaconess Medical Center, Boston, MA, 02118, USA.

Congenital Hand Malformations: A Potential Case of Symbrachydactyly and Contrahentes Digitorum.

INTRODUCTION. This study investigates the anatomy of a cadaveric hand presenting with a rare variation that we identified as symbrachydactyly. RESOURCES. We performed a layer-by-layer dissection of the affected cadaveric hand and documented both the normal and variant anatomical compositions that were present. DESCRIPTION. Normal development of most surrounding musculature also was observed with the exception of a triple headed adductor pollicis muscle. The osteology revealed complete aplasia of the proximal and middle phalanges of the second, third, fourth, and fifth digits along with truncated distal phalanges of the fourth and fifth digits. The radius, ulna, carpal bones, and the first digit was unremarkable. Neurovasculature followed standard anatomical courses. SIGNIFICANCE. Congenital hand malformations are infrequently observed in the anatomy lab and provide a unique learning opportunity for students and faculty alike. While hand deformities are frequently imaged through noninvasive techniques such as x-rays and CT imaging, they are infrequently dissected. Through dissection, clinicians and anatomists may be able to adopt a more tangible appreciation for the underlying anatomy of this condition.

*CAMPISI, Emma S.¹, Catherine AMARA², Sharon SWITZER-MCINTYRE³, and Anne M. R. AGUR¹. ¹Division of Anatomy, Department of Surgery, Temerty Faculty of Medicine, University of Toronto, Toronto, ON, M5S 1A8, Canada; ²Faculty of Kinesiology and Physical Education, University of Toronto, Toronto, ON, M5S 2W6, Canada; ³Department of Physical Therapy, Temerty Faculty of Medicine, University of Toronto, Toronto, ON, M5G 1V7, Canada.

Intramuscular Innervation of Flexor Digitorum Profundus: Implication for Botulinum Toxin Injection.

INTRODUCTION. Knowledge of the 3D innervation of the digital bellies of flexor digitorum profundus (FDP) is necessary to optimize Botulinum toxin (BoNT) injection sites for management of post-stroke spasticity. Previous cadaveric studies have focused on nerve entry points; no 3D intramuscular innervation studies of FDP were found. The purpose of this study was to: 1) model and map in 3D the intramuscular innervation of the FDP digital bellies, 2) compare and contrast the frequency of innervation patterns and 3) to propose optimum sites for BoNT injection. METHODS. Serial dissection, digitization (MicroScribe® Digitizer) and laser scanning (FARO® Quantum FaroArm®) of the nerve distribution and muscle volume of FDP was conducted in 5 embalmed specimens (mean age 81.2±11.4yrs). The data were reconstructed into 3D models (Autodesk® Maya®) to visualize, document, and compare intramuscular innervation patterns of the bellies of FDP. Based on these findings, optimal sites for BoNT injection were proposed. SUMMARY. The median nerve gave off 2 branches, one to the 2nd belly and one to the 3rd belly, at the junction of the superior and middle thirds of FDP. The intramuscular branch of the 2nd belly arborized to supply the entire belly. Intramuscular innervation from the median nerve was distributed to the distal (n=4) or proximal half (n=1) of the 3rd belly. The ulnar nerve gave off 2 (n=3) or 3 (n=2) branches to FDP in the proximal third of the muscle. One branch innervated the 3rd belly, and the second the 4th belly. If 3 branches were present, the third branch innervated the 5th belly. The 5th belly, in 3 specimens, was innervated by an intramuscular branch of the 4th belly. CONCLUSIONS. Based on the findings, 2 BoNT injection sites into the medial and lateral aspects of the proximal third of the muscle could target the 2nd/3rd, and 3rd/4th/5th digital bellies respectively. Further clinical study is needed to determine the efficacy of these anatomical findings.

*COFFMAN, Taylor G., Cara FISHER, Dan NASH, and Emma HANDLER. Department of Anatomy and Physiology, University of North Texas Health Science Center, Fort Worth, TX, 76107, USA.

Ultrasound Massage to Decrease Anesthetic Spread in Supraclavicular Blocks: A Cadaveric Study.

INTRODUCTION. Peripheral nerve blocks of the brachial plexus have become increasingly popular for upper limb surgery due to the benefits of using regional anesthesia. However, anesthetic from supraclavicular nerve blocks can spread medially and anesthetize the phrenic nerve, leading to partial paralysis of the diaphragm. There has been little research focused on whether or not ultrasound massage could manipulate anesthetic away from the phrenic nerve. The aim of this study is to determine if ultrasound massage can be used to minimize the spread of anesthesia medially. METHODS. Four fresh frozen cadavers were injected with 15 mls of a 25:75 mixture of methylene blue and 2% lidocaine. The specimens were divided into control (n=4) and massage (n=4) groups. A nurse anesthetist used ultrasound guidance to perform a supraclavicular

continued on next page

Abstracts - Platform Presentations continued

block. Immediately following injection, the massage group received 5 distally directed massage strokes with the ultrasound transducer. After 15 minutes, both groups were dissected and measurements of anesthetic spread were taken. The medial spread was measured in all four cadavers and distal spread was measured in three out of the four. SUMMARY. Spread of anesthetic medially was not reduced in the massage group when compared to the control group. Distal spread of the anesthetic was increased in the massage group when compared to the control group ($p < 0.05$). CONCLUSIONS. The similarity of medial spread between the two groups implies ultrasound massage application will not prevent phrenic nerve palsy any more than a traditional supraclavicular block. The increased distal spread of the anesthetic suggests this technique can improve anesthesia to the brachial plexus by increasing the area the anesthetic travels. Given the small sample size, continued study of this method is needed to further evaluate if this method could be used to reduce incidence of phrenic nerve palsy.

PLATFORM SESSION 2

*KAUR, Gurvinder, Keith BISHOP, and Brandt SCHNEIDER. Department of Medical Education, School of Medicine, Texas Tech University Health Sciences Center, Lubbock, TX, 79430, USA.
Highlighting the Benefits of Cadaveric Dissection in the Era of Digital World.

INTRODUCTION. Over the past two years the pandemic has created challenges to anatomy education and many schools have shifted from in-person dissection to online teaching. Cadaveric dissection relies on in-person interactions thereby making it more difficult to teach in-person during COVID. At Texas Tech University Health Sciences Center (TTUHSC), protocols that we developed to teach labs safely during the pandemic provided us with an opportunity to assess the impact of dissection on students' ability to learn anatomy. Our goal was to determine if cadaveric dissection improved test performance on related anatomical concepts. METHODS. Social distancing was achieved by assigning students to dissection or non-dissection groups. In this approach a maximum of two students dissected in-person at a time. Non-dissecting students reviewed each lab previously dissected by their peers. Complete Anatomy, a 3D anatomy atlas software, along with modules from each laboratory dissection were provided to all the students. The division of the class into dissector and non-dissector groups allowed us to determine the impact of dissection on exam performance. SUMMARY. In 2020 and 2021, laboratory sessions were ranked highest by the students as their preferred learning resource. Most significantly, we saw a direct correlation between in-person dissection and exam performance. Students missed significantly fewer questions on the practical exam directly related to material that they dissected as compared to students that only reviewed the same material ($p < 0.0001$). The overall performance on unit exams and shelf NBME during the pandemic was equivalent to previous years even though TTUHSC transitioned from categorical to Pass/Fail grading system. CONCLUSIONS. Our data indicate that hands-on learning experiences as exemplified by cadaveric dissection enhances students' learning abilities and retention of anatomical competency. Additionally, in-person laboratory experiences were considered the most valuable learning resource by students. (Approved by TTUHSC QIRB #QI-17008, 20064.)

*JO, Somin, Julie-Ann NGUYEN, Rocio ANGELES, Alisa RICHARDSON, and Sakti SRIVASTAVA. Division of Clinical Anatomy, Department of Surgery, School of Medicine, Stanford University, Stanford, CA, 94305, USA.
The Utilization of Virtual Reality (VR) Anatomical Models in Anatomy Education.

INTRODUCTION. Stanford's Division of Clinical Anatomy offered a virtual, week-long Clinical Anatomy Summer Program (CASP) to pre-health students, utilizing VR anatomical models accessible via the Engage platform on Oculus Quest headsets as a teaching modality. The first iteration of CASP with VR in 2020 emphasized the need for VR improvements related to connectivity, audio, graphics, and setup instructions, which were applied in 2021. This study aimed to determine if the VR improvements affected the learning experience and evaluate the effectiveness and student perception of VR in teaching anatomy. METHODS. Data was collected from an anonymous Qualtrics survey that utilized 5-point Likert scale questions and short answer responses based on the VR experience and analyzed using SPSS. SUMMARY. The survey yielded a response rate of 39% ($n = 32$). When asked to evaluate the overall VR experience, survey results of 2020 students ($Mn = 4$) were lower than 2021 students ($Mn = 4.28$). A Mann-Whitney test indicated that this difference was not statistically significant, $U(N_{2020} \text{ students} = 44, N_{2021} \text{ students} = 32) = 291, z = -1.151, p = .25$. A Chi-Square Goodness of Fit Test, $\chi^2(4, n = 32) = 19.79, p = .0005$, rejected our expectations that most of the 2021 students would have negative reactions to VR due to the burnout experienced from virtual learning during the pandemic. 69% of students strongly agreed that VR was a positive learning experience, and 44% specifically mentioned that the 3D visualization of anatomical structures improved their understanding of the lecture material. Almost half the students (48%) indicated mild to moderate nausea. Most students indicated that 30 minute VR sessions would be most effective. CONCLUSIONS. Despite implementing improvements to VR, no significant difference was shown in the perceived learning experience. Students widely viewed VR as a valuable supplement that helped them to better understand the lecture material, and its influence was not affected by the weariness of online learning during the pandemic contrary to our expectations.

continued on next page

Abstracts - Platform Presentations continued

*RAOOF, Ameer¹, Anas ABED², Kathar ALNAJJAR², Lina YAGAN², Mohammed ALIBRAHIM², Haya ALTAWHEEL², M. Fatin ISHTIAQ², Avelin MALYANGO¹, Mange MANYAMA¹, Charles MSUYA¹, and Nasnass NASSIR¹. ¹Medical Education Division, Weill Cornell Medicine-Qatar, Qatar Foundation, Doha, Qatar; ²Class 2022, Weill Cornell Medicine-Qatar, Qatar Foundation, Doha, Qatar.

To What Extent Do Online High-Yield Anatomy Modules Aid in Enhancing Medical Students' Performance?

INTRODUCTION. Gross anatomy is commonly believed to be the most difficult subject faced in the beginning of one's medical career. This study aimed at creating high yield online anatomy modules. Modules were created weekly on the relevant lab sessions and posted on Canvas. The primary outcome was to enhance student's performance on Essential Principles of Medicine (EPOM) course weekly quizzes, and the secondary outcome is the student satisfaction based on survey response. Results showed that students who completed 3 or more modules had higher anatomy quiz scores. In addition, the survey response was that students strongly agreed that the modules had several benefits. **METHODS.** High yield online modules were created for the gross anatomy course. Modules covered essential topics such as the thorax, and abdomen and consisted of 5-10 board-style questions followed by a 15-minute-video presentation discussing the questions and topics with narration for the week's lab. The modules were available prior to the anatomy lab sessions for students to prepare beforehand. Student satisfaction was assessed and quantified through a 5-point Likert scale survey. **SUMMARY.** Class size was 46 students. The average anatomy weekly quiz score was 92% for those who did more modules versus 85% for those who attempted 2 or less modules. The independent sample t-test confirms this was a significant difference. The average survey response was that students strongly agreed that the modules were pertinent, clear, and helped prepare for the quiz. **CONCLUSIONS.** Students who attempted more modules (does-effect) were obviously exposed to more questions and get more repetition of the high-yield material. The survey results showed that most students believe that the modules were pertinent and helped prepare for quizzes. Despite the small sample size, this study illustrates why supplementing the anatomy course with innovative online modules can enhance student's learning experience and satisfaction.

*IN, Alexander¹, Vincent Y. BARIBEAU², Dustin C. LIN³, Ann M. FEFFERMAN³, John D. MITCHELL², and Jonathan J. WISCO³. ¹Virginia Tech Carilion School of Medicine, Roanoke, VA, 24016, USA; ²Department of Anesthesia, Critical Care and Pain Medicine, Beth Israel Deaconess Medical Center, Boston, MA, 02118, USA; ³Department of Anatomy and Neurobiology, Boston, MA, 02118, USA.

Quantitative Measurement of Dissection: Differentiation of Dissectors Using Hand Motion Analysis.

INTRODUCTION. The act of dissecting has often been described as beneficial for the acquisition of fine motor skills; however, the technical components are often evaluated subjectively and rated as higher quality based on the cleanliness of the dissection. In this study, we objectively assessed dissection performance in anatomists by using hand motion analysis. We hypothesized that anatomists identified as experts, through criteria of self-administered survey, would require less time and overall movement to complete a plantar foot dissection. **METHODS.** Participants included 9 medical students and 2 anatomy faculty members where each participant performed a plantar foot dissection on a human cadaver. To quantify hand movements, sensors were attached to the first metacarpal of the first digit on both right and left hands. Four motion metrics were recorded using a Polhemus Liberty (Polhemus, Colchester, VT) motion tracker, including: total distance travelled (path length), total difference in angulation (rotational sum), number of movements performed (translational motions) and time. All participants were right-handed. Following dissection, participants were asked to complete a Qualtrics survey, in which the results were utilized as a mean to categorize the anatomists into expert (n=7) and novice (n=4) cohorts, based on hours of total and recent dissection experience. **SUMMARY.** Experts exhibited significantly less path length, rotational sum and translational motions in their right hand, and significantly less translational motions in their left-hand than novices (p=0.024, 0.042, 0.009, and 0.013, respectively). Experts also completed the dissection in significantly less time than novices (p=0.007). **CONCLUSIONS.** The technical components of dissection skills are traditionally evaluated subjectively, but through motion analysis, the dissection performance of novices and experts were objectively distinguished.

*CARTER, Yasmin, Amanda J. COLLINS, Eustathia Lela GIANNARIS, and Alexandra E. WINK. Division of Translational Anatomy, Department of Radiology, UMass Chan Medical School, Worcester, MA, 01655, USA.

What's in A Name? Reflecting Diversity in the Anatomy Lab.

INTRODUCTION. UMass Chan Medical School expanded the anatomy content to be more inclusive and diverse for first-year medical students. This expansion modified how donors are regarded in the lab, acknowledging the limitations of understanding the patient/donor lived-experience. This framework included the use of curated pseudonyms for the donors and the expansion of the existing "Diversity in Anatomy" didactic to further emphasize humanistic, anti-racism, and anti-bias behaviors during early preclinical training. **RESOURCES.** The first-day diversity session included a discussion of principles of anatomical assumptions, including gender, sex, ability, lived-experience, race, and ethnicity. It also highlighted potential biases with first meeting a patient on paper. Lab teams are provided with a donor's self-reported medical and social data, including limited demographic data. Our updated approach assigned gender-neutral and culturally inclusive first and last names to each of the 27 donors utilized in the course. **DESCRIPTION.** To further the inclusive and humanistic

continued on next page

Abstracts - Platform Presentations continued

approach to the lab experience, pseudonyms were assigned to the donors since the donation consent forms precluded disclosure of actual names. Each first name was chosen to be gender-neutral; each last name was chosen from a list of the most common surnames to represent numerous countries, cultures, and ethnicities. To socialize these concepts, a didactic session was given to explain the principles behind the choice of names and how to approach discussing a donor's body without assumptions or prompting bias. SIGNIFICANCE. The anatomy lab donor experience provides a unique opportunity to support and train learners in diversity, anti-racism, and anti-bias curricula. This approach allows students to address the assumptions they make when reviewing written patient data; fostering growth and competency in diversity, equity and inclusion essential for clinical practice and patient care.

*ANDERSON, Ryan J., and Jennifer BRUECKNER-COLLINS. Department of Anatomical Sciences and Neurobiology, School of Medicine, University of Louisville, Louisville, KY, 40202, USA.

The Hidden Curriculum: Student Lessons from the Medical Anatomy Laboratory from 2018 to 2021.

INTRODUCTION. The COVID-19 pandemic has necessitated significant changes in medical anatomy laboratory instruction at many universities over the past 2 years. Much has been published regarding the use of technology to substitute for face-to-face instruction with anatomical dissection; yet the impact of this paradigm shift on the student experience has not been fully characterized. The objective of this study was to identify how medical student experiences in and perceptions of anatomy laboratory instruction have differed at University of Louisville since 2018 through various modes of delivery (dissection, virtual, hybrid). METHODS. A series of 4 focus groups for the medical Classes of 2022 (n=8), 2023 (n=6), 2024 (n=10) and 2025 (n=7) were convened to pose 4 open ended questions about their classes' unique anatomy lab experience. The Classes of 2022 and 2023 had a fully dissection-based lab, the Class of 2024 had a fully virtual lab experience and the Class of 2025 had a hybrid lab. Student responses from each focus group were recorded, transcribed, categorized, and patterns within the data were documented. Triangulation was utilized to validate observations: researcher observations, second observer observations and member checking. SUMMARY. Four categories emerged from thematic analysis of each of the 4 medical classes in this study. Themes for the Classes of 2022, 2023 and 2025 included humanistic lessons, teamwork, kinesthetic learning and self-efficacy. The Class of 2024 instead focused on adaptability, anxiety about future patient encounters, concerns regarding anatomical orientation and a sense of an incomplete learning experience; these themes resulted in negative emotional responses from the Class of 2024, including feeling defeated, overwhelmed, frustrated and unsupported. CONCLUSIONS. A comprehensive analysis of this focus group data provided valuable information on the numerous benefits of in person, dissection-based anatomy lab instruction for first year medical students.

PLATFORM SESSION 3

*EFFERMAN, Ann M.¹, Ronald YANG², Shiaomeng TSE¹, Alivia LI¹, and Jonathan J. WISCO¹. ¹Boston University School of Medicine, Department of Anatomy and Neurobiology, Boston, MA, 02118, USA; ²Rowan University, Department of Biomedical Engineering, Glassboro, NJ, 08028, USA.

Superior Cervical and Stellate Ganglia Remodeling in Heart and Brain Vascular Pathology.

INTRODUCTION. The stellate ganglion (SG) is the primary sympathetic input to the heart. Its cell bodies increase in size and density in response to cardiovascular disease (CVD) such as heart attack. We hypothesize that the superior cervical ganglion (SCG), the major sympathetic input to the brain, also alters its structure in response to cerebral vascular pathologies (CVP). METHODS. Biopsies of SG and SCG were collected from 31 embalmed cadaveric donors then coronally sectioned and stained with luxol fast blue and cresyl violet. Slides were digitally scanned, and Python coding was used to generate heatmaps representing relative number, size and density of cell bodies in ganglia. Heatmaps were qualitatively compared by cause of death. SUMMARY. SCG from donors who died of CVP had higher nearest neighbor density weighted by size (NNDS) compared to the stellate ganglia from the same donors, and compared to SCG from donors who did not die of CVP. The NNDS in the SG was also modestly elevated for donors who died of CVP. A similar, but stronger, increase in NNDS was seen in SG corresponding to donors who died of CVD, although the SCG from those donors did not show concomitant structural changes. CONCLUSIONS. The SCG increases NNDS corresponding to brain pathology. The sympathetic chain may serve as a communication pathway between the heart and brain since the SG also increases NNDS in disease states related to the brain. Although limitations exist in understanding the precise clinical manifestations of these changes, the greater NNDS of ganglia likely relate to higher levels of activity in these structures, producing a maladaptive response especially in low perfusion states. (Sponsored by the National Heart, Lung, And Blood Institute of the National Institutes of Health under Award Number T35HL139444. The content is solely the responsibility of the authors and does not necessarily represent the official views of the National Institutes of Health.)

continued on next page

Abstracts - Platform Presentations continued

*ANADKAT, Samir¹, Joe IWANAGA², and R. Shane TUBBS^{1,2}. ¹Department of Structural and Cellular Biology, Tulane University School of Medicine, New Orleans, LA, 70112, USA; ²Department of Neurosurgery, Tulane Center for Clinical Neurosciences, Tulane University School of Medicine, New Orleans, LA, 70112, USA.
Anatomical Study of the Atrioventricular Nodal Branch of the Heart.

INTRODUCTION. The atrioventricular node (AV node) is a relay station for electrical signals passing between the atria and ventricles. The artery supplying the AV node is functionally important and its anatomical topography is relevant during invasive procedures. Therefore, the aim of this study was to identify and understand the variations of the origin of the AV nodal branch (AVNb) and its variations. METHODS. We dissected 31 adult human hearts to evaluate their AVNb and its variations. A classification scheme was used to detail the morphology found for each of these arteries. SUMMARY. We identified five distinct origins of the AVNb: AVNb originating from the right coronary artery (RCA) proximal to the inferior interventricular branch (IVb) (type I, 3.2%), AVNb originating from the junction of the RCA and IVb (type II, 19.4%), AVNb originating from the RCA distal to the IVb (type III, 64.5%), AVNb originating from the IVb (type IV, 6.5%), or AVNb originating from the circumflex branch of the left coronary artery (type V, 6.5%). CONCLUSIONS. Our study provides data on the morphology and variations of the AVNb. Such information can assist in better diagnoses based on imaging, better guide invasive procedures, and provide the cardiac surgeon an improved method of classifying the AVNb and its branches during procedures of the coronary arteries and their branches.

*BAUM, Michael M.^{1,3}, Ashley DAVIDOFF², and Jonathan J. WISCO³. ¹Margolin Hebrew Academy/Feinstone Yeshiva of the South, Memphis, TN, 38117, USA; ²Department of Radiology, Boston University School of Medicine, Boston, MA, 021182, USA; ³Department of Anatomy and Neurobiology, Boston University School of Medicine, Boston, MA, 021183, USA.
Novel Computational Methods for Mediastinal Structure Assessment to Aid in COPD Diagnosis.

INTRODUCTION. Chronic obstructive pulmonary disease (COPD) commonly presents with hyperinflated lungs associated with changes in the shape or size of adjacent mediastinal structures such as the “saber- sheath trachea.” We wish to investigate this change in the trachea and other possible markers of emphysema, including thinning and orientation changes of the posterior and anterior junction lines, flattening of the right lateral atrial and ventricular walls, and flattening of the hemidiaphragm. Others who have investigated the relationship between posterior junction line thinning and emphysema reported a weak correlation with low statistical power. In consideration of this, it may be possible to evaluate a “fingerprint” or constellation of metrics that together are diagnostic. METHODS. The aforementioned structural changes in COPD were computationally segmented and measured from axial computed tomography scans of the chest from 2 subjects in an automated or semi-automated fashion. All segmentations and most measurements were performed using the Scikit-image library, a collection of algorithms for Python image processing. We used Multi-Otsu thresholding for the segmentation of the trachea and hemidiaphragm and Li thresholding for the segmentation of all other structures. SUMMARY. The “fingerprint” metrics extracted from the segmented structures include area, eccentricity, perimeter, minor and major axis lengths, equivalent diameter, distance from the center of the image, and centroid location. CONCLUSIONS. Our segmented fingerprint of metrics offers a promising diagnostic workflow for radiologists. Next steps involve applying our pipeline to a clinical sample of subjects.

*HUSAIN, Tooba S.¹, Courtney A. MILLER¹, Ashley T. STEELE¹, Lauren A. GONZALES¹, Emma K. HANDLER¹, Jason M. ORGAN², and Rachel A. MENEGAZ¹. ¹Department of Anatomy and Physiology, University of North Texas Health Science Center, Fort Worth, TX, 76107, USA; ²Department of Anatomy, Cell Biology & Physiology, Indiana University School of Medicine, Indianapolis, IN, 46202, USA.
Neurocranial Growth in the OIM Mouse Model of Osteogenesis Imperfecta.

INTRODUCTION. Osteogenesis imperfecta (OI) is a type I collagen disorder characterized by increased bone fragility. Patients with severe OI may have macrocephaly, altered cranial base morphology, and midfacial underdevelopment. METHODS. We used the osteogenesis imperfecta murine (OIM or B6C3FE a/a-Col1a2/J), a severe type III OI model in humans, and unaffected wild-type (WT) littermates. Mice were imaged using in vivo microCT at juvenile (week 4) and adult (week 16) stages. 3D slicer software was used to quantify cranial base angle (CBA) and endocast volume (brain size proxy). Cranial landmarks were used to calculate centroid size. Mann-Whitney U tests were used to compare measurements between genotypes. SUMMARY. Both juvenile ($p=0.008$) and adult ($p=0.003$) OIM mice had absolutely smaller brains than WT mice. OIM mice do have significantly smaller default cranial centroid sizes compared to WT mice ($p=0.003$, $p<0.001$). When scaled to cranial size, juvenile mice had relatively larger brain volumes ($p=0.016$) but adult OIM relative brain volumes were not significantly different from WT. No significant difference was seen in CBA at the juvenile ($p=0.065$) or adult ($p=0.171$) stages, but a trend was observed for decreased CBA at the adult stage. CONCLUSIONS. Neurocranial dysmorphologies in OI may be more severe at earlier stages of postnatal development. Previous studies showed relative macrocephaly in juvenile and adult mice, but here we show an increase in relative endocranial volume only at the juvenile stage. A reduction in CBA during growth, possibly due to platybasia, may underlie this decoupling between external

continued on next page

Abstracts - Platform Presentations continued

and internal cranial morphology. A better understanding of the integration and growth of the neurocranium is vital for formulating treatments to manage basicranial instabilities in patients with OI. (Funding was provided by an Indiana University Collaborative Research Grant, Ralph W. and Grace Showalter Trust, and a UNTHSC Physiology & Anatomy SEED Grant.)

*WATANABE, Koichi¹, Eiko INOUE¹, Aya HAN¹, Yoko TABIRA¹, Akihiro YAMASHITA¹, Keishirou KIKUCHI¹, Yuto HAIKATA¹, Kunimitsu NOOMA¹, Joe IWANAGA², and Tsuyoshi SAGA³. ¹Division of Gross and Clinical Anatomy, Department of Anatomy, Kurume University School of Medicine, Kurume, Fukuoka, 830-0011, Japan; ²Department of Neurosurgery, Tulane University, New Orleans, LA, 70118, USA; ³Domain of Anatomy, Kurume University School of Nursing, Kurume, Fukuoka, 830-0011, Japan.

Observation of the Superficial Musculoaponeurotic System by the Stretched Tissue Dissection Method.

INTRODUCTION. The presence of the superficial musculoaponeurotic system (SMAS) is advocated in the field of facelift surgery, and this tissue is familiar to plastic surgeons. However, the detailed characteristics of this fascia are still not widely known among anatomists. We used a newly developed anatomical dissection method to observe the details of the SMAS. **METHODS.** Ten hemi-facial soft tissues with bones were obtained from formalin-preserved cadavers. Among them, five tissues were used to create horizontal slices parallel to the orbitomeatal line, and five residual tissues were used to create slices parallel to the longitudinal axis of the head (coronal slices in the lateral region and sagittal slices in the frontal region). The tissues were fixed on black rubber plates by driving pins into the bony parts and stretched outward by pulling strings fixed to the skin at approximately every 1 cm. The facial spaces composed of loose connective tissue were expanded by this treatment. The fat lobes were then carefully removed under magnification to clarify the fibrous structures. **SUMMARY.** The structures composing the SMAS, including the superficial temporal fascia, parotid fascia, platysma, frontal muscle, and orbicularis oculi muscle, were clearly observed. These structures showed no obvious continuity as a single sheet-like layer; however, all of them formed the deep border of the superficial subcutaneous fat, which contains the fibrous septa (retinacula cutis). We also observed the fibrous zones on the zygomatic arch and orbital border, and some fibers arose from the periosteum and inserted into the dermis. **CONCLUSIONS.** This method fills the gap between gross anatomical dissection and observation by a light microscopy. We expect that the results of this research will lead to improvement of surgical and other treatments of the face. (Sponsored by Grant No. 21K06744 from the Grants-in-Aid for Scientific Research (KAKENHI) in Japan)

PLATFORM SESSION 4

*STRATTON, Paige A., Makayla GOLOGRAM, and Mark TERRELL. Division of Anatomy, College of Medicine, Lake Erie College of Osteopathic Medicine, Erie, PA 16509, USA.

Anatomical Outreach Education of Clitoroplasty after Female Genital Mutilation.

INTRODUCTION. Female genital mutilation (FGM) is the intentional destruction of female genitalia performed by non-medical providers in many regions of Africa, the Middle East, and Asia. This unfortunate, but prevalent practice has an estimated incidence of at least 200 million women and girls worldwide. The practice of FGM is mainly motivated by religious and societal norms to prevent premarital sex and protect marital fidelity. Removal or damage to the clitoris disables women from being sexually aroused by touch, decreases libido and vaginal lubrication, and harms self-esteem and self-image. **RESOURCES.** A critical interpretive synthesis of the literature was performed to produce a detailed anatomical description of the clitoroplasty (CP) surgical procedure and repair of the associated anatomy after FGM. **DESCRIPTION.** The World Health Organization (WHO) has classified FGM into four major categories based on the extent of removal of glans clitoris and surrounding tissues. Variations in CP are based upon the clitoral stump, erectile tissue remaining, and presence of a vaginal seal. By understanding the basic anatomy of the female perineum and erectile structures, as well as known anatomic variants of the musculature and neurovascular structure, CP can be successfully performed. The psychological aspect of the surgery appeals to many women affected by FGM when trying to find their sexual identity and rebuild femininity. **SIGNIFICANCE.** Educating FGM patients of their options for clitoral reconstruction and improving their understanding of the procedure can increase the acceptance of this rare form of surgery, changing the lives of women who have endured FGM.

*ROBERTSON, Taylor C.¹, Cara L. FISHER¹, Emma K. HANDLER¹, and Daniel NASH². ¹Department of Physiology and Anatomy, University of North Texas Health Science Center, Fort Worth, TX, 76107, USA; ²St. Anthony's Bone and Joint Hospital, Oklahoma City, OK, 73103, USA.

Manipulating Anesthesia with Massage Increases Spread in Sciatic Nerve Blocks: A Cadaver Study.

INTRODUCTION. Sciatic nerve blocks are essential for surgical treatment of various lower limb pathologies. Due to the complexity and variation of anatomical landmarks, ultrasound (US) guided injection of local anesthesia has become common practice. In patients with thicker thigh girth (i.e., obese patients) excess tissue may distort US penetration thereby diminishing efficacy of the nerve block and/or cause severe post-operative pain. Dye tracing techniques have been used

continued on next page

Abstracts - Platform Presentations continued

to test the effectiveness of nerve blocks, but there is little research on using massage to manipulate anesthetic spread. Therefore, the aim of this study is to assess the effects of massage to manipulate local anesthesia spread in sciatic nerve blocks. We hypothesize massaging after injection will increase the spread of local anesthesia compared to non-massage post injection. **METHODS.** Forty un-fixed cadaveric legs were injected with a mixture of methylene blue dye and 2% Lidocaine Hydrochloride. Specimens were divided into non-massage (control) (n=20) and massage (n=20) groups. Sciatic nerve blocks were performed by a nurse anesthetist using US guidance at the popliteal fossa traveling proximally until the sciatic nerve was identified and the location was tagged. Immediately following, massage group specimens received five repeated proximally directed massages with the US transducer head. Specimens from both groups were then dissected to expose the sciatic nerve. Measurements of the distance traveled from marked site of injection to proximal end of dyed area were measured and compared. **SUMMARY.** Spread of local anesthesia in the inferior-superior direction was significantly higher in the massage group than the control group ($p \leq 0.05$). **CONCLUSION.:** Massaging post-injection caused a greater spread of local anesthesia during sciatic nerve block. Sciatic nerve block techniques often utilize nerve stimulation to identify the sciatic nerve location. This may be due to lack of US penetration through the gluteus maximus muscle. In patients with thicker thigh girth due to subcutaneous fat, imaging visibility may be more difficult as well. Our findings suggest that clinicians may block the sciatic nerve at a more distal location with US guidance and manipulate the anesthesia to the region of interest.

*RASTELLINI Cristiana¹, Anaas HASSAN², Natalie CLOSE², John MOTH², Carolyn MCCROSSAN², Pietro Antonio CICALI³, and Luca CICALI⁴. ¹Department of Neuroscience, Cell Biology and Anatomy, University of Texas Medical Branch, Galveston, TX, 77555, USA; ²School of Medicine, University of Texas Medical Branch, Galveston, TX, 77555, USA; ³Biomedical Engineering, University of Houston, Houston, TX, 77004, USA; ⁴Department of Surgery, University of Texas Medical Branch, Galveston, TX, 77555, USA.

The Anatomy of the Femoral Triangle: Gender Differences and Possible Clinical Implications.

INTRODUCTION. The femoral triangle is a sub-fascial space that presents as a triangular depression on the antero-superior thigh, inferior to the inguinal ligament. The borders of the femoral triangle are composed of the inguinal ligament superiorly, the adductor longus muscle medially, and the sartorius muscle laterally. The content of the femoral triangle includes the femoral nerve, artery, vein, and lymphatics. Among pathologic conditions affecting the femoral triangle, some seem to be more common in females when compared to males (i.e., femoral hernia). This could suggest that anatomical differences exist among genders. In this study, we investigated the relationship between the femoral triangle area and the femoral vein diameter in males and females, hypothesizing that differences could be responsible for the female predisposition to varicose vein disease. **METHODS.** Through careful dissection, the anatomical components of the femoral triangle were exposed bilaterally in 93 cadavers (45 males (M) and 48 females (F)). Donor average age (years) at death was 73 (SD:15) in M and 79 (SD:12) in F. Following established guidelines, measurement of the three sides of the femoral triangle (in millimeters, mm) was taken by six independent operators. Due to technical issues, some triangles could not be considered. Given the sides, the surface area of 178 femoral triangles was calculated (87 M and 91 F). The ratio between the femoral triangle area and the average diameter of the femoral vein (as reported in the literature, in M=12.90 mm and in F=11.22 mm) was calculated and compared. Statistical analyses were performed using the Student's t-test (P value <0.05). **SUMMARY.** As expected, surface area of the femoral triangles measured was smaller in the female bodies as compared to the male bodies. The ratio between the femoral triangle area and the femoral vein diameter was 13.8 (SD:2.1) in males and 9.1 (SD:1.5) in females (statistically significant). **CONCLUSIONS.** Space within the femoral triangle allows the femoral vein to dilate when needed. A lower ratio (femoral triangle area over femoral vein diameter) may be an indicator of limited space for the vein to dilate in females vs. males. This new observation should be further investigated as it could constitute a new approach in preventing and/or treating varicose vein disease.

Abstracts – Poster Presentations

* Accepted for Electronic Publication in *Clinical Anatomy*
(Listed by presenting author last name)

POSTER SESSION 1

79 AHN, Haeryun, Soo-Bin KIM, You-Jin CHOI, Kyung-Seok HU, and Hee-Jin KIM. Department in Anatomy and Developmental Biology, Department of Oral Biology, Human Identification Research Institute, BK21 FOUR Project, Yonsei University College of Dentistry, Seoul, 03733, South Korea.
Anatomical Evidence of the Bunny Lines Formation.

INTRODUCTION. Common clinical procedure of bunny lines is to inject botulinum toxin into on-site of the bunny lines is formed. According to previous cadaveric studies, it was quite difficult to identify the muscular structures between medial canthus to side of nose. Therefore, the current study tried to determine the relationship between the bunny lines and anatomical structures by using ultrasonography (US) on volunteers. METHODS. 13 Korean adults volunteered (6 females and 7 males, mean age 29.4) for the study using US. US images were scanned on the lateral side of the nose, from the radix to the nose ala based on the reference points (sellion, rhinion, and nose ala). SUMMARY. The findings of the current study showed that triangular bare area (bunny triangle) between the lateral border of the procerus and nasalis, and the levator labii superioris alaeque nasi (LLSAN) muscle. On the bunny triangle, there was no muscular structures, and the size of the triangle were determined according to the width of procerus muscle. The current study determined the anatomical structures beneath the bunny lines. The neighbouring muscles of the bunny lines such as, the procerus and nasalis muscle has effect on creasing the thin skin between the medial canthus and the dorsum of nose. CONCLUSIONS. Thus, the conventional botulinum toxin injection for bunny lines lacks anatomical evidence. Injection into on-site of the bunny lines is not targeting the muscle but only connective tissues in which, cannot bring the best results as it is expected. Therefore, the most efficient botulinum toxin injection targeting muscles would be procerus, nasalis muscles and LLSAN.

67 *BALENTINE, Lauren A. Tulane University School of Medicine, New Orleans, LA, 70112, USA.
Clinical Anatomy Research Productivity: A Bibliometric Analysis of the Past Two Decades (2000-2020).

INTRODUCTION. The relationship between anatomical research and clinical practice is symbiotic. The objective of this study was to discover and analyze the global research efforts in clinical anatomy in the past twenty years (2000-2020) using bibliometric analysis. METHODS. The term “clinical anatomy” was used as the topic for Web of Science Core Collection. For PubMed, the MeSH terms “clinical medicine” and “anatomy” with MeSH subheading “anatomy and histology” were used in conjunction with Title/Abstract and Keyword search for “clinical anatomy.” SUMMARY. 3724 articles from Web of Science and 4371 from PubMed were retrieved. After eliminating duplicates and limiting time interval, 2213 articles were selected for in-depth analysis. Journals with the most publications were evaluated and ranked according to impact factor (IF), referencing the Journal Citation Report database. Top publishing journals include Clinical Anatomy, Cureus, Surgical and Radiological Anatomy. Top 5 Web of Science Categories from the results include surgery, radiology and medical imaging, clinical neurology, cardiovascular systems, orthopedics, and neurosciences. Top 5 countries or regions represented were United States, England, Italy, Germany, and Canada. CONCLUSIONS. The search strategy employed observed the overall impressions that clinical anatomy research has made in the field. As evidence-based strategies for advancements in clinical practice & surgery expand, these kinds of research impact analyses may prove useful to find topics of interest or to connect with prolific authors.

58 *BARTON¹, Scott, Fidelis CHIBHABHA², and Brandi SCHMITT³. ¹Medical Education Department, UC San Diego School of Medicine, La Jolla, CA, 92093, USA; ²Department of Anatomy, Midlands State University, Gweru, Midlands, 00000, Zimbabwe; ³University of California Health, UC Office of the President, Oakland, CA, 92067, USA.
Sharing the University of California Anatomical Donation Program Experience with a Fulbright Scholar.

INTRODUCTION. The University of California continued its commitment to sharing its’ experiences of managing a transparent and successful whole body donation program, reflecting operational best practices, by hosting a Fulbright research scholar from Zimbabwe. The goal of this experience was to share knowledge enabling him to develop a national whole body donation program utilizing and emulating best practices learned from UC body donation programs. RESOURCES. The University of California Health division provided subject matter expertise and the UC San Diego School of Medicine and Anatomical Services program provided space, equipment and operational experiences for the invited Fulbright scholar. Additionally, Anatomical Donations Programs at UC Davis, UC Irvine, UCLA and UC San Francisco were active participants in providing

continued on next page

Abstracts - Poster Presentations continued

feedback and operational recommendations. DESCRIPTION. Supported by the Fulbright research grant and Midlands State University in Zimbabwe, the scholar engaged in research activities including data gathering, site visits and informational interviews of academic body donation programs in California and the United States. Regulatory comparisons were made between the relevant laws in the US and Zimbabwe with state level modifications and institutional policies also included for analysis. SIGNIFICANCE. The development of a national body donation program in Zimbabwe would change the paradigm of how medical education is delivered in that country and region.

76 BASSETT, Cameron C.¹, Kerry K. GILBERT², Micah LIERLY², Troy L. HOOPER², and Roger JAMES². ¹Doctor of Physical Therapy Program at DeSales University, Center Valley, PA, 18034, USA; ²Clinical Anatomical Research Laboratory of the Institute of Anatomical Sciences in the Department of Rehabilitation Sciences, Texas Tech University Health Sciences Center, Lubbock, TX, 79430, USA.

Shear Wave Elastography Measured Differences between Unembalmed and Embalmed Knee Tissue Stiffness.

INTRODUCTION. Cadavers are valuable resources for education, research, and clinical simulation, however, there is no quantitative data to compare cadaver tissue stiffness relative to the embalming condition. This research provides recommendations for unembalmed and embalmed cadaver use based on quantitative in situ tissue stiffness using shear wave elastography (SWE). METHODS. Tissue stiffness values of the patellar tendon (PT), vastus medialis oblique (VMO), and superficial medial collateral ligament (sMCL) were measured in 10 cadavers (5 unembalmed and 5 embalmed) using SWE at five and 20° of knee flexion. Intrarater reliability was analyzed using the intraclass correlation coefficient (ICC (3, 3)). The SWE data of the embalmed conditions and knee flexion angles were analyzed using a two-way mixed ANOVA. SUMMARY. Good intrarater reliability measures found for the PT (ICC (3, 3) = 0.969), VMO (ICC (3, 3) = 0.976), and sMCL (ICC (3, 3) = 0.826). Tissue stiffness measurements were significantly different between embalming conditions for the PT and VMO (PT $p < 0.001$; VMO $p = 0.008$), but sMCL data is inconclusive. There were no significant tissue stiffness differences between five and 20° of knee flexion (PT $p=0.473$; VMO $p=0.598$; sMCL $p=0.348$). CONCLUSIONS. The SWE reliably measured cadaveric tissue stiffness and found greater stiffness values in embalmed cadaver tissues for the PT and VMO. Tissue stiffness does not appear to change between five and 20° of knee flexion. Based on tissue behavior, embalmed cadavers are recommended for educational study and unembalmed cadavers are recommended for research and clinical simulation.

25 *BRICKER, Airada D. and Jennifer K. BRUECKNER-COLLINS. Department of Anatomical Sciences and Neurobiology, University of Louisville School of Medicine, Louisville, KY, 40202, USA.

Implications of a Growth Versus a Fixed Mindset in the Gross Anatomy Laboratory Experience.

INTRODUCTION. Academic and personal setbacks are an inevitable part of the medical anatomy lab dissection experience. The mindset with which students approach such challenges may be influenced by their beliefs about the nature of key personal attributes as being malleable or fixed. The entity theory is the belief that the quality in question is fixed while incremental theory (growth mindset) is the belief that the quality in question can be cultivated through effort. METHODS. As part of an anatomy lab course assignment, 157 first year medical students at the University of Louisville completed a brief 10 item instrument evaluating fixed versus growth mindset at midterm. This instrument provided feedback as to whether the student demonstrated a strong growth mindset, growth with some fixed ideas, fixed with some growth ideas or a strong fixed mindset. In addition, students were asked to self-reflect and identify a significant area for personal growth in the anatomy lab experience at midterm, along with plans for how to address this issue. Thematic analysis was performed to evaluate any trends for each category of growth and fixed mindset. SUMMARY. The mean class score on the growth mindset survey was in the strong growth mindset category. Seventy six percent of the class scored in the strong growth mindset category, while 21% held growth mindset with some fixed ideas and 3% held a fixed mindset with some growth ideas. Students with a strong growth mindset predominantly identified dissection/kinesthetic skills as their area for growth. Students with a growth mindset with some fixed ideas and those with a fixed mindset with some growth ideas largely identified anatomical knowledge as their area for growth in the laboratory setting. CONCLUSIONS. Student knowledge of and self-reflection on their position on the growth versus fixed mindset scale provides meaningful opportunities for academic and personal growth and awareness.

Abstracts - Poster Presentations continued

28 *CAMPISI, Emma S.¹, John TRAN¹, Catherine AMARA², Sharon SWITZER-MCINTYRE³, Anne M. R. AGUR¹. ¹Division of Anatomy, Department of Surgery, Temerty Faculty of Medicine, University of Toronto, Toronto, ON, M5S 1A8, Canada; ² Faculty of Kinesiology and Physical Education, University of Toronto, Toronto, ON, M5S 2W6, Canada; ³Department of Physical Therapy, Temerty Faculty of Medicine, University of Toronto, Toronto, ON, M5G 1V7, Canada.
A Comparison of Flexor Digitorum Superficialis and Flexor Digitorum Profundus Contributions to Grasp.

INTRODUCTION. Flexor digitorum superficialis (FDS) and flexor digitorum profundus (FDP) are essential for grasp/fine motor skills. Following injury, balanced function of the digital bellies of FDS/FDP is difficult to restore and requires knowledge of muscle architecture. Literature of FDS/FDP function is scarce, limiting understanding of their relative contributions to wrist/digital movements. The purpose was to compare morphology, fiber bundle length (FBL), and physiological cross-sectional area (PCSA) of FDS/FDP to elucidate their relative excursion/force generating capabilities. METHODS. In 10 FDS and 7 FDP specimens (mean age 79.0±10.0yrs), fiber bundles/aponeuroses were dissected, digitized, and modelled. The 3D morphology, mean FBL and PCSA of the digital bellies of FDS/FDP were compared to determine relative excursion/force generating capabilities. SUMMARY. The FDS consisted of 4 digital and 1 proximal belly; FDP consisted of 4 digital bellies. In both, the mean FBL of the digital bellies from longest to shortest were 3rd, 4th, 5th, and 2nd. The mean FBL of the 2nd and 5th bellies of FDS were 23mm and 26mm less than the 2nd and 5th bellies of FDP, respectively. The 2nd, 4th and 5th digital bellies of FDP had greater mean PCSA than that of FDS whereas the 3rd belly of FDS had greater mean PCSA than FDP. The mean PCSA of the 5th FDP belly was statistically greater than FDS (p=0.00). CONCLUSIONS. The 3rd digital belly of FDS and FDP have the greatest excursion capability. The proximal belly of FDS is in series with the 2nd/5th bellies through their attachment to a common aponeurosis.

Contraction of the proximal belly may play a major role in wrist flexion of FDS, with isolated contraction of the digital bellies alone resulting primarily in digital flexion. The 3rd FDS belly and the 2nd FDP belly have the greatest force generation capability. Function of the bellies of FDS/FDP require further in vivo study to determine their role in grasp and fine motor skills.

31 *CURRY, Hannah M.¹, Cassidy S. FIX¹, Tommy R. WRIGHT¹, Cara L. FISHER², and William F. PIENKA II³. ¹Texas College of Osteopathic Medicine, University of North Texas Health Science Center, Fort Worth, TX, 76107, USA; ²Center for Anatomical Sciences, University of North Texas Health Science Center, Fort Worth, TX, 76107, USA; ³Department of Orthopaedic Surgery, John Peter Smith Hospital, Fort Worth, TX, 76107, USA.
Investigating the Potential for Using the Gantzer Muscle Tendon in Reconstructive Hand Surgery.

INTRODUCTION. The Gantzer muscle is a small muscle found in the forearm that is not commonly recognized and does not commonly appear in any major anatomic textbooks. The literature has just recently begun to determine the prevalence of this muscle and its relationship to the anterior interosseous nerve. The purpose of this project is to investigate the prevalence of this muscle, as well as the length and diameter of the tendon to determine its possible utility as a free tendon graft for reconstructive hand surgery. METHODS. 29 embalmed and fresh frozen cadaver forearm pairs (n=58) were dissected by removing the skin and superficial fascia. The muscles of the forearm were then separated to look for the Gantzer muscle between the flexor digitorum superficialis (FDS) and flexor digitorum profundus (FDP) muscles. Information was recorded on the presence of the Gantzer muscle in the left and right forearms, its proximal and distal attachments, its relationship with the AIN, and sex and age of the cadaver. Using a digital caliper, the muscle tendon length and diameter will be recorded. SUMMARY. The average age of the cadaveric specimens was 69.87 years. 17 (58.62%) were male. The Gantzer muscle was present in 17 right forearms (58.62%) and 19 right forearms (65.52%). The Gantzer muscle was identified in a total of 36 specimens (62.07%). 23 cadavers (79.31%) showed the presence of the Gantzer muscle in at least one forearm. The Gantzer muscle was present in 10 cadavers unilaterally (34.48%) and 13 bilaterally (44.83%). It was absent bilaterally in 6 pairs (20.69%). The most common attachment sites were the deep surface of FDS proximally and flexor pollicis longus distally. The AIN most commonly passed deep to the belly of the Gantzer muscle. CONCLUSIONS. The findings of this study thus far show that the Gantzer muscle is present in a large majority of the population and could potentially be used as a free graft tendon for hand reconstruction while creating little to no functional deficit.

Abstracts - Poster Presentations continued

10 *FRITSCH, Alexa R., Abigail L. LIMOV, and Nena LUNDGREEN MASON. Department of Clinical Anatomy and Osteopathic Principles and Practice, Rocky Vista University College of Osteopathic Medicine-Southern Utah, 255 E. Center Street, Ivins, UT 84738, USA.

Case Study: Identification and Analysis of a Suprahepatic Gallbladder in a Cadaver.

INTRODUCTION. Ectopic gallbladders are largely categorized by location, which can include retrohepatic, intrahepatic, left-sided, floating, transverse, and suprahepatic. Of these, the suprahepatic location is exceedingly uncommon and comprises only 0.026%-0.7% of the population. The cause of this irregular positioning is unclear, but several studies have illustrated its association with atrophy, congenital agenesis, and hypoplasia of the right lobe of the liver. Most patients with a known suprahepatic gallbladder complained of right upper quadrant pain presumably due to bile stasis, atypical gallbladder emptying, and cholelithiasis. Other patients were asymptomatic with an ectopic gallbladder incidentally discovered on imaging. **RESOURCES.** A 56-year-old female cadaver with a suprahepatic gallbladder and a history of alcoholism, who passed due to a myocardial infarction (MI). **DESCRIPTION.** Several incisions of the anterior abdominal wall were made to gain access to the abdominal cavity. The peritoneal organs were inspected prior to removal via blunt and/or scalpel dissection. While retracting the anterior portion of the diaphragm superiorly over the liver, a suprahepatic gallbladder was recognized. **SIGNIFICANCE.** Noting various anatomical findings (e.g. liver measurements and gross characteristics, biliary tree measurements and branching, additional ectopic organs, gallbladder shape and septations, choleliths, etc.) and relationships can lead to a better understanding of the biological organization that is conducive to a suprahepatic gallbladder. To date, no cadaveric anatomic structural analysis of an ectopic gallbladder situated above the liver has been reported in the literature.

13 *GONZALEZ, Brandon, and Keith KERR. College of Medicine, University of Houston, Houston, TX, 77004, USA.

The Retrosigmoid Approach to the Cerebellopontine Angle.

INTRODUCTION. The retrosigmoid approach is used to access the cerebellopontine angle (CPA). Indications for use of the retrosigmoid approach include microvascular decompressions and resection of vascular lesions and tumors of the posterior fossa. Becoming familiar with the neuroanatomical correlates, clinical presentation of CPA lesions, and surgical technique of the retrosigmoid approach is of educational importance to medical students and residents alike. **RESOURCES.** Using a case-based approach, we describe the retrosigmoid approach to the CPA, focusing attention to the soft tissues, cranial landmarks, and intracranial neuroanatomical structures. We review the medical record and discuss the clinical presentation and pre-operative radiographic and intra-operative images of a 38-year-old female patient presenting with a meningioma of the anterior portion of the right petrous ridge (ICD- 10-CM D32.0). **DESCRIPTION.** We present an overview of patient positioning, location of extracranial landmarks, and intra-operative surgical management, including incision and craniotomy, dissection of the dura mater, neurovascular structures accessed within the CPA, tumor resection, replacement of the skull flap, and closure of the incision. Post-operative follow-up care and surgical sequelae are briefly discussed. **SIGNIFICANCE.** A description of the retrosigmoid approach targeted to the medical student and resident facilitates the acquisition of neuroanatomical knowledge and its application to patient care. Furthermore, a case-based approach is utilized more frequently in medical education, which emphasizes case- and problem-based learning as ways for learners to integrate basic and clinical sciences and become efficient and effective problem solvers.

55 *HINES, Jonathon H., Aubrey L. COVINGTON, and Amberly M. REYNOLDS. Department of Clinical Anatomy, Sam Houston State University College of Osteopathic Medicine, Conroe, TX 77304, USA.

Analysis of Study Skills Utilized by Osteopathic Medical Students for Clinical Anatomy.

INTRODUCTION. The number of resources and teaching modalities available to medical students for learning clinical anatomy continues to grow, and students tend to gravitate toward certain resources in particular. The goal of this research is to anonymously interview first-year osteopathic medical students at Sam Houston State University College of Osteopathic Medicine to determine which resources were most used and subsequently correlate those findings with course performance. **RESOURCES.** After completing two courses of clinical anatomy didactics and its corresponding lab, osteopathic medical students were invited to voluntarily participate in an anonymous interview conducted by a graduate student from a separate campus. Interviews consisted of standardized open-ended questions designed to direct students to discuss the resources they used and their study strategies. Audio recordings of interviews were transcribed to maintain anonymity, and a codebook was created to identify common resources and strategies among students. Official themes have not been designated yet as the final analysis has not been complete, but trends can already be identified. **DESCRIPTION.** The study strategies the were most prominently discussed by students were creating drawings, notecards and Anki cards, flowcharts, and mnemonics. Students also found peer teaching helpful and relied heavily on instructor slides. Trends for most used resources included use of First Aid, Boards and Beyond, practice practicals, open lab time, and Embryo Hour (instructor-led hour guiding students through embryological development). Trends for the least used resources were study groups, dissector manuals, and VH Virtual Dissector. **SIGNIFICANCE.** Picking the best resource is vital to student performance, and this research aims to help educators discover which ones led to top student performance. Results will help provide a framework for future students as they decide which resource and strategy will lead to academic success.

continued on next page

Abstracts - Poster Presentations continued

64 *HUNTER, Shelley D.¹, Brandt J. WISKUR², Mary B. MOON³, and Nancy L. HALLIDAY³. ¹School of Nursing and Health Studies, University of Missouri-Kansas City, Kansas City, MO, 64108, USA.; ²Office of Institutional Research, University of Oklahoma Health Sciences Center, Oklahoma City, OK, 73117, USA.; ³Department of Cell Biology, College of Medicine, University of Oklahoma Health Sciences Center, Oklahoma City, OK, 73126, USA.
Clinical Anatomy Remote Learning: A Mixed Methods Study of Actual and Perceived Knowledge.

INTRODUCTION. The COVID-19 pandemic forced academic institutions fully online in March of 2020. At the University of Oklahoma Health Sciences Center, anatomy faculty prepared for remote delivery of the Clinical Anatomy curriculum for newly matriculating dental and PA students. Faculty created dissection videos and synchronous lesson plans for lecture and laboratory video review sessions. Two purposes of this research were to assess academic outcomes and survey student perspectives of remote Clinical Anatomy. A third purpose was to determine relationships between outcomes and perceptions. METHODS. Summative and formative assessment items were compared between a 2020 remote and a historical 2019 face-to-face cohort. For the 2020 remote cohort, a survey was developed to assess student perspectives of anatomical knowledge (IRB #12937). SUMMARY. Results indicated an increase in academic outcomes for the 2020 remote cohort. Remote students reported adequate cognitive domain gains in anatomical knowledge, but many perceived a lack of psychomotor and affective domain learning as a lost opportunity. CONCLUSIONS. Anatomy educators should seek online teaching pedagogies that support different modalities of student learning, and administrators need to consider student learning needs beyond the cognitive domain in order to promote teaching methods that develop professionalism and non-traditional discipline-independent skills (NTDIS).

37 *IMMONEN, Jessica A., Jason CICCOTELLI, Landen BROADHEAD, Mackenzie KITCHEN, and Conner PAUL. University of Nevada Las Vegas, Las Vegas, NV, 89106, USA.
Osteoarthritis Disease Severity in a Pilot Cohort of Temporomandibular Joints.

INTRODUCTION. The objective of this study was to determine the level of disease severity in a pilot cohort of temporomandibular joints (TMJs). A validated scale for disease severity of osteoarthritis (OA) in the knee joint was utilized to interpret disease severity in the TMJs. RESOURCES. Thirteen intact TMJs from 8 cadaveric donors were harvested from skull dissections with the calvaria and brain removed. DESCRIPTION. Specific types of lesioning seen in arthritic knee joint cartilage were investigated on the condyle of the mandible and the mandibular fossa of the temporal bone using a validated, OA disease scale. It was determined that superficial pitting was the most common form of degeneration in donors with mild TMJ OA in this population. Donors demonstrating severe TMJ OA demonstrated cartilage loss and cortical bone exposure. The mandibular fossa was more prone to demonstrate OA pitting symptoms (58%) and cartilage loss (46%) compared to the condyle (38%, 23%). The pathology demonstrated in the TMJs of this population did not include notable stellate fractures, pathology commonly demonstrated in arthritic knee joints. A case study was carried out on a donor that demonstrated severe OA in the knee joint and TMJ. Similar articular cartilage and fibrocartilage disease symptoms presented on the two joints highlighting the systemic nature of OA. SIGNIFICANCE. This study demonstrates for the first time that gross symptoms of OA in the TMJs of cadavers are comparable to pathology found in the knee. Given the validated scale does not specifically address stellate fractures as a specific requirement to be classed as a 0-4 Grade it is concluded that this scale for OA disease severity could be effectively used to class disease in arthritic TMJs. The mandibular fossa appears to be the site of more profound disease, implying the translational movements of the TMJ may be more likely to induce biomechanically abnormal movement, loading and OA.

7 *JOHNSON, Benjamin G.¹, Omid B. RAHIMI², and Annette OCCHIALINI². ¹Joe R & Teresa Lozano Long School of Medicine, University of Texas Health Science Center San Antonio, San Antonio, TX, 78229, USA; ²Cell Systems & Anatomy, University of Texas Health Science Center San Antonio, San Antonio, TX, 78229, USA.
Effects of Severe Scoliosis on Internal Thoracic and Abdominal Anatomical Structures: A Case Study.

INTRODUCTION. In the US, scoliosis results in over 600,000 office visits and 38,000 spinal fusion surgeries annually with a complication rate of 44%. Despite this, visceral anatomical variations due to altered skeletal structures in patients with severe scoliosis have not been well described. RESOURCES. During a cadaveric dissection, a female 84-year-old body donor had marked lateral and kyphotic curvatures of the thoracic spine with compensatory curvature into the lumbar region. The estimated Cobb angle was greater than 70 degrees with severe deformity of the thoracic cage. Intrathoracic changes included collapse of the left lung, marked deviation of the descending aorta, and severe axial rotation of the heart; the right atrium was the most anterior chamber. In addition to the expected deviation of the descending thoracic aorta, the inferior vena cava and esophagus passed through the diaphragm to the right of midline while intraperitoneal structures such as the stomach and spleen were displaced superiorly and retro cardiac. The liver was more anteriorly and inferiorly displaced than normal. DESCRIPTION. The authors describe a case of severe scoliosis with significant thoraco-abdominal visceral displacement. SIGNIFICANCE. While the etiology of scoliosis is not well understood, clinicians must keep in mind the

Abstracts - Poster Presentations continued

compensatory visceral changes that occur. The thoracic artery displacement is readily intuited but the additional torsional forces placed on other intrathoracic structures such as the heart are less predictable. This visceral displacement can alter the presentation of many common diseases. For example, with the inferior displacement of the liver, biliary colic would present with right lower quadrant pain. Heart sounds in such a patient as this would be radically altered from standard expectations. The change in the relative placement of these structures demonstrates the need for thorough evaluation of scoliosis patients before medical or surgical intervention.

70 *KELLY, Alexa P., and Scott D. MADDUX. Center for Anatomical Sciences, University of North Texas Health Science Center, Fort Worth, TX, 76107, USA.

Nasal Morphology and Energetic Demands: A Test of the Respiratory-Energetics Hypothesis.

INTRODUCTION. Anthropologists have long attributed geographically-patterned variation in human nasal anatomy to climatic adaptation. This assertion is largely based on the primary role of the nasal complex in heating and humidifying inspired air prior to its entry into the lungs. However, previous studies have also demonstrated sexual dimorphism in overall nasal size, with larger nasal passages in males hypothesized to reflect greater volumetric demands for oxygen intake due to higher metabolic requirements. To test this “respiratory-energetics” hypothesis, we assessed adult nasal variation in conjunction with associated body mass/basal metabolic rate data derived from 21 modern human skeletons from France. **METHODS.** Sixty-six 3D-coordinate landmarks were collected from CT scans of each crania, while associated postcranial measurements were manually collected from skeletal elements. Body mass and climate-specific basal metabolic rate (BMR) estimates were calculated for each individual utilizing Ruff et al. 1991 and Froehle 2008 formulae. Multivariate regression analyses of nasal size and shape on metabolic measures were performed using the MorphoJ software package. **SUMMARY.** Following theoretical expectations, results indicate that nasal passage size is significantly correlated with both body mass ($p=0.013$) and BMR ($p=0.006$). Conversely, within this one sample (i.e., holding climate constant), nasal passage shape was not significantly correlated with either body mass ($p=0.226$) or BMR ($p=0.131$). **CONCLUSIONS.** These results support previous suggestions that males and females exhibit similar nasal shapes due to shared climatic conditions, while differing in nasal size due to sexual dimorphism in energetic demands. These results are thus consistent with the basic tenets of the respiratory-energetics hypothesis, suggesting that both climatic and metabolic pressures likely influenced nasal morphology during human evolution. (Funding for this research provided by the National Science Foundation (BSC #2050253) to APK & SDM and the Wenner-Gren Foundation (#10009) to APK.)

19 *KENDRICK, Alexis¹, Teressa F. BROWN¹, LaVona TRAYWICK¹, Tracey ZEINER², and Daniel CIPRIANI³. ¹School of Physical Therapy, Arkansas Colleges of Health Education, Fort Smith, AR, 72916, USA; ²School of Occupational Therapy, Arkansas Colleges of Health Education, Fort Smith, AR, 72916, USA; ³Department of Physical Therapy, West Coast University, Los Angeles, CA, 91606, USA. Intentional Grouping and Team Building within the Gross Anatomy Laboratory.

INTRODUCTION. Several benefits have been cited in literature discussing cadaver dissection, with the development of team building skills and group dynamics frequently towards the top of this list. This study aims to focus on the development of teamwork skills in the human gross anatomy lab and if the formation of intentional lab groups based on individualized strengths assessments impacts this development. **METHODS.** The participants in this study were physical therapy students enrolled in the Clinical Gross Anatomy course at a private medical school. The students were purposely assigned their lab groups of four by the researchers based on their results from the CliftonStrengths assessment. Although there are 34 different “strengths,” they fall under four main categories: executing, influencing, relationship building, and strategic thinking. Each group had a student who scored highly in each of the four areas. This study used a pre-experimental one-group pretest–posttest design. The data measures were TCI (Team Climate Inventory) additional open-ended questions were asked on the posttest. **SUMMARY.** Using a thematic analysis, two primary dimensions of the teambuilding study were identified. First, personality trait differences were identified within groups and led to further understanding of competition within the group and individual self-confidence issues. Secondly, group dynamics were identified as they related to a positive, negative, or neutral experience. Out of nine groups surveyed in this study, four (4) reported very positive comments related to group dynamics and team formation, two (2) groups had comments that were categorized as neutral, and three (3) negative experiences in the team. **CONCLUSIONS.** This pilot study demonstrated that intentional grouping based on individualized personality strengths did not result in overall improved development of team dynamics. While significant positive experiences were noted in some groups, significantly negative experiences were noted in others, with some neutral still.

continued on next page

Abstracts - Poster Presentations continued

49 *KHACHIK, Lena¹, Adam EL-MENINI¹, Nachammai NACHIAPPAN¹, Jana SATMA¹, James COEY^{1,2} and Nahidh AL-JABER¹. ¹St. George's International School of Medicine, Keith B. Taylor Global Scholars Program, Northumbria University, Newcastle upon Tyne, NE1 8ST, United Kingdom; ²Department of Anatomy, St. George's University, Grenada, West Indies.
Anatomical Variations of the Genicular Arteries: An Ultrasound-Guided Evaluation.

INTRODUCTION. Understanding the anatomy of the genicular arteries has significance for various clinical procedures in this region. Previous studies have looked at differences in the diameter and branching patterns of the genicular arteries, but variations have only been studied in cadavers or patients with pre-existing medical conditions such as chronic knee pain. In order to reduce the risk of damage to other structures, variations in genicular arteries should be better understood. The aim of this study was to establish possible anatomical variations to assess the risk of nerve block complications and osteoporosis development. METHODS. The superior medial genicular artery (SMGA), superior lateral genicular artery (SLGA), inferior medial genicular artery (IMGA), and inferior lateral genicular artery (ILGA) were imaged using ultrasound on 30 volunteers. Statistical analysis was conducted to measure the diameter and distance of the genicular arteries to their relative bone. Demographic information was gathered and taken into consideration. SUMMARY. Significant variations between participants were seen in the diameter of the genicular arteries. Several anatomical differences were also seen in the distance between the genicular arteries and their relative bone cortex. CONCLUSIONS. Anatomical variations were more common than expected and should be taken into consideration in clinical practice. Differences in diameter can be used to further the understanding of factors contributing to osteoporosis development. Awareness of variations in distance of genicular arteries to their relative bone are critical to avoid damaging local structures when performing intravenous procedures such as nerve blocks. The use of bedside ultrasound on a patient-to-patient basis can significantly improve the efficacy of assessing individual anatomical variations.

46 *LEWIS, Courtney S., Yordi A. CALIX, Marilou V. FONTI, Brooke A. GOLDSTEIN, Brianna N. MOSLEY, Lital NAINSHTEIN-BATUROV, Brian OBINERO, Ramona F. BAEZ, and Sushama RICH. Touro College of Osteopathic Medicine, New York, NY, 10027, USA.
Tibiocalcaneus Internus: A Rare Accessory Muscle in the Tarsal Tunnel.

INTRODUCTION. The posterior compartment of the leg is divided into superficial & deep layers. The Tibio-calcaneal internus muscle (TCI) is a rare accessory muscle found in the deep compartment. RESOURCES. In the dissection of a 92y/o Caucasian male donor via Grant's Dissector guidelines, an accessory TCI was identified; measurements and correlations with surrounding structures were recorded. DESCRIPTION. Upon reflecting the superficial layer of the posterior right leg & deep to the transverse intermuscular septum, we identified an accessory TCI located in the same fascial covering of the flexor digitorum longus; proximal attachment with the Soleus muscle, at the medial aspect of the Soleal Line via a tendon that measured 111.96mm L, 0.33m W & distal insertion to the medial calcaneus via a cylindrical tendon that measured 37.88mm L, 2.00mm W. The TCI muscle belly fibers measured 16.70mm L & 7.65mm D & 23.32mm W within the tunnel. The TCI was 165.75mm L. The TCI was deep to the Soleus muscle then emerged out of it before diving into the flexor retinaculum, hence the Tarsal Tunnel (TT), prior to its distal attachment. The TCI was supplied by the Tibialis Posterior artery & Tibial nerve. It was a weak foot inverter on manual traction. The differences in depth of the right & left Gastrocnemius muscle: the right posterior leg (with TCI) the medial head was 9.33mm & the lateral head 5.16 mm; both were larger than in the unaffected left leg with medial head 6.25mm & the lateral head 4.77mm. SIGNIFICANCE. This account of a TCI documents its prevalence & presentation. It may be used to assist in the differential diagnoses of tarsal tunnel syndrome, in cases where there is impingement of the posterior tibial neurovasculature. Awareness of presence by MRI & other imaging in the cases of Tibial nerve impingement within the TT can aid in their proper surgical/medical interventions associated with accessory TCI.

52 MAGANG, Loeto¹, Ibukun OGUNSAKIN¹, Salima MESKINE¹, Salwa ABOUKAL¹, Marwin ANANDRATI¹, James COEY^{1,2}, Haider HILAL^{1,2}, Nahidh AL-JABER¹, and Tarek ALMABROUK¹. ¹St. George's International School of Medicine, Keith B. Taylor Global Scholars Program, Northumbria University, Newcastle upon Tyne, NE1 8ST, United Kingdom; ²Department of Anatomy, St. George's University, Grenada, West Indies.
Using Ultrasound to Investigate the Level of the Bifurcation of the Posterior Tibial Artery within the Tarsal Tunnel.

INTRODUCTION. Current consensus of the vascular anatomy of the Tarsal Tunnel relies on cadaver dissections, with most cadaveric studies having been performed prior to 2012. This is possibly due to the relative shortage of non-congenital tarsal tunnel pathologies, moreover, cadaveric dissections, due to their invasive nature, make conducting studies difficult, whereas ultrasonography provides a viable means of visualizing vasculature. The aim of this study was to compare the rate of documented variations of the bifurcation of the posterior tibial artery in cadaveric studies, using ultrasonography. METHODS. Volunteers were imaged using ultrasound at a reference line (medial malleolus to the medial calcaneal

Abstracts - Poster Presentations continued

tuberosity) on both legs, and the posterior tibial artery or its tributaries were visualized. The probe was also fanned proximal and distal to the reference line for confirmation. The point of bifurcation relative to the reference line was then noted. Demographic information was also collected and included in the data processing. Statistical analysis was conducted in order to determine the most common bifurcation point location and establish possible relationships between branching patterns and different demographic factors. **SUMMARY.** Noted variations included bifurcation prior, after and at the reference line. Of the examined participants, 60% had a bifurcation distal to the reference line, with 25% and 15% having bifurcations proximal to the reference line, and on the reference line respectively. **CONCLUSIONS.** The rates of variation of artery bifurcation dispute recent cadaveric studies. It has been noted that the plurality of bifurcation points occurred proximal to the same reference line. Previous work states that 71.67% of bifurcations occurred proximal to the reference line with 23% of bifurcations occurring distally. Due to these discrepancies, we recommend that more studies regarding the bifurcation of the posterior tibial artery must be conducted.

34 *MARWAHA, Vidur, Aaron MURILLO-RUIZ, Dylan SALAZAR, Esdras O. RODRIGUEZ, Diana PETTIT, Sarah WALKER, Geoffrey GUTTMAN, and Ricardo BELMARES. Department of Medical Education, The Paul L. Foster School of Medicine, Texas Tech University Health Sciences Center, El Paso, TX, 79905, USA.

Evaluation of a Surgical Anatomy Elective Course for Medical Students.

INTRODUCTION. The Surgical Anatomy Elective Course (SAEC) at Paul L. Foster School of Medicine (PLFSOM) is an intensive 2-week review of anatomy, common procedures, and basic surgical techniques aimed at preparing 4th-year medical students to enter surgical specialties. The purpose of this study is to assess the efficacy of surgical procedure instruction using cadaver-based surgical simulations. **METHODS.** Seven SAEC participants completed a test both prior to and after completion of in-person instruction for the following procedures: splenectomy, anterior abdominal wall hernia repair, thyroidectomy and neck resection, bowel resection, excision of skin lesions, ultrasound basics, and wrist surgeries. The results for both the pre-test and post-test were analyzed using a Wilcoxon Rank Sum. The null hypothesis was that there was no statistically significant difference between pre and post-tests, and the alternate hypothesis was that there was a statistically significant increase in post-test grades. **SUMMARY.** We found a statistically significant increase in post-test scores for five of the seven procedures ($p=0.05$): abdominal wall hernia repair ($p=0.016$), thyroidectomy and neck resection ($p=0.027$), bowel resection ($p=0.017$), excision of skin lesions ($p=0.017$), ultrasound ($p=0.027$), and carpal tunnel repair ($p=0.027$). There was no significant difference between pre and post tests for the splenectomy procedure ($p=0.109$). **CONCLUSIONS.** Given that post-test scores were significantly higher after most procedures, we believe cadaver-based surgical simulations in the SAEC to be an effective method of preparing fourth year medical students for surgical specialties.

22 *MASSOUD, Tarik F., and Sara G. TEDLA. Division of Neuroimaging and Neurointervention, Stanford Initiative for Multimodality neuro-Imaging in Translational Anatomy Research (SIMITAR), Department of Radiology, Stanford University School of Medicine, Stanford, CA 94305, USA.

Arterial Tortuosity in the Head & Neck: Neuroimaging Review of Anatomy and Clinical Arteriopathies.

INTRODUCTION. Excessive twists and turns (tortuosity) in craniocervical arteries are commonly seen on neuroimaging. When severe, arterial tortuosity (AT) can lead to neurological symptoms, or may be a marker of vessel fragility and underlying arteriopathies. Although objective AT morphometric indices can be determined from radiological images, routine clinical quantitation of AT is seldom undertaken. We provide a pictorial and educational review of craniocervical AT as a prelude to future anatomical and morphometric analyses of neck arteriopathies. **RESOURCES.** We comprehensively review imaging findings in a wide spectrum of acquired and inherited AT disorders. **DESCRIPTION.** AT develops as arterial elongation associated with mechanical factors: blood pressure and flow, axial tension, and wall structural changes. We will illustrate the 3 Bullitt types of AT. Craniocervical AT may affect small (retinal) to medium and large sized arteries (cerebral and carotid). Acquired AT is associated with hypertension, diabetes, obesity, and atherosclerosis. Numerous arteriopathies are associated with AT such as FMD and SCAD, as well as inherited causes: Marfan syndrome, Loeys-Dietz syndrome, aneurysms osteoarthritis syndrome, autosomal recessive cutis laxa Type 1, arterial tortuosity syndrome, and Menkes disease. Carotid AT is often associated with aging, but may lead to dizziness, vertigo, syncope, or persistent tinnitus. When severe, neck arterial kinking or angulation can result in occlusion and possible TIAs and stroke. Cerebral AT is also reported in the elderly with hypertension, and in Moyamoya collaterals. Increased flow in AVMs leads to tortuous feeders and drainers. **SIGNIFICANCE.** AT has potential clinical use as a structural biomarker for common arterial diseases and rarer FMD, SCAD, or genetic arteriopathies. Incidental imaging findings of marked AT should prompt a search for predisposing factors or associated clinical conditions with possible substantial clinical impact.

continued on next page

Abstracts - Poster Presentations continued

61 *NGO, Wayne¹, Caitlyn FINNERTY², Malaka G. FINCO¹, Bethany HOLLEY¹, and Rachel A. MENEGAZ¹. ¹University of North Texas Health Science Center, Fort Worth, TX, 76107, USA; ²The College of New Jersey, Ewing Township, NJ, 08618, USA. Additive Effects of Diabetes and Lower-Limb Amputation on Osteoarthritis Compared to Controls.

INTRODUCTION. Individuals with type II diabetes and individuals with lower-limb amputation both have increased risks of developing osteoarthritis (OA) compared to the general population. Differentiating influences of amputation and diabetes could help better manage the risk of developing OA in these populations. **METHODS.** 30 CT scans were obtained from the New Mexico Decedent Image Database. We measured hip and knee joint space, as indicators of OA, in four groups of individuals: 1) lower-limb amputees with diabetes, 2) lower-limb amputees without diabetes 3) diabetic controls, and 4) healthy controls. We hypothesized lower-limb amputees with diabetes would have the most impaired musculoskeletal health, followed by amputees without diabetes, diabetic controls, then healthy controls. Comparisons between groups were assessed using Kruskal-Wallis with Bonferroni post hoc tests. **SUMMARY.** Amputees with and without diabetes showed significantly narrower hip ($p=0.01$) and knee ($p=0.08$) joint space bilaterally compared to diabetic and healthy controls. This result suggests amputees could be at a higher risk of developing lower-limb OA compared to diabetic and healthy individuals, which is in line with prior work demonstrating the prevalence of OA in the amputee population. **CONCLUSIONS.** Amputees with diabetes had the most narrowed joint space, followed by amputees without diabetes, then diabetic controls, and healthy controls. While not statistically significant, these trends suggest amputees with diabetes are at increased risk of developing OA compared to amputees without diabetes. Perhaps the aggressive management of blood glucose and post-amputation physiotherapy treatments could help reduce joint deterioration in these patients. Future work will focus on increasing sample size to assess if these findings are generalizable to a larger population. (The Free Access Decedent Database was funded by grant No. 2016-DN-BX-0144 from the National Institute of Justice.)

16 *RASTELLINI, Cristiana¹, Samuel BEZOLD,² and Richard COGGESHALL¹. ¹Department of Neuroscience, Cell Biology and Anatomy, University of Texas Medical Branch, Galveston, TX, 77555, USA; ²Department of Radiology, University of Texas Medical Branch, Galveston, TX, 77555, USA. In-Person vs. Virtual in the Teaching of Human Anatomy.

INTRODUCTION. The recent COVID 19 Pandemic affected instruction at all levels. Medical educators had to quickly adopt alternative strategies to minimize any disruption in learning activities. The Gross Anatomy & Radiology Course (GAR), first foundational science course offered by our School, is based on content delivered by experts, lab dissection, Problem Based Learning and interactive sessions (ISs). As the Pandemic prevented in-person activities, the same non-mandatory ISs (based on Poll Everywhere questions [8-12 questions/hour] and discussions) were delivered remotely using Zoom. **METHODS.** The authors compared four GAR cohorts of ISs (two in-person and two virtual). For each year, we analyzed: initial attendance (15 minutes past the start time) vs. final attendance (10 minutes before the end time), attendance at the beginning of the course vs. attendance at the end of the course, number of student questions, and time spent in interactive discussion. Over 50 hours of ISs were analyzed (24 hours in-person and 30 hours virtual). Students' end of course evaluations were also examined. Statistical analyses were performed using the Student's t-test (P value ≤ 0.05). **SUMMARY.** In-person ISs were attended by an average of 110 students (SD:33) while virtual ISs were attended by an average of 192 students (SD:14). In both groups attendance decreased over the length of the course but with significant difference (-39% in-person vs. -6% virtual). Differences in initial and final attendance of each IS were minimal with a larger number of students leaving the virtual vs. the in-person sessions. The number of student questions and time of interactive discussions were significantly higher in the virtual compared to the in-person sessions. Learners' evaluations consistently appreciated ISs both in-person and when delivered virtually. **CONCLUSIONS.** While it is critical to reestablish in-person activities for learners, virtual platforms can be advantageous. Virtual presentation may facilitate students' attendance and participation in valuable sessions. (Acknowledgements: Era Buck, PhD, Office of Educational Development, UTMB and Betty Shipp, RN, Willed Body Program, UTMB.)

Abstracts - Poster Presentations continued

73 ALEXANDER, Austin P., Kathryn NORTON, and Marsha D. RUTLAND. Department of Physical Therapy, Hardin-Simmons University, Abilene, TX, 79698, USA.

Midsagittal Dissection of the Brain in Situ.

INTRODUCTION. As Doctor of Physical Therapy (DPT) students learn anatomy in the cadaver lab, internal and midline anatomical structures of the head/neck may be difficult for students to visualize. Anatomical models are commonly used for mid-sagittal anatomical identification. This case study highlights the procedure to develop a mid-sagittal dissection of the brain in situ. **RESOURCES.** A 66-year-old male embalmed cadaver (11-month postmortem) was dissected by first year DPT students. Occupation: farmer with causes of death including cardiovascular disease, diabetes, and hypertension. **DESCRIPTION.** Initially, clearing of the skin, fascia, and subcutaneous tissue was performed off the midline of the face, nose, and occiput with a scalpel. Once the sagittal suture is exposed, the initial sagittal cut was made through the bone. A Craftsman oscillating multi-tool saw can be used to guide a midsagittal cut and control for depth of cut. To ensure the cut is in a true midsagittal section, recommendations are made to avoid cutting completely through the skull with the autopsy saw and finish with a chisel and hammer. The midsagittal cut should extend from the bridge of the nose to the foramen magnum. Utilizing a Stryker oscillating orthopedic bone saw or an oscillating multi-tool saw, the midline of the mandible and maxilla then can be cut. A retractor was used to separate the skull bones along the sagittal suture and expose the dura matter and superior sagittal sinus. The dura was cut with a scalpel to expose the falx cerebri. Using a twelve-inch knife, the midsagittal cut was made using one slicing motion to cut through the corpus callosum, diencephalon, brainstem, and cerebellum. With the retractor still in place, a manual saw or oscillating saw was used to cut through the cervical spine, sphenoid, ethmoid, and hyoid bones. A scalpel or larger knife then was used to cut through the midline of the larynx and esophagus. The head and cervical region was then reflected to expose a midsagittal dissection of the brain in situ. **SIGNIFICANCE.** Utilization of the midsagittal dissection of the brain in situ allows students to identify midline structures of the brain, larynx, nasal cavity, and pharyngeal constrictors that are often difficult to identify as well as see the cranial nerve still intact and provides additional learning experiences.

40 *TALLEY, Celine M., Kara FADANELLI, Suneeti DASH, and Melissa ZOLNIERZ. Kansas City University, Joplin, MO, 64804, USA.

Mapping the Course of the Saphenous Nerve: A Cadaveric Study.

INTRODUCTION. The saphenous nerve is the target of adductor canal blocks, an increasingly utilized surgical pain intervention during knee procedures. Studies provide information for finding the nerve through landmarks such as the medial condyle of the femur. However, descriptive mapping of the saphenous nerve course along those points is limited. The present study maps the route of the saphenous nerve to understand its variations. **METHODS.** Formalin-embalmed cadavers, from Kansas City University's Gift Donor Program, were examined in this study. Eighteen donors (both male and female) met the criteria for inclusion in the research, providing 34 saphenous nerve samples. Careful dissection of the saphenous nerve occurred starting at the apex of the femoral triangle and following it down to the medial condyle of the femur. The relationship of the saphenous nerve to soft tissue structures, vessels, and bony landmarks was recorded through measurements and photography. **SUMMARY.** The course of the saphenous nerve was consistent between specimens. The saphenous nerve ran deep to the sartorius muscle, mirroring the great saphenous vein path. The nerve consistently entered the vastoadductor membrane and its distal course wrapped medially along the medial condyle of the femur at an average distance of 4.28 cm ($\sigma = 1.21$ cm) from the level of the medial epicondyle of the femur. Additionally, limited nerve branching was discovered. Only two specimens from different donors (6% incidence) branched before entering the vastoadductor membrane. **CONCLUSION.** Based on our study, the course of the saphenous nerve has no significant variation. Therefore, the nerve is an anatomically reliable target for surgeon-lead adductor canal blocks.

POSTER SESSION 2

68 *ANGELES, Miguel, and Sakti SRIVASTAVA. Division of Clinical Anatomy, Stanford University School of Medicine, Stanford, CA 94305, USA.

A Case of Duplicated Inferior Vena Cava in Cadaver Dissection.

INTRODUCTION. The complex sequence in the development of the venous system in the abdomen determines different anomalies of the Inferior Vena Cava. The persistence of the right and left supracardinal veins gives origin to duplicated inferior vena cava or Left Inferior Vena Cava. **RESOURCES.** A case of duplicated inferior vena cava was found during the dissection laboratory in the Clinical Anatomy class for medical students at the Division of Clinical Anatomy at Stanford. **DESCRIPTION.** The donor was a 76-year-old woman who died of a malignant neoplasm of ovary. The findings included a duplicate IVC running in the left side and two common iliac veins that did not join. The duplicated IVC received the left

continued on next page

Abstracts - Poster Presentations continued

renal vein and the left suprarenal vein before curving and connecting to the right IVC at the level of L1. The left ovarian vein drained to the left renal vein, and the right ovarian vein drained to the right renal vein. SIGNIFICANCE. The knowledge of the anomalies of the inferior vena cava is relevant for abdominal clinical and surgical procedures and imaging studies.

20 *ARBOR, Taflina¹, Snehal GARG², Marissa REMEDI², Anna GARVEY², Harrison SMITH², and Joseph GONSIOROWSKI².

¹Division of Biomedical Sciences, College of Osteopathic Medicine, Marian University, Indianapolis, IN 46222, USA; ²College of Osteopathic Medicine, Marian University, Indianapolis, IN 46222, USA.

Bilateral Congenital Absence of the Middle Nasal Turbinates.

INTRODUCTION. Complete or partial absence of nasal turbinates may be the result of congenital absence, pathologic processes, or surgery. The purpose of this report is to demonstrate what we believe is a rare case of bilateral congenital absence of the middle nasal turbinates and highlight associated conditions and symptoms in patients with turbinate absence. RESOURCES. A >90-year-old female undergoing postmortem evaluation demonstrated bilateral abnormalities of the nasal turbinates. Careful dissection and examination of the sinonasal region was performed. In addition, associated pathologic features were identified following a full-body dissection. Photographs and pathologic descriptions of notable findings were recorded and provide the basis for discussion. DESCRIPTION. The middle turbinates are absent bilaterally, while the superior and inferior turbinates are variably developed. Within the left nasal cavity, the openings of the frontal, anterior ethmoidal, and maxillary sinus remain separate, and the lateral wall of the middle meatus is intact. On the right side, the lateral wall of the middle meatus, the semilunar hiatus, and the ethmoidal bulla are extensively resorbed with evidence of mucosal inflammation suggesting rhinosinusitis. In addition, the right frontal sinus is filled with mucus and its linings appear inflamed. Bony pathologies in this individual include bilateral and well-circumscribed lytic lesions involving the inner and outer table of the parietals consistent with osteoporosis circumscripta cranii, a classic indicator of Paget's disease. Consistent with the age of this individual, there is significant bony degeneration of the vertebral column. SIGNIFICANCE. Congenital bilateral absence of the middle turbinates is extremely rare. Evidence of age-related bony degeneration and pathological bone resorption appear incidental. A wide range of causes and consequences of turbinate absence, including surgical resection and atrophic rhinitis, are discussed.

77 AYUB KHAN, Rafika Munawara., Kanchan KAPOOR, Mahesh K SHARMA, Poonam GOEL, and Poonam CHAUDHARY. Government Medical College and Hospital, Chandigarh, CH, 160047, India.

Age-Related Evaluation of Morphogenesis, Histogenesis, and Vasculogenesis of Human Fetal Stomach.

INTRODUCTION. Ultrasonographic visualization of the fetal stomach is possible by 9 weeks of intrauterine life and it can be used as an important indicator organ of the fetal well being. It is essential to establish the different developmental events in relation to gestational age and fetal weight, in order to diagnose abnormalities. The present study assessed the chronological development of the fetal stomach. METHODS. Morphometry of 50 fetal stomachs from 12 to 38 weeks of gestation was recorded. Light (H&E, MT, MGS) and confocal microscopy (TRITC) were used to study the cellular architecture. SUMMARY. Morphogenesis: A pattern of consistent increase in the growth rate of different parts of the stomach (except pyloric canal) from 12 to 28 weeks was seen followed by a steady decline till term. In contrast, the pyloric canal showed a continuous increase in the growth rate till the term. The majority of the specimens showed a maximum increase in pyloric thickness around 20 weeks and had a strong correlation with gestational age and fetal weight. Histogenesis: The adult characteristics were distinct by 24 weeks of gestation. Interestingly, the glandular development showed a retro-cranial sequence in development showing the well matured pyloric glands by 12 weeks and cardiac glands by 14 weeks. However, the muscular layers followed an orthodox craniocaudal sequence of development with an oblique layer in the cardiac and body region by 14 and 16 weeks respectively. The parietal cell preceded the development of chief cells. The pyloric sphincter had the striking characteristic of the whorling pattern of the inner circular layer by 12 weeks. Vasculogenesis: Sprouting and splitting angiogenesis was evident by 12 and 20 weeks respectively. Vascular plexus in the different layers were well developed by 24 weeks and submucosal plexus contributed to the formation of mucosal plexus. CONCLUSIONS. This cumulative data will enhance the understanding of the intricacy of embryogenesis at various gestational periods while stressing the importance of gestational age and fetal weight in the diagnosis of congenital anomalies.

59 *BARTON¹, Scott and Mary TRACY-BEE². ¹Medical Education Department, UC San Diego School of Medicine, La Jolla, CA, 92093, USA; ²Anatomy Department, University of Detroit Mercy, Detroit, MI, 48221, USA.

Honoring Our Donor's Legacy and Impact through the Creation of a Memorial Site.

INTRODUCTION. The impact a donor has on the education and clinical aptitude of health care professionals is immeasurable. These "silent teachers" are an important part of our student's learning academically, emotionally, and spiritually. The sacrifice made by the donor and their family should be remembered and honored. RESOURCES. Over the past nine years, the University of California San Diego School of Medicine Anatomical Services program and collaborators

Abstracts - Poster Presentations continued

have worked to create a space to honor its donors. The Memorial Site is located on the cliffs at the edge of the Pacific Ocean in La Jolla, which overlooks the location where the cremated remains are spread at sea. Resources included a bronze marker, benches, etched boulders, landscaping material, premium oceanfront land, and many hours of employee and consultant's time. DESCRIPTION. The nine year journey to secure, design, and create this space involved many obstacles and came at a great financial cost. Coordination of multiple Vice Chancellor areas, facilities management, project management, and other stakeholders proved to be a challenging aspect of this venture. However, the response from the community has been overwhelmingly positive. SIGNIFICANCE. Offering a reflection space for our donor's loved ones has been well received. We advocate for the development of a memorial site to honor all donors.

14 BASET, Nawsin, Sirai RAMIREZ, Micaela R. MOTZKO, Elif DIRICANLI, and Melissa S. ZOLNIERZ. Department of Anatomy, Kansas City University, Kansas City, MO, 64106, USA.

Cadaveric Exploration of the Pectineal vs Sacral Anterior Longitudinal Ligament for Pelvic Prolapse.

INTRODUCTION. Apical pelvic organ prolapse refers to the descent of the vaginal vault after a woman has a hysterectomy. The standard treatment for apical prolapse is a sacrocolpopexy, a procedure attaching mesh from the vaginal apex to the anterior longitudinal sacral ligament. A newer treatment, the pectopexy, attaches mesh from the vaginal apex to the pectineal ligaments bilaterally. Research indicates that pectopexy causes fewer complications and lower rates of prolapse recurrence. This result may stem from the biomechanical properties of these ligaments. Our study compares the biomechanical differences of the pectineal ligament and anterior longitudinal sacral ligament. METHODS. Thirty formalin-preserved female cadavers from Kansas City University and the University of Nebraska were examined. Transverse scalpel cuts were made on the superior pubic ramus and sacral promontory to remove the pectineal ligament and anterior longitudinal ligament, respectively. Ligaments were removed with forceps and placed in individual labeled containers with a wetting solution for ligament maintenance. A BOSE Electroforce Mechanical Testing Instrument was used to determine the mechanical properties of each ligament. Data was imported to Excel for statistical comparison of results. SUMMARY. Each cadaver provided us with one anterior longitudinal sacral ligament and two pectineal ligaments, totaling 30 anterior longitudinal sacral ligaments and 60 pectineal ligaments. Mechanical testing included three distinct property measurements: peak force at failure, toughness, and elastic modulus. CONCLUSION. The ligament with the higher peak force at failure, toughness, and elastic modulus should better withstand forces placed upon it. By selecting this ligament during prolapse repair, a better surgical outcome should be seen.

53 *BRADLEY, Libby J., Kimberly E. MEYER, Rustin E. REEVES, and Emma K. HANDLER. Structural Anatomy and Rehabilitation Sciences, University of North Texas Health Science Center, Fort Worth, TX, 76107, USA.

The Effect of Active Learning in an Asynchronous Online Graduate Anatomy Course.

INTRODUCTION. Recently, there has been an increase in the quantity of online anatomy courses. Moreover, in-person anatomy courses have increasingly moved from a traditionally lecture-focused learning model to models including active learning, an approach in which students engage in their own learning. The present study investigates the effects of different active learning activities on the perception and performance of students in an online anatomy course. METHODS. Within an online anatomy course, four active learning techniques (jigsaw, question constructing, concept mapping, and team-learning module) were implemented into the first unit, and students were divided into five groups. Four groups engaged with one of the active learning techniques, while one group did not. After exam completion, students were asked to participate in a survey concerning their perceptions of the active learning technique. Surveys and exam grades were de-identified and matched to compare perceptions to performance. This research study is ongoing through Spring 2022. SUMMARY. Although Chi-squared tests revealed there were no significant differences between the five groups, it was found that students who felt more prepared prior to the course beginning also felt active learning prepared them more for the exam. A Kruskal-Wallis test revealed that there were no significant differences concerning perceptions or performance of the five groups. Jigsaw and concept mapping were perceived better and had higher exam scores on average than question constructing, team-learning module, and control. CONCLUSIONS. These findings suggest that students performed better on their exam and had a better understanding of the course content in jigsaw and concept mapping. Researchers aim to further understand the effects that active learning has on performance and perceptions of the techniques as the semester progresses, along with a greater sample size generated with each technique being utilized in future units.

continued on next page

Abstracts - Poster Presentations continued

62 *BUBB, Kathleen C., Ritwik BAIDYA, Sushil KUMAR, Santosh K. SANGARI, and Estomih P. MTUI. Division of Anatomy, Department of Radiology, Weill Cornell Medicine, New York, NY, 10065.
Retro-aortic Aberrant Renal Arterial Trunk with Branches to Each Kidney – A Rare Variation.

INTRODUCTION. Retroperitoneal interventions involving the kidney, ureter, and aorta require that renovascular variations are well documented. A single renal artery is only present in 70% of kidneys while accessory and aberrant renal arteries account for the remaining 30%. Unlike accessory renal arteries, aberrant renal arteries are end arteries that supply a renal segment without entering the hilum, typically piercing the upper or lower poles of the kidney. Inferior polar accessory renal arteries typically arise from the renal artery, anterior and lateral aspects of the aorta, and median sacral artery. These arteries have been associated with an increased risk of complications during retroperitoneal surgery, hydronephrosis, hypertension, and ischemic renal injury. Given the importance of variations of the renal arterial supply for academic, imaging, and surgical purposes, documentation of rare and novel variations of the inferior polar renal arteries is important in ensuring patient safety. RESOURCES. During routine dissection of a 72-year-old female Caucasian donor, multiple variations in the renal vasculature were noted. The most significant finding was a retro aortic inferior polar accessory renal artery giving bilateral branches to the lower pole of each kidney. DESCRIPTION. A single arterial trunk was observed emerging from the midline on the posterior wall of the aorta, distal to the origin of the median sacral artery. After emerging anteriorly from below the aortic bifurcation, the artery coursed superiorly. At the 4th lumbar vertebral body, the artery gave a right and a left branch which pierced the inferior pole of the corresponding kidney. Additionally, both kidneys were lobulated, elongated, and had multiple accessory renal arteries. SIGNIFICANCE. This rare variation adds to the available data on renal artery variations and should be excluded when performing surgical or imaging procedures of the kidneys, ureters, and aorta.

17 *DYKSTRA, Chandler, Emma DWENGER, Elizabeth PARENT, and Sumathilatha SAKTHI-VELAVAN. Marian University College of Osteopathic Medicine, Indianapolis, IN 46222, USA.
Extracranial Hypoglossal Tumor with a Variant Ansa Cervicalis: A Case Report.

INTRODUCTION. Hypoglossal neurofibromas are rare, slow-growing, benign neoplasms of the peripheral nerve sheath consisting of Schwann cells, perineurial cells, and fibroblasts. Literature suggests that only 5% of the neurogenic tumors in the neck arise from the hypoglossal nerve. While most of them are Schwannomas, only three cases are reported as extracranial hypoglossal neurofibromas. The purpose of this report is to explore a rare combination of hypoglossal neurofibroma and a variant ansa cervicalis in a cadaver. RESOURCES. The study investigated a swelling of the right hypoglossal nerve in a 90-year-old female donor found during routine dissection. Detailed dissection, examination of the region, and histopathological analysis of the mass followed this initial finding. The entire course of the hypoglossal nerves and other cranial nerves were examined on both sides to exclude concurrent pathology. Photographs of the tumor and course of the right hypoglossal nerve were taken. A biopsy and histopathological examination of the tumor were performed. DESCRIPTION. A fusiform enlargement of the right hypoglossal nerve was observed in the submandibular region. It measured approximately 1.27x1.27 cm. The superior portion of the right hypoglossal nerve was fused to the right vagus nerve. The superior root of ansa cervicalis, normally a branch of the hypoglossal nerve, was found to arise from the vagus nerve on the right side. The left hypoglossal and vagus nerves looked normal. There was no other tumor along the other cranial nerves. Histopathological examination revealed a benign neurofibroma. SIGNIFICANCE. The rare location of the tumor and coexistent anatomical variation necessitate further investigation to understand the pathogenesis and clinical correlation better. This study documents and furthers the knowledge of this condition and intends to contribute to the currently limited body of clinical research.

71 *EZRA, David¹, Ronit AHDUT HA-COHEN², Mor CARMEL HAGOEL² and Ilya KAGAN³. ¹School of Nursing Sciences, The Academic College Tel Aviv-Jaffa, Tel Aviv, 6818211, Israel; ²Department of Medical Neurobiology, Institute of Medical Research, Hadassah Medical School, The Hebrew University of Jerusalem, Jerusalem, 9112102, Israel; ³Nursing Department, Ashkelon Academic College, Ashkelon, 78461, Israel.
Teaching Anatomy and Physiology in Nursing Schools Under the Shadow of the Covid-19 Pandemic.

INTRODUCTION. Anatomy and Physiology (A&P) is one of the main courses required to obtain a nursing diploma. The A&P course is important since it serves as a basis for the learning of core topics and courses. Routinely in pre-pandemic times, the A&P courses were conducted in frontal lectures and seminars using anatomical models. In response to the Covid-19 pandemic, significant changes and restrictions were imposed, which caused all nursing education in Israel to be conducted via distance learning. At the education policy level, changes were made so that there could be assimilation and implementation of new learning and teaching technologies which required new facilities and resources. At the individual level, teachers and students were required to obtain and develop new distance learning skills. Aims: To examine the advantages and disadvantages of teaching anatomy and physiology courses in nursing education programs during the pandemic. RESOURCES. 12 A&P lecturers (mean age = 43.4 years, 7 women) underwent an in-depth interview. 4 lecturers

Abstracts - Poster Presentations continued

taught synchronously, 7 hybridlike and 1 asynchronously. Analysis of the data revealed 4 major themes: 1) preparation 2) challenges 3) teaching quality and students' success 4) recommendations for improvements. SIGNIFICANCE. The challenges were related to a limited ability to illustrate anatomical structures, lack of eye-to-eye contact, receiving feedback, and staying focused during the lesson. Eight lecturers adhered to the course program but only four of them claimed that the quality of learning was the same as in previous years. 5 of the participants preferred to return to class when the pandemic ends, 4 others supported distance learning, and 3 suggested a hybrid teaching. Remote teaching pushed lecturers to be creative especially in actual demonstrations during lessons. In response, some of the lecturers decided to use physical demonstrations such as models while others preferred videos, boards, and presentations.

65 *GIANNARIS, Eustathia Lela, Amanda J. COLLINS, and Alexandra E. WINK. Division of Translational Anatomy, Department of Radiology, UMass Chan Medical School, Worcester, MA, 01655, USA. Anatomy Dissection Bootcamp Week: Fostering Exploration in a Supportive Environment.

INTRODUCTION. During the 2020-21 academic year, UMass Chan Medical School pivoted from in-person to virtual learning due to the pandemic. Students had completed the musculoskeletal block of their integrated anatomy course but experienced the remainder of the content virtually. An optional anatomy bootcamp was offered so interested students could experience the missed dissections. RESOURCES. Two week-long bootcamp opportunities were offered following the completion of the course. Anatomy faculty supervised groups of 3-4 learners, using donors from the anatomy course. Participants completed an evaluation following the experience. DESCRIPTION. Fifteen students participated in the first bootcamp and 25 students participated in the second bootcamp. Students were assigned to a team and, when possible, were placed with the donors they previously dissected during the course. Throughout the week, teams dissected the neck, thorax, abdomen, and pelvis, and removed the brain. On the last day, teams chose their own dissection adventure. Some student-led "adventures" included complete laminectomy, visualization of ear ossicles, cavernous sinus and orbit, and infratemporal fossa. SIGNIFICANCE. The feedback from students was favorable: 100% of respondents rated the bootcamp "excellent". Students appreciated the flexibility of the experience, freedom to explore regions in depth, and the high faculty-to-student ratio. Students reflected that they gained more from the dissection experience having already learned the content during the anatomy course. Critiques were few but were related to the intensive time commitment and dissection instructions. In circumstances where dissection cannot be completed concurrently with an anatomy course, an intensive week-long dissection bootcamp experience can be offered. Such experiences allow students to expand their anatomy knowledge, foster inquiry and exploration, and further the student and donor connection in a self-directed and supportive environment.

32 *HENDERSON, Katherine M.¹, Anne M.R. AGUR¹, and Soo Y. KIM². ¹Division of Anatomy, Department of Surgery, University of Toronto, Toronto, ON, M5S 1A8, Canada; ²School of Rehabilitation Science, College of Medicine, University of Saskatchewan, Saskatoon, SK, S7N 2Z4, Canada. Impact of Mastectomy on the Morphology and Musculotendinous Architecture of Pectoralis Major.

INTRODUCTION. Post-mastectomy shoulder pain and decreased range of motion have been associated with tightness, weakness and scarring of pectoralis major (PM). The morphology and architecture of PM have not been studied post-mastectomy to determine the impact structural changes may have on function. The purpose of this anatomical study was to compare the 3D volumetric musculoaponeurotic morphology and architectural parameters of PM in specimens with and without mastectomy. METHODS. The fiber bundles and aponeuroses of 3 female cadaveric specimens (two single mastectomy, one double mastectomy) were volumetrically dissected, digitised and modelled in 3D bilaterally. Morphology and architectural parameters (mean fibre bundle length (FBL)/physiological cross-sectional area (PCSA)) were determined and compared between mastectomy and non-mastectomy hemithoraxes. SUMMARY. Mean age of specimens was 74 ± 1.7 years. On dissection, robust scar tissue adhesions from the area surrounding the incision site extended from the skin through the pectoral fascia into the perimysium between the fiber bundles in all mastectomy specimens. These adhesions anchored the tissue layers together into a single unit which would not allow for normal movement between tissue planes. The scar extended obliquely through the inferior third of PM with the most inferior part exhibiting changes in fiber bundle density and length. Mean FBL of the most inferior part was 10mm shorter and the PCSA was smaller on the mastectomy side. CONCLUSIONS. Contraction of the inferior third of PM would be directly compromised by the scar tissue adhesions extending from the skin into the perimysium. Furthermore, decrease in mean FBL and mean PCSA is indicative of reduced excursion and relative force generating capability. Post-mastectomy, PM morphology was altered when compared to the non-mastectomy side. Further clinical study is needed to elucidate the in vivo consequences of these changes.

continued on next page

Abstracts - Poster Presentations continued

38 *LYNN, Conner W.¹, Makayla BRADY², David POWELL^{2,3}, Mary B. KROETZ¹, Steven D. WILT¹, and David J. PORTA¹. ¹Department of Biology, Bellarmine University, Louisville, KY, 40205, USA; ²Department of Biochemistry and Molecular Genetics and ³Department of Medicine, School of Medicine, University of Louisville, Louisville, KY, 40202, USA. Extracting DNA from Embalmed Tissue to Study Genetic Predisposition to Degenerative Disc Disease.

INTRODUCTION. According to a prominent study, 80-90% of people will show some evidence of degenerative disc disease (DDD) by age 50. Researchers have proposed that a Q326W substitution in the COL9A2 gene increases susceptibility to DDD. The role of collagen IX in intervertebral discs is not completely known, but due to its increased flexibility compared to other types of collagens, it is thought to connect collagen II with other components of the cartilage which are important to the integrity of the disc. Collagen II can be found within the nucleus pulposus and the inner portion of the annulus fibrosis. Following previous research that demonstrated successful genomic DNA (gDNA) isolation from embalmed tissues, this project attempted to analyze the COL9A2 gene in samples collected from an embalmed 87 y/o female cadaver donor with obvious lumbar DDD who died from ovarian cancer. **METHODS.** Samples were isolated from four tissues for gDNA extraction: parotid gland, cerebellum, genioglossus muscle and occipital lobe following approval from the donor institution. DNA samples were subsequently analyzed for concentration and purity. COL9A2 specific primers were designed for polymerase chain reaction (PCR). Following PCR amplification and DNA sequencing, samples were compared with published National Centre for Biotechnology Information (NCBI) sequences using BLASTn analysis. **SUMMARY.** DNA was successfully extracted from each tissue, but cerebellar and cerebral tissues yielded DNA of the highest purity. Nucleotide BLAST alignment did not show evidence of the Q326W substitution; however, studies suggest that this substitution is present in only 4% of patients with a form of DDD. **CONCLUSIONS.** While the Q326W substitution was not identified in this cadaver, the ability to successfully extract and amplify DNA from embalmed tissue was confirmed. This is a preliminary project and additional genes and donors will be studied in the future.

5 *MARTIN, Allison M.¹, Stacy CHELF¹, and Daniel B. DRINNEN². ¹Anatomy Department, Lincoln Memorial University DeBusk College of Osteopathic Medicine, Knoxville, TN 37932, USA; ²Lincoln Memorial University School of Medical Sciences Physician Assistant Program, Knoxville, TN 37932, USA. Early Clinical Procedure Training Using Simulated Abscesses in Fixed Cadavers.

INTRODUCTION. Early exposure to clinical procedures may help students transition from the didactic phase of training to clinical rotations. Incorporating effective training can be difficult due to cost, availability of resources, and time. We sought to evaluate the use of simulated abscesses in cadavers to incorporate clinically focused training during the didactic phase of a physician assistant (PA) program. **RESOURCES.** One-hundred and five low-cost simulated abscesses were made using balloons and lubricating jelly. Simulated abscesses were placed subcutaneously in the abdominal wall of twelve embalmed cadavers. A single incision, tunneling dissection allowed for multiple placement sites. Surgical instruments, surgical drapes, 5 cc syringes, 18- and 21-gauge needles, 10 cc saline vials, #11 scalpels, plain strip gauze wound packing, and dressing gauze were used at each station during the lab sessions. **DESCRIPTION.** Seventy-eight first year PA students participated in scheduled lab sessions which incorporated simulated abscess drainage lead by PA program faculty. Students verbalized physical exam findings, performed abscess drainage, and discussed follow-up instructions. Multiple clinical skills were introduced during the session including sterile technique, surgical draping, and handling of instruments. The simulated abscesses modeled a clinical setting while maintaining a low-risk learning environment with direct feedback from PA program faculty. **SIGNIFICANCE.** Simulated abscesses in cadavers creates an opportunity to introduce clinical skills to students during the didactic phase of a physician assistant program. Evaluation of the effect of simulated clinical scenarios in the cadaver lab on students' perception of their clinical skills is warranted. Additional procedure simulations using cadavers with longitudinal comparison of learning outcomes and students' perception of their preparedness on clinical rotations are of interest.

29 *MOORE, Jacob C.¹, Emma K. HANDLER¹, Rachel A. MENEGAZ¹, Lauren A. GONZALES¹, and Jason M. ORGAN². ¹Department of Physiology and Anatomy, University of North Texas Health Science Center, Fort Worth, TX, 76017, USA; ²Department of Anatomy, Cell Biology & Physiology, Indiana University School of Medicine, Indianapolis, IN, 46202, USA. Dental Tissue Volumes in Mice with Osteogenesis Imperfecta.

INTRODUCTION. Osteogenesis imperfecta (OI) is associated with lifelong dental problems, including dental fractures and discoloration. OI is a disorder caused by insufficient or misshapen forms of type I collagen leading to disruptions in the microstructure of bone and teeth tissues. Dentin, the hard tissue which comprises the bulk of the tooth, develops on a type I collagen matrix. Thus, collagen abnormalities in OI lead to disorganized and less stable dentin. Teeth in people with OI often exhibit dentin hypertrophy at the interior of the tooth. While enamel is thought to develop normally in OI, abnormal dentin can lead to enamel fractures. Finally, people with OI tend to have smaller teeth than people without OI. Because dental development occurs early in life, there is a lack of data surrounding the developmental program of dental differences seen in OI. Mice are commonly used models for dental development, yet, this has not yet been studied in mice. The objective of this

Abstracts - Poster Presentations continued

study is to compare dental tissue volumes of teeth from mice with OI (oim) and wild type mice (wt) to determine the degree of dental differences during late growth stages. **METHODS.** Three-dimensional models of upper and lower first molars and incisors were created from microCT scans from oim and wt mice. Scans were taken 4 weeks after birth (weaning; "W4") and 16 weeks after birth (young adulthood; "W16"). Dental tissues were measured using 3D Slicer. Mann-Whitney U tests were used to compare tissue data between genotypes and age groups. **SUMMARY.** At W4 and W16, oim mice had lower dentin volumes and total tooth volumes for upper incisors than wt mice ($p < 0.05$). At W16, molar tooth total volumes were lower in oim mice before adjusting for mandible size ($p < 0.05$). For both oim and wt groups, W16 mice had significantly greater dentin, enamel, and total tissue volumes for lower and upper incisors compared to W4 mice ($p < 0.05$), as well as greater dentin volumes for lower molars ($p < 0.05$). **CONCLUSIONS.** These results demonstrate that the trend of smaller teeth in humans with OI also holds for the oimouse. These differences are present at both the juvenile and young adult life stages. This affirms the oim mouse as a possible model for dental development in humans with OI. Further studies are needed to determine the developmental program of these differences at earlier growth stages.

8 *Morgan, Bobbi D. Department of Biomedical Sciences, West Virginia School of Osteopathic Medicine, Lewisburg, WV, 24901, USA.
Memorializing Anatomical Donors During a Pandemic.

INTRODUCTION. Becoming an anatomical donor is a selfless act that can affect a family's opportunity to remember and honor their loved one's life. Therefore, memorializing our anatomical donors and offering comfort and peace to their loved ones is a humbling privilege. Prior to COVID, family and friends would gather to share stories and students would be able to express their gratitude in meaningful ways, showing love and compassion for this special gift. However, with COVID restrictions and the desire to keep our community safe, we were presented with a unique challenge when planning our memorial service. In order to honor our donors and provide meaningful closure to their families, our Human Gift Registry program, in combination with our institutional resources, produced a virtual memorial ceremony. **RESOURCES.** The memorial service was recorded using contributions from donor families, our students, faculty and staff, where we produced a virtual memorial service that projected our genuine respect. **DESCRIPTION.** Upon completion of the memorial ceremony video, each of our donor families were sent a package containing a USB with a copy of the ceremony that included: student musical tributes, family photos, student respects, and more. Also enclosed was a memorial plaque, and a special gift for our veteran families. **SIGNIFICANCE.** Showing our respect and appreciation for our donors and their families is extremely important and we find comfort knowing we were able to achieve this. After the distribution of the ceremony, our program received numerous positive responses from families, suggesting our virtual memorial service was very successful.

11 *PHAM, Minh N., James C. YANG, Ankita JOSHI, Jeffrey M. BETTAG, Julian A. GIAKAS, Megan K. KALINOWSKI, Maurice Nigel A. MAGLASANG, Daniel DALY, and Yun TAN. Center for Anatomical Science and Education, Department of Surgery, Saint Louis University School of Medicine, Saint Louis, MO 63104, USA.
Atypical Fissures Associated with an Unusual Accessory Liver Lobe.

INTRODUCTION. Hepatic variations are common in the general population and the most prevalent variation is the presence of abnormal fissures. However, accessory lobes of the liver are rare occurrences, and the vessels associated with it are rarely discussed. **RESOURCES.** Unique morphological variations were observed in the liver of an 81-year-old male cadaver during routine dissection. **DESCRIPTION.** The liver was observed with an accessory lobe on the visceral surface and five accessory fissures. Three accessory fissures on the diaphragmatic surface were typical of a corset liver. On the visceral surface, the accessory fissures presented as two horizontal lines, each extending to either the right or left lobe. The accessory lobe was located between the quadrate lobe and caudate lobe and maintained a connection to the quadrate lobe via liver parenchyma. The hepatic triad associated with the accessory lobe was identified as a direct branch from the right hepatic artery, a direct branch from the left portal vein, and a component of the biliary system leading to the left hepatic duct. There was also a tributary to the middle hepatic vein directly associated with the accessory lobe. **SIGNIFICANCE.** The novel presence of an accessory lobe is clinically significant, particularly in the fields of surgery and diagnostic imaging. (Sponsored by the Saint Louis University Gift of Body Program of the Center for Anatomical Science and Education (CASE) with signed informed consent from the donor. The CASE gift body program abides by the rules set forth by the Uniform Anatomical Gift Act.)

Abstracts - Poster Presentations continued

80 PIAO, Jiong-Zhen¹, Wook OH², You-Jin CHOI¹, Ji-Hyun LEE¹, Hyungkyu BAE¹, Kyung-Seok HU¹, Hyoung- Moon KIM³, and Hee-Jin KIM¹. ¹Department in Anatomy and Developmental Biology, Department of Oral Biology, Human Identification Research Institute, BK21 FOUR Project, Yonsei University College of Dentistry, Seoul, 03722, South Korea; ²Maylin Clinic, Seoul, 03722, South Korea; ³Maylin Clinic, Gyeonggi, 06005, South Korea.
Ultrasonographic Analyses of Crow's Feet and Novel Guideline for Botulinum Toxin Injection.

INTRODUCTION. Crow's feet are bilateral orbital wrinkles formed by the orbital portion of the orbicularis oculi muscle, which is the target muscle for botulinum neurotoxin (BoNT) injection. This study's aim was to demonstrate a novel BoNT injection guideline by assessing muscle width, thickness, and dynamic features using ultrasonography. **METHODS.** Twenty healthy Korean volunteers (10 men, 10 women; mean age, 25.6) were participated. The width, thickness, and dynamic movement of the orbicularis oculi muscle were measured using ultrasonography in a semi-supine position. Two volunteers were selected to receive BoNT injections. Injections were administered using a novel method with two curved reference lines passing a point 15 mm lateral to the lateral canthus (conventional injection) and a point 5 mm lateral to the lateral margin of the frontal process of zygomatic bone (additional injection). **SUMMARY.** At the lateral canthus level, the distance between the lateral margin of the frontal process and the most lateral margin of the orbicularis oculi muscle was 12.5 ± 1.3 mm. The thickness of the orbicularis oculi muscle at the midpoint of the frontal process, the lateral marginal of the frontal process, and 5 mm lateral to the lateral marginal of the frontal process was 0.7 ± 0.3 mm, 1.1 ± 0.3 mm, and 1.2 ± 0.3 mm, respectively. Comparison of the ultrasound images showed that the thicker lateral portion of the orbicularis oculi muscle played a major role in the formation of crow's feet. The crow's feet of the two volunteers began to disappear from day 3 and completely disappeared on day 7 after the injection. **CONCLUSIONS.** The novel injection technique based on the ultrasonographic anatomy resulted in improvements in the appearance of crow's feet and with no side effects such as infection or edema.

50 *RAMIREZ, Sirai, Nawsin BASET, Nathaniel BALLEK and Tony OLINGER. Department of Anatomy, Kansas City University, Kansas City, MO, 64106, USA.
A Cadaveric Study of Deep Dorsal Vein and Superficial Dorsal Vein for Penile Transplantation.

INTRODUCTION. For transgender men experiencing gender dysphoria, penile transplantation is an emerging option for those that are not optimal candidates for phalloplasties. Total penile allograft requires harvesting a longer vascular pedicle for en bloc dissection. Therefore, understanding the lengths of the neurovasculature proximal to the explant provides better viability. To expand the anatomical knowledge for penile transplantation, we mapped the deep dorsal vein and the superficial dorsal vein of the penis. **METHODS.** Eighteen formalin-embalmed male cadavers were studied, housed at Kansas City University. Careful dissections freed all tissues superficial to Buck's fascia to expose the superficial dorsal vein. The vertical distance from the pubic symphysis to the turn of the superficial dorsal vein was measured using standard spreading calipers. Measurements from where the superficial dorsal vein pivots to meet the great saphenous vein were also recorded. After hemisection, the deep dorsal vein was identified and measured to its connection with the prostatic venous plexus. **SUMMARY.** This investigation yielded 19 superficial dorsal veins and 21 deep dorsal veins. Mean lengths for these venous structures were analyzed using IBM SPSS Statistics, Windows Version 23.0. These lengths were used to create a heat map to understand the variation found within the vasculature and its relationship to surrounding structures. **CONCLUSION.** Total penile allograft requires harvesting longer vascular pedicle for en bloc dissection for success. By mapping these vessels, surgeons performing a penile transplant have a better understanding of the location and variation found.

35 *RAOOF, Ameer, Avelin MALYANGO, Mange MANYAMA, Charles MSUYA, and Nasnass NASSIR. Medical Education Division, Weill Cornell Medicine-Qatar, Qatar Foundation, Doha, Qatar.
Assessing the Impact of Introducing VR to Anatomy Lab Sessions on Students' Interest and Performance.

INTRODUCTION. An array of unconventional supplemental measures has been introduced to anatomy education at Weill Cornell Medical College Qatar (WCMC-Q) in response to the challenges imposed by the pandemic. An exploratory pilot Virtual Reality (VR) station was included in all anatomy lab sessions for the fall Essential Principles of Medicine (EPOM) course taught to first year medical students. The station was optional and included the use of 3D Organon software on Oculus Quest 2 headsets. Students' opinion of whether this method improved their learning was qualitatively assessed through opting to fill a survey at the end of the course. About two thirds of the class agreed that the VR station was helpful in enhancing understanding and performance. **METHODS.** An optional VR station was included into each of the 29 anatomy lab sessions for the EPOM course. Material included a relevant VR regional anatomical imaging component using the 3D Organon software. The station included three Oculus Quest 2 and one HTC Vive headsets. Lab time was extended by about 45 minutes beyond the usual dissection time to allow students to attend the VR station in addition to other added optional stations such as the Anatomage Table and the online image quiz. Class size was 47 students attending the first-year human anatomy course. A survey was administered at the end of the semester to assess opinions about the new measures using 5-point Likert scale. **SUMMARY.** Twenty-nine students answered the survey question about VR. Sixty six percent (66%) of the

Abstracts - Poster Presentations continued

participants agreed/strongly agreed that the VR station was helpful in enhancing understanding and performance. On the other hand, 17% disagreed/strongly disagreed with that. **CONCLUSIONS.** Having a good section of the class favoring this VR pilot intervention matched our expectations. We believe through observations, that some students were unable to spare sufficient time in lab to attend the VR station and may explain the less favorable response. This limitation may be attributed to the intense dissection requirement during the lab. Our plan is to offer more free time during lab sessions partly by making the required dissection checklists more focused. We believe that further refinements of the VR stations will enhance wider students' comprehension and performance.

44 *RASTELLINI, Cristiana¹, Luca CICALESE², Lisa ELFERINK¹, Majka WOODS³, and Era BUCK⁴. ¹Department of Neuroscience, Cell Biology and Anatomy, University of Texas Medical Branch, Galveston, TX, 77555, USA; ²Department of Surgery, University of Texas Medical Branch, Galveston, TX, 77555, USA; ³School of Medicine, Academic Affairs, University of Texas Medical Branch, Galveston, TX, 77555, USA; ⁴Office of Educational Development, University of Texas Medical Branch, Galveston, TX, 77555, USA.

Integration of Clinical Skills Practice in the Gross Anatomy Course: An Innovative Approach.

INTRODUCTION. Medical simulation is a valuable strategy in Medical School curricula. An innovative learning experience, combining patient management and medical skills training was incorporated in the Gross Anatomy and Radiology (GAR) course required for our first-year medical students. **METHODS.** Seven clinical scenarios (integrated within the learning objectives of each week) were used. Each case-based exercise included 4 components: 1) patient management (through multiple choice questions and feedback), 2) execution of a minimally invasive procedure 3) identification of potential procedural complications, 4) operative report (submitted in Epic). In the GAR lab, before starting their assigned body dissection, learners performed the minimally invasive procedure. Guidelines (operative preparation, anesthesia (local), reference points/lines) were provided. Procedures included thoracostomy, lumbar puncture, insertion of a central vein catheter, emergency cricothyrotomy, liver biopsy, insertion of a Foley catheter and insertion of a nasogastric tube. Each exercise included individual as well as small group (2-3 students) activities. This exercise was assessed through a "focus group" that explored a set of established areas through questions (opening, introductory, transitioning, key and ending). In addition, students were asked to answer questions presented on a Likert scale questionnaire. Notes were collected by a group of observer faculty who later generated a report. **SUMMARY.** Overall, the exercise was well received by the learners. Themes identified included: knowledge gain on surface and spatial anatomy, risk-free practice, familiarization with minimally invasive procedures, continuity of patient care, and prediction of complications. Suggestions were provided and adopted as the activity was repeated the following years. **CONCLUSIONS.** Practicing clinical skills on cadavers has been a valuable exercise early in medical education. Additional skills, and different strategies for their integration in the dissection laboratory will be investigated. (Acknowledgements: Betty Shipp, RN, Willard Body Program, UTMB, and the "Focus Group".)

74 RUTLAND, Marsha D. and Cheyanne N. HAMILTON. Department of Physical Therapy, Hardin-Simmons University, Abilene, TX, 79698, USA.

Middle Ear Dissection in the Anatomy Cadaver Lab to Improve Future Education.

INTRODUCTION. Commonly, cadaver dissections of the middle ear are performed using an endoscope. Dissections using an endoscope are highly specialized and not available to all cadaver anatomy labs. The middle ear is difficult to dissect due to its enclosed location within the temporal bone. These factors contribute to lack of dissection of the middle ear. Instead, other methods of teaching the middle ear are used. This study provides cadaver dissection techniques that can be utilized to allow for more widespread anatomical teaching of the middle ear bones. **RESOURCES.** Embalmed Cadavers. **DESCRIPTION.** Before performing the middle ear dissection, the entire calvaria was removed using a bone saw directly above the eyebrows and one inch superior to the ear canal. Once completed, both the cerebellum and cerebrum were removed from the cranial cavity. Soft tissue surrounding the ear, styloid process, and mastoid process were removed using a scalpel. The prone position allowed the most access to the dissection area prior to initiation of the middle ear dissection. When attempting to dissect the middle ear, a section of the temporal bone was removed from the calvaria for more visualization of the external auditory meatus. Then, dissection tools were used to remove the anterior portion of bone from the external auditory meatus, exposing the tympanic membrane. Visualization of the middle ear cavity was possible after the removal of the tympanic membrane, being careful of the attached malleus. Once the middle ear was exposed, the malleus was viewed and removed followed by the incus and stapes. Care must be used with dissection of the stapes due to its fragility, and the crus can break off the footplate during removal. Once the stapes was removed, the oval window could be viewed. **SIGNIFICANCE.** By performing this dissection, the anatomy and physiology of the middle ear was clearer to first year students. The techniques used in this dissection method allowed anatomy students the ability to locate and dissect the middle ear with minimal difficulty and with common dissection tools. By performing the dissections on cadavers, students can increase their knowledge and skill set in this area without complete dependence on usage of models, textbook images, and other theoretical methods.

continued on next page

Abstracts - Poster Presentations continued

26 *SANTOS, Rosaysela, Jordan MOBERG PARKER, Boris B. BOYANOVSKY, Adrienne P. BRATCHER, Mostafa BELGHASEM, Frank H. THAI, William Y. WOO, Jose M. BARRAL SANCHEZ, and Dolgor BAATAR. Department of Biomedical Sciences, Kaiser Permanente Bernard J. Tyson School of Medicine, Pasadena, CA, 91101, USA. Are 3-Dimensional Scans of Plastinated Specimens Helpful for Learning and Assessment of Anatomy?

INTRODUCTION. Assessment of anatomy knowledge using prosected donor bodies is an important component of the anatomy curriculum in many institutions. However, it has been a time-consuming and logistically challenging task to prepare and label prosections and assess a large group of students within a limited time period. This task became more challenging after the switch to remote teaching, where anatomists had to use 2D images that were often difficult to interpret due to insufficient resolution, color discrimination, and lack of ability to orient. METHODS. We developed a library of annotated 3D scans of our plastinated anatomical specimens that were used by a class of first-year medical students to prepare for anatomy labs, a practical exam, and a multiple-choice written exam. The exams covered multiple systems and were administered at the end of a semester-long course, along with a student survey. For each practical exam question, a high-quality 2D photograph of the plastinated specimen was provided along with the link to its 3D scan. SUMMARY. 2D images contained sufficient information to answer each question, however students actively engaged the 3D scans during the exam. Surveys showed that all students found the 3D scans helpful in preparing for the practical exam. Students also rated the 3D scans as more helpful than the 2D images during the practical exam. The class mean for the anatomy practical exam was 88%. Furthermore, most students (81%) also rated the 3D scans as helpful in preparing for the anatomy portion of the multiple-choice standardized written exam. The class mean for the anatomy portion of the written exam was 89% (national average recorded at 74.9%). CONCLUSIONS. 3D scans of plastinated anatomical specimens provide a useful and effective method of learning and assessing anatomy knowledge.

POSTER SESSION 3

9 *ABDEL MEGUID, Eiman M., and Olaoluwatofunmi J. OWOLABI. Centre for Biomedical Sciences Education, School of Medicine, Dentistry and Biomedical Sciences. Queen's University Belfast, Belfast BT9 7AE, United Kingdom. Variability of the Anterior Ethmoidal Artery in Endoscopic Sinus Surgery.

INTRODUCTION. The anterior ethmoid artery (AEA) is one of three potential branches of the ophthalmic artery. Although it begins its course in the orbital cavity, it eventually traverses three cavities to terminate in two main branches in the nasal cavity. Endoscopic surgery requires the surgeon to navigate the complex anatomy of the nasal cavity. This artery is quite prominent and can therefore be at risk in surgical interventions. The aim of this study was to determine the variability of the anterior ethmoidal artery and the importance of knowing them due to the risks and complications involved in endoscopic sinus surgery. METHODS. Articles from the following databases: EMBASE, MEDLINE and PUBMED were searched using the following search terms; "Anterior Ethmoidal Artery", "Anatomic variation", "Endoscopic sinus surgery". The database yielded one hundred and twenty-nine articles. Ninety-eight of the studies were either not in English, irrelevant in terms of study direction, or the full papers were simply inaccessible and were therefore excluded. SUMMARY. Thirty-two papers were deemed eligible. The included articles were mostly conducted using Computed Tomography (CT), some however were a combination of CT and cadaveric studies while one paper was surgical in nature. The main themes of anatomical variations identified are in terms of course; dimensions in mm; distances to related structures in mm and demographic differences. The average diameter of the AEA was found to be 0.8 mm with a mean intranasal length of 5.82 mm. The distance of the AEA from the skull base ranged from 0.87 mm to 6.17 mm. CONCLUSIONS. The literature has clearly detailed the great variability of the AEA, not as much in its dimensions, but certainly in its course and relations to the nasal cavity structures and features. The findings of this study suggest the usefulness of this information to surgeons performing surgeries such as pituitary surgeries and intranasally approached orbital surgeries.

27 *BAIDYA, Ritwik, Sushil KUMAR, Kathleen C. BUBB, Santosh K. SANGARI, and Estomih P. MTUI. Division of Anatomy, Department of Radiology, Weill Cornell Medicine, New York, NY, 10065, USA. Duplication of the Falx Cerebelli – A Rare Variation.

INTRODUCTION. The falx cerebelli is a small sickle-shaped fold of the dura mater, present in between the right and left cerebellar hemisphere in the posterior cranial fossa. Superiorly, it is attached to the lower surface of the tentorium cerebelli and posteriorly to the internal occipital crest. Inferiorly, it merges with the dura mater present over the margin of the foramen magnum. RESOURCES. A rare variation of the falx cerebelli was observed while removing the brain of an 83-year-old male donor who died due to natural causes. DESCRIPTION. Duplication of the falx cerebelli was observed below the tentorium cerebelli. The two leaflets were attached superiorly to the undersurface of the tentorium cerebelli. The vermiformis of the cerebellum was present between the two folds. Inferiorly, the right falx cerebelli was merged with the dura mater present over the right margin of the foramen magnum, while the left falx cerebelli merged with the dura mater present over the left margin of the foramen magnum. SIGNIFICANCE. Variations of the falx cerebelli are rare and could pose difficulties in various analytical and surgical procedures in the posterior cranial fossa.

continued on next page

Abstracts - Poster Presentations continued

66 *BALL, Jennette J., and Dana M. MIHAILA. Department of Cell and Developmental Biology, Upstate Medical University, Syracuse, NY, 13210, USA.

Personalized Education in Medical School: Design of a Micro-credential in Anatomy.

INTRODUCTION. Since the USMLE Step 1 examination has changed to a pass/fail grading system, medical students are exploring opportunities to differentiate themselves from their peers. Micro-credentials at SUNY (State University of New York) are designed to be unique educational experiences that provide the learner with a specific set of professional skills and competencies. We propose a micro-credential in clinical gross anatomy through which students can advance their anatomical knowledge relevant for their chosen specialty as well as gain experience in educational best practices. **RESOURCES.** The ideal medical student should pass all first year examinations with a minimum of 80% and pass all anatomy practical examinations with a minimum of 85%. **DESCRIPTION.** The micro-credential in clinical gross anatomy will be personalized for the student's specialty of interest, such as surgery, neurology, otolaryngology, obstetrics and gynecology. This will be a competency-based experience that will include in-person training to acquire anatomical dissection skills and experience in instructional best practices for the classroom (in-person and remote) as well as the anatomy laboratory setting. Students will demonstrate competency by completing the course work and a comprehensive and reflective portfolio. **SIGNIFICANCE.** Students will acquire an educational experience and instructional mentoring in a team-teaching environment, and they will receive feedback from expert educators as well as from peers. This personalized micro-credential will differentiate Upstate students from other residency applicants. It will demonstrate their motivation and their competency in the specialty/discipline of their choice as well as their passion for teaching; these qualities are something of keen interest to residency program directors.

75 BASSETT, Cameron C.¹, Kerry K. GILBERT², Micah LIERLY², Troy L. HOOPER², Nathan E. BURGESS², Gary KEARNS², and Jean-Michel BRISMÉE². ¹Doctor of Physical Therapy Program at DeSales University, Center Valley, PA, 18034; ²Clinical Anatomical Research Laboratory of the Institute of Anatomical Sciences in the Department of Rehabilitation Sciences, Texas Tech University Health Sciences Center, Lubbock, TX, 79430.

Displacement and Strain of Obturator Nerve During Neurodynamic Testing with Various Limb Positions.

INTRODUCTION. The obturator nerve can be injured during surgery or trauma. Neurodynamic testing of the obturator nerve is theorized to identify obturator nerve involvement post injury. There is no objective evidence to support neurodynamic testing of the obturator nerve comparing various hip positions. The aim of this study was to evaluate the displacement and strain of the obturator nerve within the pelvis at end range hip abduction at three end range hip positions (hip neutral, hip flexion, hip extension). **METHODS.** Nine cadavers were selected by consecutive sampling and metal markers were glued to the exposed obturator nerves *in situ*. Cadavers were secured in a sidelying slumped knee bend position while fluoroscopic images of the obturator nerve were taken. Images compared resting position to the three, end range hip abduction, positions. The images were digitized, and displacement and strain values were calculated. **SUMMARY.** The obturator nerve significantly displaced distally at end range hip abduction incorporating a hip neutral position 2.76 ± 2.46 mm ($p = 0.015$). The obturator nerve at end range hip abduction incorporating hip extension was significantly displaced distally 3.31 ± 2.14 mm ($p=0.003$) and laterally 3.36 ± 3.18 mm ($p=0.013$) and underwent a decreased strain -2.96 ± 2.72 % ($p=0.018$). There were no significant differences between hip positions for parallel or perpendicular displacement or strain values ($p = 0.948$, $p = 0.925$, $p = 0.359$). **CONCLUSIONS.** Hip neutral with end range hip abduction displaces the obturator nerve distally with neurodynamic testing. Hip extension with end range hip abduction position displaces the obturator nerve distally and laterally and decreases strain. The results of this study suggest that clinicians are able to neurodynamically test the obturator nerve at end range hip abduction incorporating hip neutral and hip extension positions.

23 BASET, Nawsin, Melanie R. MEISTER, Sirai RAMIREZ, Nafis M. DEEN, Larry SEGARS, Zak B. ROSE-RENEAU, and Antony B. OLINGER. Kansas City University, Kansas City, MO, 64106, USA.

A Study on the Relationship of Retropubic Vessels to Pelvic Size During Sling Placement.

INTRODUCTION. Tension-free vaginal tape retropubic sling is a surgical procedure for urinary stress incontinence treatment in females. This procedure uses mesh to lift the urethra to prevent leakage during episodes of increased abdominal pressure. Mesh placement may generate complications, including a hematoma when a nearby artery is nicked. This study examines the pelvic vasculature and pelvic dimensions to understand correlations between the pelvis shape and vessel location. **METHODS.** The superficial epigastric, inferior epigastric, external iliac, and obturator arteries were dissected bilaterally on 15 formalin-embalmed cadavers from Kansas City University. A trocar, inserted through the vagina to the abdominal wall above the pubic bone, served as a measurement reference point from each artery. The anteroposterior pelvic diameter and the ischial interspinous distance were also recorded for each donor. Measurements, taken with spreading calipers, were recorded with Excel. Statistical analyses were carried out with SPSS. **SUMMARY.** Four arteries were dissected bilaterally, and two pelvic measurements were taken for each cadaver. This data was analyzed to determine significant correlations between

continued on next page

Abstracts - Poster Presentations continued

the artery distances to the trocar and the female pelvic size. CONCLUSION. Females with smaller pelvic sizes have a positive correlation with vasculature distances. Because of the shorter distances from the trocar, these females are more susceptible to vessel injury during a sling procedure. Understanding this relationship is beneficial for surgeons performing this procedure to reduce surgical complications.

69 *CHO, Elizabeth O.¹, Lyndee A. WARD¹, Hasintha H. AMARANAYAKA², Brian H. DENNIS², and Scott D. MADDUX¹. ¹Center for Anatomical Sciences, University of North Texas Health Science Center, Fort Worth, TX, 76107, USA; ²Department of Mechanical and Aerospace Engineering, University of Texas at Arlington, Arlington, TX, 76019, USA.
Nasal Morphology and Respiratory Airflow Physiology: Implications for Health Disparities in Asthma.

INTRODUCTION. Approximately 90% of diagnosed asthmatics share exercise-induced bronchoconstriction (EIB) as a unifying symptom. Yet, it is not actually exercise—but introduction of cold and/or dry air into the pulmonary airways—which initiates EIB. As the nasal passages are the primary source of respiratory heat and moisture exchange, it is widely acknowledged that EIB ultimately stems from insufficient nasal air-conditioning. Yet, to date, there has been little attempt to determine whether certain aspects of nasal morphology predispose an individual towards insufficient conditioning of cold/dry air. METHODS. Here, we investigate the relationship between nasal morphology and airflow physiology using computed tomography-derived 3D models of nasal passages collected from a mixed- sex sample of 20 individuals with diverse ancestral backgrounds. A total of 15 linear measurements were collected on each model to comprehensively assess nasal morphology. Computational fluid dynamics (CFD) analysis was then performed on each model to assess intranasal temperature and humidity transfers during inspiration of cold-dry air (-5°C, RH = 20%). Statistical associations between nasal morphology and airflow physiology were then assessed via two-block partial least squares (2BPLS) analysis. SUMMARY. Results of the 2BPLS analysis reveal significant covariation between nasal anatomy and respiratory physiology (RV = 0.19, P < 0.05), with the first PLS axis explaining 97.5% of this covariation. This PLS axis indicates a consistent pattern in which individuals with shorter, wider, and shallower nasal passages are associated with diminished air-conditioning capabilities. CONCLUSIONS. Individuals with shorter, wider, and shallower nasal passages may be predisposed to EIB. Further research into potential anatomical etiologies of asthma are warranted. (Sponsored by Grant #RF00241 from the Texas Center for Health Disparities via NIMHD 5U54MD006882-10.)

72 CRAIG, Taylor, Cara FISHER, Howe LIU, Armando ROSALES, and Rustin REEVES. Structural Anatomy and Rehabilitation Sciences, University of North Texas Health Science Center, Fort Worth, TX, 76017, USA.
Localizing the Sciatic Nerve in the Gluteal Region Using Surface Projections: A Cadaveric Study.

INTRODUCTION. Localization of the sciatic nerve (SN) for pain management commonly relies on ultrasound (US), but in some rural health clinics and impoverished countries, that resource may not be available. The purpose of this study is to investigate the use surface projections within the gluteal region (GR), which are the greater trochanter (GT), ischial tuberosity (IT), and the apex of the sacral hiatus (ASH), to localize the SN and assess sex differences of the SN in orientation to those landmarks. METHODS. Using 14 embalmed, dissected cadaver specimens (7 male, 7 female), 9 different measurements using a digital caliper were taken to establish the orientation of the SN to the GT, IT, and ASH within the GR. Using these data, two reference points (1 superior: 1 inferior) for the SN were marked on the left and right GR of 20 fresh frozen cadavers (10 male, 10 female). Pink latex was injected at the superior point; blue latex at the inferior point, followed by a simple gluteal maximus muscle dissection to verify the location of latex to the SN. A Welch's T-Test was used to analyze any sex differences between the left and right GR, and a Student T-test was used to compare the left and right GR within each sex. SUMMARY. There was no statistically significant difference between the 9 measurements found within each sex; however, between each sex, there were several measurements that displayed significant differences. Latex injected into the superior point proved better for localizing the SN without using US. CONCLUSIONS. Although there were significant differences in the SN measurements between the sexes, the study showed that these three bony landmarks could locate the sciatic nerve accurately. This method could provide clinicians who lack the resources of US or other imaging modalities to localize the SN reliably.

33 FADANELLI, Kara A., Melissa ZOLNIERZ, Celine TALLEY, and Suneeti DASH. Anatomy Department, School of Medicine, Kansas City University, Joplin, MO, 64804, USA.
Popliteal Artery Aneurysm: A Cadaveric Case Study.

INTRODUCTION. During dissection of the right popliteal fossa on a 70-year-old white male cadaver (KCU #1189), as part of the Kansas City University School of Medicine curriculum, a fusiform popliteal artery aneurysm was discovered. The aneurysm was not disclosed in the past medical history of the donor. RESOURCES. General dissection tools and technique were used to clean and examine the aneurysm on the right leg. The left leg was also cleaned for comparison. DESCRIPTION. The dilated popliteal artery diameter measured 29.9 mm at its widest point. The width is 2.8 times the size of the non-dilated popliteal artery width of 10.5 mm (normal range 7-11 mm). The aneurysm dilation extends 108 mm within the popliteal fossa. Opening the aneurysm showed atherosclerotic changes to the vessel walls. The left popliteal fossa dissection revealed a

continued on next page

Abstracts - Poster Presentations continued

second left popliteal artery. Sutures and surgical pins were found at both ends of the vessels, indicating a femoral-popliteal bypass graft extending 119 mm. Further examination of the right popliteal fossa showed a second femoral-popliteal bypass graft, immediately distal to the aneurysm. The right bypass was 64 mm long. SIGNIFICANCE. The cadaver had risk factors for a popliteal artery aneurysm, including older age, male sex, and ethnicity (white). Further, a coronary artery bypass graft present supports the existence and management of atherosclerosis. The cause of death was chronic hypoxemic respiratory failure. Given the vascular complications, the hypoxemia arised from perfusion dysfunction. While the left popliteal artery did not appear dilated, the presence of the femoral-popliteal bypass graft suggests a bilateral aneurysm, more common than a unilateral aneurysm. Because a risk factor for popliteal artery aneurysms is a prior aneurysm, the bilateral bypass grafts may have been an effort to repair previous aneurysms. Due to our dissection findings of a proximal aneurysm to the grafts, the right side failed.

42 *GONZALEZ, Pavel F., Joanna M. ORTEGA, Ricardo BELMARES, Heather BALSIGER, and Geoffrey GUTTMAN. Department of Medical Education, Paul L. Foster School of Medicine, Texas Tech University Health Science Center El Paso, El Paso, TX, 79912, United States of America.

An Interesting Case of Celiac Axis Anatomy and Its Surgical Implications.

INTRODUCTION. Anatomical anomalies and variations have always been of surgical interest due to its importance in operative planning and avoidance of intraoperative complications. From the Michaels classification to other team's attempts at characterization of more rare anomalies and variations of the Celiac Axis, we present an interesting case that appears to have not been described in the literature. RESOURCES. Fully embalmed cadaver dissected over 1-month using Netter's Surgical Anatomy and Approaches as well as Netter's Atlas of Human Anatomy. We used PubMed to search for various radiological studies on variations to investigate for prior descriptions of the found celiac axis variant. DESCRIPTION. Our patient was a 80-year-old-female with a history of bladder cancer whose main cause of death according to the death certificate was hypotension. The dissection presents with a high isolated left gastric about 2.5 cm above a hepatosplenic trunk, and a right hepatic artery that transverses in a retro-portal manner and gives off a short cystic artery. The right hepatic artery is also surrounded by an accessory circumferential cystic duct. SIGNIFICANCE. One can imagine how being aware of this possible anatomy can be relevant in cases of transplant surgery and especially laparoscopic cholecystectomy in order to avoid clipping an isolated right hepatic artery and causing hepatic injury or necrosis post or intraoperatively.

12 *KALINOWSKI, Megan K., Jeffrey M. BETTAG, Julian A. GIAKAS, Ankita JOSHI, Minh N. PHAM, James C. YANG, Maurice Nigel A. MAGLASANG, Yun TAN, and Daniel DALY. Center for Anatomical Science and Education, School of Medicine, Saint Louis University, Saint Louis, MO, 63104, USA.

Unique Case of Vascularization: Superficial Brachial Artery and Radial Persistent Median Artery.

INTRODUCTION. Most variations of a persistent median artery present as a branch of the ulnar artery. RESOURCES. During a routine cadaveric dissection of a 93-year-old male donor, unique arterial variations were observed in the right upper extremity. DESCRIPTION. This rare arterial branching pattern began at the third part of the axillary artery, where it gave off a large superficial brachial artery (SBA) before bifurcating into the subscapular artery and a common stem. The subscapular artery had typical vascularization. The common stem then gave off a common trunk for the anterior and posterior circumflex humeral arteries, before continuing as a small brachial artery (BA). The BA terminated as a muscular branch to the brachialis muscle. The SBA bifurcated into a large radial artery (RA) and small ulnar artery (UA) in the cubital fossa. The UA branching pattern was atypical, giving off only muscular branches in the forearm and a deep ulnar artery before contributing to the superficial palmar arch. The RA gave off the radial recurrent artery and a common trunk (CT) proximally before continuing its course to the hand. The CT from the radial artery gave off a branch that divided into anterior and posterior ulnar recurrent arteries, as well as muscular branches, before it bifurcated into the persistent median artery (PMA) and the common interosseous artery. The PMA anastomosed with the UA before entering the carpal tunnel and contributed to the superficial palmar arch. SIGNIFICANCE. This case presents a unique combination of arterial variations in the upper extremity and is clinically and pathologically relevant. (Sponsored by the Saint Louis University Gift of Body Program of the Center for Anatomical Science and Education (CASE) with signed informed consent from the donor. The CASE gift body program abides by the rules set forth by the Uniform Anatomical Gift Act.)

3 *KANDAVALLI, Naveen Babu , Katarina MILOSAVLJEVIC, Bedia CASTELLANOS, and Manan N. SHAH. Department of Anatomy, School of Osteopathic Medicine, Touro University, New York City, NY, 10027, USA.

Rare Variant Branching Pattern of Axillary Artery and High Bifurcation of Brachial Artery.

INTRODUCTION. The axillary artery is divided into three parts by the pectoralis minor. Subscapular artery, anterior & posterior circumflex humeral arteries are the main branches from the third part of the axillary artery. The axillary artery becomes the brachial artery inferior to teres major. The brachial artery typically bifurcates into the ulnar and radial arteries at the inferior aspect of the cubital fossa. In the right limb, an anatomical variation concerning the third part of the axillary

continued on next page

Abstracts - Poster Presentations continued

artery was observed. METHODS. A routine dissection of an 82-year-old female donor in an anatomy lab for medical students showed variations in the branching pattern of the third part of the axillary artery in the right upper limb. The axillary artery on the left side showed a normal branching pattern. Photographs were taken after dissection. SUMMARY. An unusual common trunk arose from the third part of axillary artery that further divides into deep brachial, common circumflex humeral, and subscapular arteries. Additionally, the anterior and posterior circumflex humeral arteries are branching from the common circumflex humeral trunk instead of the third part of the axillary artery. The axillary artery transitioned into brachial artery that divided into the radial and superficial ulnar arteries in the mid-arm area medial to the belly of the biceps brachii. The superficial ulnar artery coursed over bicipital aponeurosis in the cubital fossa. CONCLUSION. The coexistence of variation in axillary artery branching, superficial ulnar artery and high- origin radial artery makes our case unique. Our donor had a variant common trunk from the third part of the axillary artery that trifurcated into deep brachial, common circumflex humeral, and subscapular arteries. The variation is of paramount importance for diagnostic, surgical and interventional procedures especially during intra-arterial injection of drugs and angiographic studies.

60 *KHAN, Sara¹, Sarah SIDDIQUI¹, Fonteparit DEVAKUL NA AYUDHYA¹, Bassem SHERIF¹, Yuzhu WANG¹, James COEY^{1,2} and Haider HILAL^{1,2}. ¹St.Georges International School of Medicine, Northumbria University, Newcastle, NE1 8ST, UK; ²Department of Anatomy, St. Georges University, Grenada, West Indies.

Comparative Ultrasonographic Evaluation of Thickness of the Calcaneus Tendon.

INTRODUCTION. The goal of this research is to investigate an athlete's calcaneal tendon to a sedentary control group to determine if the difference, such as thickness and morphology at the calcaneus insertion will increase the susceptibility to plantar fasciitis or tendonitis. METHODS. Twenty-nine (29) athletes were evaluated between the ages of 18-32 years old using GE Logiq e ultrasound machine with a 12L-RS Transducer. Athletes were defined as people who play a minimum of 8 hours weekly. By performing a longitudinal view, the thickness of the calcaneus tendon was determined from a point in the distal third of the calcaneus tendon, proximal to the origin of calcaneal insertion. The participant's age, weight, ethnicity, smoking history, sport, and the average time spent playing sports, heel/foot pain as well as participating in other exercises weekly were recorded through self-completed questionnaires. The findings obtained from the athletes were compared to 22 non-sportsmen. SUMMARY. In total, 51 male participants which included 22 non-sportspersons and 29 sportspersons showed significant difference in the calcaneus tendon thickness at point of insertion. Out of the 29 sportspersons, 6 of those who participated in 8 hours/week of sports had a mean thickness of 0.48±0.08cm whilst the sedentary group had a mean value of 0.42±0.05cm. The maximum value of each group varied, with the sportsperson's group at 0.59cm, in contrast to 0.53cm in the sedentary group. Morphological variation at the point of calcaneal tendon insertion between the two groups suggested anatomical adaptation and signs of wear and tear as per increased involvement in a sport. CONCLUSIONS. Certain sports are known to increase the chance of calcaneal tendon pathology later in life. While carrying out our research, we found a varied thickness in both groups with a mean difference of about 0.06cm. Therefore analysis of different parameters associated with the calcaneal tendon, clinically will assist us to diagnose common injuries like plantar fasciitis and tendonitis in the near future. The values obtained could be set as a baseline for future easy diagnosis of acquiring common injuries, as well as differentiation between athletes vs non-athletes.

81 KIM, Soo-Bin, Hyung-Kyu BAE, Kyung-Seok HU, and Hee-Jin KIM. Department in Anatomy and Developmental Biology, Department of Oral Biology, Human Identification Research Institute, BK21 FOUR Project, Yonsei University College of Dentistry, Seoul, 03733, South Korea.

Anatomical Consideration of Ultrasonography-Guided Intraoral Injection for the Temporalis Tendinitis.

INTRODUCTION. Temporal tendinitis is a disease accompanied by acute inflammation and is secondary to mechanical stress such as jaw opening and closing movements and clenching teeth. To treat the temporalis tendinitis, local anesthetic or corticosteroid injections are suggested. However, the coronoid process (CP) to which the temporalis tendon attaches is located deep to the zygomatic arch, and due to the complex anatomical structure, a blind injection may result in an unwanted injection. The purpose of this study was to determine the three-dimensional location of the CP and temporalis muscle in the open mouth using ultrasonography (US) to optimize safety and efficiency in the treatment of temporal tendinitis. METHODS. US images were taken on 10 volunteers. The intraoral transducer tip was positioned at the distal end of the maxillary second molar to acquire US images. The depths from the oral mucosa to the temporalis muscle and the CP were measured. The measurements were conducted at the anterior, middle, and posterior portions of CP (ACP, MCP, and PCP) SUMMARY. The CP and temporalis muscle tendon were observed in all cases. The distance from the oral mucosa to CP was 6.08±1.19 in ACP, 5.15±1.05 in MCP, and 4.74±0.97 in PCP. Also, the distance from the oral mucosa to the temporalis muscle was 3.36±0.93 in ACP, 3.11±0.85 in MCP, and 2.84±1.10 in PCP. CONCLUSIONS. The intraoral US study of the CP and temporalis muscle with the mouth open provide the most effective and safe injection site and depth for the treatment of temporal tendinitis.

Abstracts - Poster Presentations continued

51 *MARTIN, Brooke A., Kristine A. GILLIGAN, and Adam KOLATOROWICZ. Department of Anatomy, DeBusk College of Osteopathic Medicine at Lincoln Memorial University – Knoxville, Knoxville, TN, 37932, USA.
Morphometric Analysis of Mitral Annulus Shape Variation.

INTRODUCTION. Post-operative complications following mitral annuloplasty are reported at a surprisingly high incidence, despite major advancements in the procedure over the past few decades. Limited knowledge of mitral annulus structure in females and males across the lifespan remains a concern for surgeons, primarily due to limitations in imaging modalities used to visualize the annulus prior to surgery. This study aims to quantify morphological variation of the mitral annulus as it fluctuates by age and sex using landmark morphometric techniques. METHODS. Hearts from 70 formalin-fixed, whole-body donors (38 females, 32 males, aged 47-103 yo) were dissected and examined. A MicroScribe® 3DX digitizer was used to register 3D landmark coordinates of the annulus rim as well as the anterior and posterior leaflet junctions. After further dissection, anterior and posterior leaflet lengths along with annulus circumference were measured with sliding calipers. Heart dominance and the number of valve leaflets were noted. Geometric morphometric techniques were used to visualize and identify areas of greatest shape variation in the annulus. SUMMARY. Principal components analysis of Procrustes shape data reveals that annulus curvature, closeness of the anterior and posterior margins, and posterior displacement of the annulus account for 31.3%, 21.6%, and 12.1% of total shape variation, respectively. Canonical variate analysis shows that the anterior and posterior edges of the annular rim are closer in the middle aspect in females compared to males. Regression analysis reveals annulus shape does not significantly change with age. CONCLUSIONS. Data collected from this study will allow surgeons to better predict normal anatomical variation of the mitral annulus, as well as expect and mitigate intraoperative and postoperative complications based on structural variations of the annulus and proximity of surrounding structures, such as the left circumflex artery.

21 *MASSOUD, Tarik F., and Siddhant S. DHAWAN. Division of Neuroimaging and Neurointervention, Stanford Initiative for Multimodality neuro-Imaging in Translational Anatomy Research (SIMITAR), Department of Radiology, Stanford University School of Medicine, Stanford, CA 94305, USA.
Is Percutaneous Trans-Sacral Foraminal Puncture of the Dural Sac Feasible? 3D-CT Morphometric Study.

INTRODUCTION. We test the theoretical feasibility of percutaneous posterior sacral foramen (pSF) needle puncture of the dural sac (DS) by studying the 3D anatomy of the pSFs relative to the sacral canal (SC). METHODS. On lumbosacral spine CT-myelogram orthogonal images of 34 normal subjects we noted the DS termination level and scrutinized sacral alae passageways from SC to pSFs in all 3 planes. We determined if an imaginary needle could theoretically traverse S1 or S2 pSFs in a straight path that meets the SC. If not straight, we digitally measured angulation of this route, maximum width of pSF, and midsagittal SC surface area. We tested effects of patient sex on measured dependent variables using two-way ANOVA, and performed linear regressions with age against each dependent variable (significant if $p < 0.05$). SUMMARY. Subjects F:M=24:10 with mean age 43.5 yr had DS terminations from low S1 to low S3. Mean SC areas differed between sexes (M=899.7mm², F=698.3mm², $p=0.001$). No S1 or S2 pSF joined SC along a straight path. Instead, there were bilateral angled M-shaped passageways, with SC at the center of the middle limbs. There were Tarlov cysts at junctions of lateral and medial M- limbs in 2 subjects. Axially, the mean angle formed by lateral and medial limbs was 81° at S1 and 88° at S2. Mean width of lateral limbs were 8.6mm at S1 and 6.9mm at S2. The angle formed by lateral and medial limbs was significantly larger at S1 in females ($p=0.02$). Other correlations were not significant between: S1 or S2 widths and sexes; S1 or S2 widths and SC surface area; angles formed by lateral and medial limbs at S1 or S2 and SC surface area; age and S1 or S2 widths; and age and S1 or S2 angles. CONCLUSIONS. Circuitous passageways from pSFs to the SC at S1 and S2 levels preclude percutaneous straight needle puncture of the sacral DS. We speculate that previously reported 'successful' cases without image guidance had likely followed unwitting injection of Tarlov cysts close to pSFs.

48 *MERCHO, Joseph¹, Hasan Y.,KHAN¹, Marwin,ANANDRATI¹, James,COEY^{1,2}, Haider,HILAL¹, and Tarek,ALMABROUK¹. ¹St. George's International School of Medicine, Keith B. Taylor Global Scholars Program, Northumbria University, Newcastle upon Tyne, NE1 8ST, United Kingdom; ²Department of Anatomy, St. George's University, Grenada, West Indies.
Anatomical Variation of the 3rd Part of the Axillary Artery: An Ultrasound-Based Comparative Study.

INTRODUCTION. Variation in the anatomical arrangement of the axillary artery can introduce unexpected risks in a clinical setting, with implications ranging from nerve blocks to lumpectomies. The purpose of this comparative study was to investigate the viability of using a Logiq E ultrasound to view variation in the branching of the third part of the axillary artery. Furthermore, this study aims to mitigate the risk of vascular damage to the axilla secondary to minimally invasive procedures by addressing anatomical variation. METHODS. The procedure included ultrasound imaging of the 3rd part of the axilla using a 12-15 Hz linear probe alongside doppler for 50 participants bilaterally. Branching patterns were noted proximal to and distal to the region of intended branching. Demographic information was also collected and included in the data processing. Statistical analysis was conducted holistically in order to determine the most common variation and establish possible relationships between branching patterns and different demographic factors. SUMMARY. Results

continued on next page

Abstracts - Poster Presentations continued

were compared to anatomical reported variation observed through cadaveric studies. Several anatomical variants were observed amongst branching patterns of the 3rd part of the axillary artery. The majority of participants with variants demonstrated the presence of a common trunk branching into a posterior circumflex humeral artery with individual branches for the anterior circumflex humeral artery and subscapular artery. **CONCLUSIONS.** Variations in branching patterns were significant, confirming the results of the anatomical dissection studies. Furthermore, Data from the study demonstrates the discrepancies between what is considered to be common anatomical branching and the degree of variation among the population. The non-invasive nature of ultrasound demonstrates a viable means to minimize potential risk factors associated with invasive procedures in the axillary region.

24 *MILLER, Courtney A.¹, Ashley T. STEELE¹, Jason M. ORGAN², and Rachel A. MENEGAZ¹. ¹Department of Physiology & Anatomy, University of North Texas Health Science Center, Fort Worth, TX, 76107, USA; ²Department of Anatomy, Cell Biology, & Physiology, Indiana University School of Medicine, Indianapolis, IN, 46202, USA.
Interrelationship Between Microstructure & Macrostructure in the Growing Hard Palate.

INTRODUCTION. Bone strength is the result of microstructure (bone material properties) and macrostructure (bone size and shape), and deficiencies in either can produce skeletal fragilities with an increased likelihood of injury. The development of bone strength enables the skeleton to be resistant to repetitive loading and preventing fracture. The hard palate is a unique structure that undergoes continuous loading due to tongue pressure and bite force. This study aims to investigate longitudinal changes in the palate when the relationship between microstructure and macrostructure is perturbed. **METHODS.** The study used OIM mouse (B6C3FE a/a-Col1a2OIM/J), a strain with a mutation to the structural protein type I collagen, resulting in bone fragility. The OIM mice and their wild-type (WT) littermates were micro-CT scanned as juveniles and adults. Bone mineral density (BMD) values were collected at 3 regions along the palate and 38 landmarks were placed to analyze variation in overall palatal shape. **SUMMARY.** Results show significant differences in palatal BMD and morphology between genotypes throughout growth, with fewer significant differences at the adult stage. Average BMD decreased along an anteroposterior gradient for all mice. While juvenile OIM mice had lower BMD than WT mice at all regions, adult OIM mice had significantly lower BMD at only the anterior and posterior regions. Significant differences in palatal shape were revealed between the genotypes at both age stages ($p < 0.0015$). The juvenile OIM mice had a shorter anterior palate and broader palate compared to WT mice, while adult OIM mice had a shorter posterior palate than WT mice. **CONCLUSIONS.** Increased loading of the anterior palate during incisive gnawing may result in the convergence of bone macrostructure among adult mice, while increased strain at the midpalatal suture may necessitate increased BMD even in the presence of a biomineralization defect. (Sponsored by the Indiana University Collaborative Research Grant & the Ralph W. and Grace Showalter Trust.)

30 *PICHA, Kelsey, Rebecca HLAVAC, and Kellie C HUXEL BLIVEN. A.T. Still University, Mesa, AZ, 85206, United States.
Using ARCS Model of Motivational Design to Assess Team-Based Learning in a Gross Anatomy Course.

INTRODUCTION. Contemporary anatomy education research is focused on active learning methods, such as team-based learning (TBL), that expect students to engage in learning independently before applying the content during in-class activities with peers. While best evidence guides development and implementation of TBL into anatomy curricula, it is important to assess how curricular design impacts students' motivation to learn. The current study examined components of the ARCS Model of Motivational Design to assess the implementation of TBL in a gross anatomy course. **METHODS.** Nine TBL sessions were implemented during a 20-week graduate health sciences gross anatomy course. After the last TBL session, students completed the Instructional Materials Motivation Survey (IMMS) to assess perceptions of TBL as an instructional method for learning. The IMMS is a valid 20-item survey designed to evaluate the ARCS Model of Motivational Design across four subscales: attention (A), relevance (R), concentration (C), and satisfaction (S). Total score ranges from 20-100 and subscale scores range 1-5. Item responses use a Likert scale from 1 (Not true) to 5 (Very true). A higher score on the subscales are desired. **SUMMARY.** 109 health science graduate students (female:77, male:30, prefer not to disclose:2, age:24.2±2.7 years) completed TBL sessions and the IMMS. The IMMS total scores were 70.3±17.5. Subscales scores were: A:4.0±1.1, R:4.4±0.9, C:3.7±2.1, and S:4.2±2.2. **CONCLUSIONS.** The IMMS is a valuable tool in the assessment of students' reactions to curricular design as it relates to the ARCS Model of Motivational Design. Overall, the design of TBL in our curriculum was successful in motivating students to learn. TBL was found to gain our students' attention, while staying relevant to the course and their future professions. Students reported confidence in TBL to hold their attention, be the correct level of difficulty, and were not bored by the presented material.

Abstracts - Poster Presentations continued

6 *PORTA, Emily M. and Jennifer BRUECKNER-COLLINS. Department of Anatomical Sciences and Neurobiology, University of Louisville School of Medicine, Louisville, KY, 40222, USA.

Taking a Competency Based Approach to Gross Anatomy Laboratory Instruction: A Pilot Study.

INTRODUCTION. The AAMC announced their new Strategic Plan in 2020, including plans to strengthen the medical education continuum by fostering innovation in competency-based medical education (CBME). One of their major goals is for the medical education community to implement CBME in new and emerging areas in diverse educational settings. We propose the Gross Anatomy dissection lab as a meaningful venue to implement CBME in undergraduate medical education. **RESOURCES.** A needs-based assessment was conducted at the University of Louisville in fall of 2021. First-year medical students were asked to rank order six competencies in the Gross Anatomy lab and propose 1-2 strategies to strengthen skills related to their weakest competency. At the end of the semester, they were asked to reflect on if those strategies improved their mastery of their weakest competency and comment on what additional resources would have been helpful to achieve mastery of their weakest competency. **DESCRIPTION.** CBME is an outcomes-based approach to the education and assessment of learners that uses competencies (observable abilities). With the influence of the AAMC competencies for entering medical school and the ACGME competencies for medical residents, we defined six competencies for the Gross Anatomy lab: Professionalism, Communication, Teamwork, Anatomical Knowledge, Dissection skills, and Preparation for lab. **SIGNIFICANCE.** Out of 149 student responses, Dissection Skills (43%), Anatomical Knowledge (24.8%), and Preparation for lab (18.8%) were ranked as the students' weakest competencies and Professionalism (32.9%), Teamwork (27.5%), and Communication (14.8%) as their strongest competencies. Student responses, their proposed strategies and desired resources indicated that incorporating and assessing competencies in the Gross Anatomy lab provides an optimal opportunity to study and develop CBME in undergraduate medical education for first-year medical students.

39 *PRADHAN, Grishma and Ricardo BELMARES. Department of Anatomy, Paul L. Foster School of Medicine, Texas Tech University Health Sciences Center El Paso, El Paso, TX, 79905, USA. Anatomical Variations Present in the Coronary Arteries.

INTRODUCTION. Throughout history, human coronary arteries have been studied for many years. This study was performed to research the anatomical variations that can be present in the coronary arteries. The main goal of studying these variations was to provide a better understanding of any clinical correlations that could be associated with differences in the arterial branching pattern. **METHODS.** Eighteen cadaveric hearts from the Willed body program at TTUHSC El Paso in the academic years of 2020-2022 were used to analyze these variations. **SUMMARY.** Several specimens had branching patterns, unlike the standard patterns. Out of the eighteen hearts, 44.4% of the hearts had a bifurcated posterior descending artery, 38.9% had a bifurcated left anterior descending artery, 33.3% had a trifurcated left anterior descending artery, 5.56% had bifurcated right marginal artery, 22.2% had a bifurcated left marginal artery, and 11.1% had a bifurcated posterior left ventricular artery. The RCA length was in the range of 3.2 cm to 6.9 cm and the LCA length was 0.5 cm to 2.5 cm. All of the eighteen hearts showed right-sided dominance with no variations in the origins of the right and left coronary arteries. **CONCLUSIONS.** Due to the smaller sample size, we were unable to find the proper clinical correlation between the variations and medical history. This work will help further catalog variations that are seen in the coronary vasculature allowing for decreased complications during cardiac procedures.

18 *RATHOD, Sonali, Riley KOLUS, Byungchan KIM, Sarika GURNANI, Andy KIM, Erin KIM, Faisal TAN, Isabelle VAN ROY, Elizabeth WHITNEY, Maryann MACNEIL, and Jonathan J. WISCO. Department of Anatomy and Neurobiology, Boston University School of Medicine, Boston, MA, 02118, USA.

A Case of an Abnormally Dilated and Tortuous Arc of Buhler and Pancreaticoduodenal Arteries.

INTRODUCTION. The Arc of Buhler is a vascular variant describing a persistent remnant of the embryologic ventral anastomosis between the celiac trunk (CT) and superior mesenteric artery (SMA). Arc of Buhler prevalence is estimated to be 3% of the population with only half of those cases being hemodynamically active, invariably reported in the context of CT stenosis. We encountered a case of 1) an abnormally large and tortuous pancreaticoduodenal arcade 2) a large and tortuous Arc of Buhler in the absence of CT stenosis. This finding represents a previously unreported case of dilated and tortuous anastomotic connections between the CT and SMA without any obvious causative factors. The abnormal position of this aberrant vessel may increase risks of herniation and surgical complications, and the tortuosity may increase the risk of clot formation. Surgeons should be aware of this example of abnormal anatomy for perioperative considerations and clinical identification of future pathologies. **METHODS.** The variant was discovered during routine cadaver dissection. We acquired transverse biopsies of variant vessels and evaluated their wall thickness. **SUMMARY.** The donor's anterior pancreaticoduodenal artery (PDA), posterior PDA, and Arc of Buhler had larger diameters than literature reported values of a standard human body. Additionally, the posterior PDA had significantly increased wall thickness compared to the other investigated vessels. The common hepatic artery was smaller in diameter than literature reported ranges. The splenic artery

continued on next page

Abstracts - Poster Presentations continued

diameter was within the literature reported range. CONCLUSION. The Arc of Buhler is a remnant of the embryologic ventral anastomosis that is estimated to be present in 3% of the population but hemodynamically active only in the context of CT stenosis. To the best of the authors' knowledge, this is the first reported case of a persistent and hemodynamically active Arc of Buhler in the absence of CT stenosis.

41 *RUTLAND, Marsha D., Karla M. ESPINOSA, Alyssa K. PEVEHOUSE, Sarah M. BROOKS, and Austin P. ALEXANDER. Department of Physical Therapy, Hardin-Simmons University, Abilene, TX, 79698, USA. [Muscular Axillary Arches from Bilateral Latissimus Dorsi and its Clinical Implications.](#)

INTRODUCTION. Background & Purpose: As Doctor of Physical Therapy (DPT) students learn anatomy through dissection, additional medical information is gleaned. As the death certificate only reviews the cause of death, students often discover supplementary medical complications. This study evaluates the discovery of bilateral latissimus dorsi bands, also known as the "Muscular or Langer's axillary arch", impinging on the axillary brachial plexus and axillary artery. RESOURCES. A 66-year-old male embalmed cadaver (11-month postmortem) was dissected by first year Doctor of Physical Therapy students over 8 months. Causes of death: Cardiovascular disease, Diabetes, Hypertension. Upon dissection of the anterior axillary region, bilateral muscular axillary arches were found from the latissimus dorsi bands compressing the brachial plexus in the axillary region. DESCRIPTION. DPT students researched axillary arch compression and speculated clinical implications of this anomaly. "Langer's axillary arch," an accessory muscle that normally crosses the axillary region from the latissimus dorsi and inserts into the pectoralis major, was discovered in 1795 and confirmed in 1894. The axillary arch has been reported in 7% of the general population and develops from the remainder of aponeurotic fascia(panniculus carnosus). Compression of neurovasculature can mimic thoracic outlet syndrome. Axillary arches may be mistaken for enlarged lymph nodes or a soft tissue tumor. Patients may report painful paresthesias of the arm, forearm, and hand and pain with shoulder abduction, external rotation, and elevation. Entrapment of the axillary artery may cause decreased blood flow to the upper extremities and cause axillary venous thrombosis or upper limb lymphedema. Lymphedema may cause swelling, feelings of tightness, limited range of motion, fibrosis, and recurring infections. The possibility of axillary venous thrombosis could occur with pain/tightness, blue coloration and sudden swelling in the upper limb.

SIGNIFICANCE. Through critical thinking, students speculated symptoms anticipated with muscular axillary arch compression. Health care clinicians should recognize these underlying factors and refer for further medical consult.

63 *SAKOWSKI, John H. and Neil S. NORTON. Department of Oral Biology, Creighton University School of Dentistry, Omaha, NE, 68178, USA.

[A Digital Learning Resource on the Pterygopalatine Fossa Using Cone Beam Computed Tomography.](#)

INTRODUCTION. The Pterygopalatine fossa is one of the most challenging anatomical areas for dental students to master. It is small a pyramidal-shaped fossa on the lateral aspect of the skull between the pterygoid process of the sphenoid and the maxilla. Due to this location in the skull, the fossa is a space that is difficult to conceptualize. Cone beam computerized tomography (CBCT) has become the gold standard in various dental treatment plans providing 3D reconstruction of the skull. RESOURCES. A CBCT scan of a young healthy male patient was taken. The DICOM images were imported into Horos, an image viewing software. The CBCT scans were exported to iMovie and the distribution of the maxillary division of the trigeminal nerve and maxillary artery were annotated in the CBCT to create the visual resource. Hyperlinks were added within the program to allow users to review anatomical concepts. DESCRIPTION. A learning resource was created to simplify the understanding of the pterygopalatine fossa using CBCT. In this learning resource are multiple short videos of CBCT scans of a skull. Each video has visual representations of one of the branches of the maxillary nerve and artery. SIGNIFICANCE. Educational digital learning resources provides a supplementary resource to help simplify understanding of difficult Anatomical concepts. The pterygopalatine fossa is a small but difficult anatomical area to conceptualize. Using CBCT allowed for the creation of a digital learning resource in 3D to help explain the distribution of the maxillary nerve and artery branches.

Abstracts - Poster Presentations continued

78 SIDDQUI¹, Ayla, and Daniel JIPESCU². ¹Texas Christian University, Fort Worth, TX, 76129, USA;

²Medical City, Fort Worth, TX, 76104, USA.

Sudden Cardiac Death in Young Athletes: Including Knowledge about Anomalous Coronary Arteries in Medical School.

INTRODUCTION. Sudden cardiac death (SCD) is a rare event and an unexpected tragedy. It is also the leading cause of death in young athletes in the U.S. Affected individuals are young and healthy but have undiagnosed cardiac conditions where their exercise causes unexplained sudden death. Anomalies of coronary arteries are second among identified structural causes of SCD in athletes but most of the medical curricula teach normal coronary arteries anatomy and other cardiovascular congenital defects such as tetralogy of Fallot. Earlier exposure to anomalous coronary arteries could be beneficial.

RESOURCES. PubMed database was searched using the subject keywords sudden death, athletes, and coronary anatomy. Publications included US athletes of 11-30 years that died during a game or practice or immediately after. Publications were excluded if the study population of any young athlete died because of known cardiac history, trauma, non-US athletes, died in sleep, possible drugs, or alcohol. In the review that we made, we found 317 manuscripts. **DESCRIPTION.** Sudden cardiac death incidence ranged from 1 in 40,000 to 1 in 80,000 athletes per year. Anomalies of coronary arteries are second in causes among identified structural causes of SCD in athletes, accounting for 17% of such deaths in the U.S. The most common anomalous origin is the right coronary artery originating from the left sinus of Valsalva. Among athletes of SCD, anomalous origin of the left main or left anterior descending coronary artery from the right sinus of Valsalva is more prevalent. SCDs are most strongly associated with the pattern in which the anomalous left coronary artery passes between the aorta and main pulmonary artery. **SIGNIFICANCE.** Our study demonstrates the need to emphasize anomalous coronary arteries to the students in anatomy courses of medical schools to equip them with the skills to screen, accurately identify, and appropriately treat young athletes for coronary artery anomalies.

54 *SMITH, Michael P., Amanda S. KHAN, Natalia LOWRY, and Jeffrey FAHL. Division of Anatomy, Albany Medical College, Albany, NY, 12208, USA.

A Rare Hamstring Variation: The Tensor Fasciae Suralis.

INTRODUCTION. Variations in the muscles of the posterior thigh are uncommon in literature. An extremely rare hamstring muscle variation is the tensor fasciae suralis (TFS) muscle. This accessory muscle has been reported to arise from the distal portion of any of the three hamstring muscles and may insert on the proximal gastrocnemius, posterior crural fascia, or calcaneal tendon. In this report we show a rare tensor fasciae suralis muscle arising from the long head of the biceps femoris. **RESOURCES.** During a routine dissection of a 93-year-old white male cadaver, a variation of the biceps femoris muscle was noted in the right posterior thigh. The posterior right leg was dissected to show the insertion of this anomalous muscle. No variations to the hamstrings of the left lower limb were detected. **DESCRIPTION.** The accessory muscle arises from the distal third of the long head of the biceps femoris. It descends from the posterior thigh, travels superficially across the popliteal region, and then between the two heads of the gastrocnemius before its insertion point on the posterior leg. The distal tendon appears to have three main portions, one that inserts on to the crural fascia overlaying the proximal gastrocnemius and two other slips that insert on the medial and lateral heads of the gastrocnemius. This muscle receives branches from the tibial portion of the sciatic nerve proximally and branches from the tibial nerve distally. The characteristics of this particular specimen are consistent with the description for the TFS muscle. **SIGNIFICANCE.** Structural variations of the hamstrings may affect the function of this muscle group, which could predispose a patient to injury, affect gait, compress underlying structures, mimic a Baker's Cyst or a soft tumor of the popliteal fossa. Documenting and adding to the knowledge of these different hamstring muscle variations can help clinicians expand the differential diagnostic possibilities and avoid diagnostic errors.

36 *TRAN, John¹, Anne M.R. AGUR¹. ¹Division of Anatomy, Department of Surgery, Temerty Faculty of Medicine, University of Toronto, Toronto, ON M5S 1A8, Canada.

Innervation of the First Carpometacarpal Joint: A Cadaveric Study for Denervation Procedures.

INTRODUCTION. Osteoarthritis (OA) of the first carpometacarpal joint (FCMCJ) has been reported to have a prevalence of 7% in men and 15% in women. Chronic joint pain related to FCMCJ OA can have a substantial impact on hand function. Patients with moderate-to-severe symptoms are considered for joint fusion however this procedure further limits the joint's range of motion (ROM). Ultrasound (US) guided radiofrequency denervation has emerged as a viable treatment option to manage chronic joint pain while preserving ROM. The effectiveness of denervation protocols requires a detailed understanding of the innervation of the joint. Previous studies of the nerve supply to the FCMCJ have not defined the relationship of articular branches to anatomical landmarks visible with US. The purpose was to document the course of articular branches supplying the FCMCJ in relation to relevant US landmarks. **METHODS.** Articular nerves, innervating the FCMCJ, were meticulously dissected in 7 specimens. The origin, course, and termination of each articular nerve were documented. US landmarks were identified to localize each articular nerve. **SUMMARY.** The innervation of the FCMCJ was extensive with up to 5-7 nerves innervating the joint. The anterior capsule was supplied by articular branches originating

continued on next page

Abstracts - Poster Presentations continued

from the lateral antebrachial cutaneous, superficial radial, recurrent branch of median, and palmar cutaneous branch of median nerves. The posterior capsule was supplied by articular branches from the lateral antebrachial cutaneous, superficial radial, and deep branch of ulnar nerves. Relevant US landmarks to locate the articular branches include the radial artery, tendon of flexor carpi radialis, tubercle of trapezium, and tendon of extensor pollicis longus. **CONCLUSIONS.** The course and distribution of articular nerves provide an anatomical basis for the development of new clinical denervation protocols to better manage chronic joint pain of the FCMCJ.

57 *WALLACE, Carrie¹, Edwin GLUECK², Shelby KUHNERT¹, Philip BRAUER², Crystal LEMMONS¹, Mary KILMER¹, and Alla BARRY¹. ¹Missouri Southern State University, Joplin, MO 64801, USA; ²Kansas City University of Medicine and Biosciences, Joplin, MO 64804, USA.

An Exploration of Catecholaminergic Fibers and Their Source within the Cervical Vagus Nerve.

INTRODUCTION. The vagus nerve (VN) is mainly known for its parasympathetic function. Although apparent communications between the VN and sympathetic ganglia have been described previously, the existence of sympathetic fibers within the VN is still under debate. Studies utilizing immunohistochemical verification with anti-tyrosine hydroxylase (TH) antibody have found a variable distribution of catecholaminergic activity in the cervical trunk of the VN. We aimed to elucidate the presence and distribution of the postganglionic sympathetic element within the cervical region of the VN. In addition, we evaluated neural communications between cervical sympathetic chain ganglia (SCG) and the cervical VN as a potential source of intravagal catecholaminergic fibers. **METHODS.** Dissection of the VN, cervical chain ganglia, and any communicating branches was performed bilaterally on 20 fully embalmed cadavers (male n=11, female n=9). Cervical VN samples were collected bilaterally, all communications were histologically validated to confirm the presence of neural tissue. Tissue sections were stained with anti-TH antibody and Luxol fast blue. Histological slides were viewed and photographed, and all images underwent quantitative analysis with ImageJ software. **SUMMARY.** Interconnections were found between the cervical VN and SCG in 11 donors (55%), resulting in 13 total neural anastomoses between the VN and either the superior, middle, or inferior cervical ganglia. TH immunoreactivity was detected in all donors in at least one sampled location. There was a significant interaction between gender and the percentage of TH-positive fibers on the right side ($3.0 \pm 1.22\%$ and $1.2 \pm 0.37\%$; $p=0.044$) female and male, respectively. The presence or size of communications did not influence the number of TH-positive fibers within the vagus nerve. **CONCLUSION.** Investigating the sympathetic activity of the VN and its source aids in understanding the vast physiologic role of the VN in the human body.

15 *ZEITOUNI, Ferris¹, Gurvinder KAUR², and Brandt SCHNEIDER². ¹Graduate School of Biomedical Sciences, Texas Tech University Health Sciences Center, Lubbock, TX, 79430, USA; ²Department of Medical Education, Texas Tech University Health Sciences Center, Lubbock, TX, 79430, USA. Instructional Videos Increase Academic Performance and Reduce Anxiety in Learning Clinical Anatomy.

INTRODUCTION. Anatomy presents a challenge for first year medical students (MS1s) due to the large amount of information presented. Students rely on “buzzwords” to recognize specific clinical concepts. However, this does not provide an in-depth understanding of this material. We hypothesized that concise instructional video modules covering clinical concepts would increase understanding of these concepts in anatomy. **METHODS.** This study was done at Texas Tech University Health Sciences Center School of Medicine (TTUHSC-SOM). High yield clinical concepts were identified from 23 mandatory cadaveric dissection labs in the MS1 curriculum and condensed into seven short videos which were presented over the 10-week anatomy course. The mechanism of injury in clinical scenarios were demonstrated using Complete Anatomy®, a commercially available 3D anatomy atlas, paired with de-identified cadaveric dissection videos. Each video was supplemented with pre- and post-quizzes with questions formulated to assess clinical concept understanding. Surveys were distributed to gauge usefulness of this resource for exam preparation and reduction of test anxiety. **SUMMARY.** After watching video modules, student performance significantly improved on all post-quiz scores as compared to the pre-quiz scores. For example, the week 1 quiz score average increased from 46% to 81% correct (P value $< .001$). Responses ($n=75$) collected from the end of the block survey showed 80% of students stated that this resource was “helpful” or “very helpful” in preparation for exams. Finally, 78% of students surveyed indicated this resource was “helpful” or “very helpful” in alleviating anxiety. **CONCLUSIONS.** Active learning through a video module incorporating 3D models and cadaveric footage enabled better understanding of clinical anatomy and decreased student stress. These results support the continued use and expansion of such resources in the first year of medical school. (Approved by TTUHSC QIRB# QI-17008.)

Abstracts – Tech Fair Presentations

* Accepted for Electronic Publication in *Clinical Anatomy*
(Listed by presenting author last name)

TECH FAIR SESSION

*THAI, Frank H., William Y. WOO, Rosaysela SANTOS, Boris B. BOYANOVSKY, Mostafa BELGHASEM, Jordan MOBERG PARKER, Jose M. BARRAL, and Dolgor BAATAR. Kaiser Permanente Bernard J. Tyson School of Medicine, Pasadena, CA 91101, USA.

Innovative Modality of 3D Scan Imaging for Anatomy Teaching.

INTRODUCTION. Learning anatomy using donor bodies and specimens is most efficient when guidance is provided by the instructor, but many students may need additional resources for independent study. Various factors such as anatomical variations and dissection quality may limit the use of textbooks or anatomy software as reference guides. Modern tools such as 3-dimensional (3D) models and plastinated anatomical specimens are increasingly attractive methods for learning anatomy but present some challenges for use in independent learning. In our school, we use plastinated anatomical specimens during instructor-led anatomy sessions and have developed a library of annotated 3D scans of our plastinates for students' independent learning. RESOURCES. Plastinates were obtained from the Gubener Plastinate GmbH (von Hagens Plastination). The Artec Space Spider and Artec Eva 3D scanners were used to scan the specimens and our scans were hosted on the Sketchfab platform (<https://sketchfab.com>). DESCRIPTION. To date, we have scanned and labeled 4 whole-body plastinates, 18 regional plastinates, and 19 plastinated organs. It took an average of 40-45 hours to scan and process a whole body at high resolution and 16-20 hours to scan and process an isolated organ. Anatomy instructors have labeled important anatomical structures and provided a brief description of the structures. These scans were used by a Class of first-year medical students (n=50) during one semester to prepare for their anatomy labs as well the anatomy practical exam. The whole-body scans were accessed by students – 676 times, regional specimen scans – 1193 times, and organ scans – 626 times. Scans were also used by instructors during remote anatomy sessions. SIGNIFICANCE. Three-dimensional scans of plastinated anatomical specimens provide an accessible method of teaching and learning anatomy independently. Furthermore, they turned out to be especially useful for remote anatomy sessions.

*LINK, Brittney L.¹, Mark TERRELL¹, Sarah MCCARTHY¹, Leah LABRANCHE¹, Stephany ESPER², and Randy J. KULESZA Jr¹. ¹Department of Anatomy, Lake Erie College of Osteopathic Medicine (LECOM), Erie, PA 16509, USA. ²Department of Osteopathic Principles and Practice, Lake Erie College of Osteopathic Medicine (LECOM), Erie, PA 16509, USA.

Development of Computer and Three-Dimensional Printed Models for Teaching Facial Nerve Anatomy.

INTRODUCTION. To differentiate signs and symptoms of cranial nerve injuries, students need to understand the branching and distribution of axon functional types. Existing computer and three-dimensional (3D) printed models of the facial nerve emphasize surgical planning or general nerve path and are inadequate for preclinical education. The present study aimed to develop computer and 3D printed models showing the path of facial nerve axon functional types to improve visualization of these structures. Efficacy of both models was compared with a traditional wire diagram during a learning session with first year medical students. METHODS. Amira 6.7.0 software was used to draw color-coded axon pathways onto a series of computed tomography scans of the head to produce a monoscopic 3D computer model of the facial nerve. This file was converted to a 3D PDF, allowing viewers to zoom, rotate, and toggle structures on/off. The skull was also 3D printed on a Phenom Peopoly printer in clear resin and color-coded wires were inserted to indicate the path of axon types. Pre/post/medium term retention tests measured content knowledge and surveys assessed student perceptions, confidence, and usability of the resources. Data were analyzed using repeated measures ANOVA or Kruskal-Wallis tests, as appropriate. SUMMARY. The three treatment groups performed similarly on knowledge tests. The 3D printed model was perceived more positively by students and resulted in greater confidence in knowledge. Survey responses indicated a need for alternative facial nerve learning resources. The printed model was perceived as most applicable to meet this need. CONCLUSIONS. The 3D printed model was preferred overall by students and is recommended as a supplement to traditional learning resources. (Sponsored by a grant from the American Association of Colleges of Osteopathic Medicine (AACOM) and Grant No. J2021.05 from the LECOM Consortium for Academic Excellence.)

Abstracts - Tech Fair Presentations continued

*WARNER, Amanda A., Alexa P. KELLY, and Scott D. MADDUX. Center for Anatomical Sciences, University of North Texas Health Science Center at Fort Worth, Fort Worth, TX, 76107, USA.

Virtual Reconstruction of 3D Skeletal Anatomy: A Comparison of Two Methodologies.

INTRODUCTION. Human skeletal remains recovered from forensic investigations are commonly damaged, presenting obstacles for subsequent analyses via 3D morphometric techniques which typically require that all specimens possess homologous anatomy (i.e., no missing data). As a consequence, two competing methods are generally employed to reconstruct such missing data: mathematical prediction of missing data using a reference sample (i.e., “mean substitution”) and virtual reconstruction in which missing data on one side is predicted by reflecting existing data from the contralateral side (i.e., “mirror imaging”). Here, we compare mean substitution and a newly developed mirror imaging methodology. METHODS. To test the accuracy and comparability of the two reconstruction methods, we employed a fully intact cranium and used the two methods to digitally reconstruct the left side of the face (as if it was damaged). Bilateral measurements of facial width from the two reconstruction methods were then compared to the specimen’s actual measurements. SUMMARY. Results indicate that the mirror imaging approach reconstructs missing data to within 0.3-2.6 mm of the actual anatomy. The measurement error appears to be randomly distributed, indicating this method does not systematically over- or under- estimate the positioning of data. In contrast, the mean substitution approach was found to routinely overestimate the mediolateral positioning of reconstructed data by 4.1-8.0 mm, indicating that this method typically reconstructs facial structures slightly wider than is anatomically accurate. CONCLUSIONS. These results suggest that the mirror imaging method permits more accurate reconstruction and thus appears advantageous in most scenarios. Additional evaluation of this newly developed 3D reconstruction method in comparison to other virtual reconstruction protocols is thus warranted.

*HINES, Jonathon H., Amberly M. REYNOLDS, and Mario G. LOOMIS. Department of Clinical Anatomy, Sam Houston State University College of Osteopathic Medicine, Conroe, TX 77304, USA.

Tumescent Fluid as a Tool for Improved Cadaveric Hand Dissections.

INTRODUCTION. The hand is an intricate part of the human body that is best appreciated via detailed cadaveric dissection. This research aims to discover how the use of tumescent fluid can be applied to cadaveric dissections to enhance the learning experience for medical students and residents alike by making the process more effective and efficient overall. This will be assessed by the ability of tumescence to increase the ease of dissection, create more separation between tissues, and aid in the identification of intact deep structures in situ. RESOURCES. Prior to beginning cadaveric hand dissections by first-year medical students, tumescent fluid was injected into the interstitial tissues using a 30cc syringe and blunt-tipped cannula. Tumescent fluid is a solution comprised of water, propylene glycol, and Sanisol 7® detergent disinfectant. Students then continued with their dissections which were followed by an anonymous voluntary Qualtrics® survey containing short answer questions to ascertain the benefit, if any, of tumescent fluid for cadaveric dissections. Qualitative thematic analysis was then performed using the answers provided. DESCRIPTION. Students (n=15) unanimously agreed that using tumescent fluid saved them time, made their cadaveric dissections easier, and created better separation of the layers of the hand. When students were asked if they would recommend the continued use of tumescence in the anatomy lab for future dissections, all participants stated “Yes”. Students stated they were better able to identify structures of the volar hand specifically listing the superficial and deep palmar arterial arches, the thenar and hypothenar eminences, and deep structures including the lumbricals and interossei. SIGNIFICANCE. Tumescent utilization is a simple technique to improve the quality of cadaveric hand dissections and allows learners to preserve more structures of the hand while also allowing for appreciation of the three-dimensional relationships in situ.

* ISHIKAWA¹, Marisa, BAGWISANYI, Tapiwa N.¹, Wanlert HORSANGCHAI¹, Balaji KALAIVANAN¹, Swai M. KHAING¹, Haider HILAL^{1,2}, and James COEY^{1,2}. ¹St. George’s International School of Medicine, Northumbria University, Newcastle-upon-Tyne, NE1 8ST, United Kingdom; ²Department of Anatomy, St. George’s University, Grenada, West Indies.

Effectiveness of Using 3D Printed Models in Students’ Understanding of Anatomical Heart Defects.

INTRODUCTION. Three-dimensional (3D) printed models can help medical students understand complex congenital heart defects (CHD), such as double aortic arch, right aortic arch, and anomalous right subclavian artery better by offering them the opportunity to visualize and manipulate heart models with these defects and ultimately provide greater patient care. As such, the objective of this study is to explore the effectiveness of 3D printed models in enhancing medical students’ understanding of the complex heart abnormalities listed above compared to only lecture-based teaching. RESOURCES. 3D models of double aortic arch, right aortic arch, and anomalous right subclavian artery were printed, using STL files. These models were presented in combination with a short lecture given by an anatomy professor, to examine their usefulness. DESCRIPTION. First-year medical students were recruited for the study and randomly divided into two groups: C is the control group and E is experimental. Each group was given 20 minutes to answer 10 multiple-choice questions (MCQ) as a pre-test to measure their baseline knowledge. Both groups were given a 15-minute pre-recorded lecture to watch during

Abstracts - Tech Fair Presentations continued

which, group E was given 3D printed models to spend time with while group C only watched the lecture. Data were collected using the same MCQs and an additional five Likert scale subjective questions as post-test. SIGNIFICANCE. This study compared the usefulness of 3D printed models as a teaching tool during a lecture to the conventional lecture-based teaching only in enhancing the first-year medical students' understanding of the following congenital heart defects: double aortic arch, right aortic arch, and anomalous right subclavian artery.

*BROWER, Gregory L.¹, Caitlyn N. MATEJKA², Matthew BOOMER², Ferris ZEITOUNI², and Gurvinder KAUR¹. ¹Department of Medical Education, School of Medicine, Texas Tech University Health Sciences Center, Lubbock, TX, 79430, USA; ²Graduate School of Biomedical Sciences, Texas Tech University Health Sciences Center, Lubbock, TX, 79430, USA.
Benefits of Incorporating Ultrasound and Clinical Simulations in Medical Pre-Clerkship Curriculum.

INTRODUCTION. Point-of-care ultrasound (POCUS) is used in clinical practice across many specialties. POCUS education is becoming an important component of medical school curricula. In conjunction with a simulation-based pre-clerkship curriculum, medical students can acquire clinical skills without exposing patients to unnecessary risk. Incorporation of simulation sessions has been shown to improve learner's performance in both simulated and clinical settings. At Texas Tech University Health Sciences Center, we incorporated POCUS and clinical simulations into the pre-clerkship curriculum. The main goals were to provide students with bedside US skills through hands-on experience and improve integration of clinical and basic science education via simulations incorporating normal or pathological US images. METHODS. Didactic and hands-on US sessions were introduced to first-year medical students (MS1s) during gross anatomy. MS1s were exposed to 3 US sessions that aligned with gross anatomy labs (shoulder, neck and liver/gall bladder). As the curriculum progressed, further US sessions were provided in conjunction with US images introduced in simulations (e.g., cardiac tamponade and pre-renal azotemia). Formative assessment of ultrasound images acquired by MS1s and clinical notes from the simulated patient encounters were used to provide feedback necessary to identify strengths and weaknesses. SUMMARY. Students were satisfied with their learning experience. US and simulation sessions were considered valuable in reinforcing anatomical knowledge and fostering development of clinical skills. CONCLUSIONS. MS1s perceived US training as valuable in understanding human anatomy and seemed to be more at ease in acquiring US images as the curriculum progressed. Additionally, incorporation of POCUS into simulations helped MS1s to "rule in" or "rule out" a specific condition during formulation of a differential diagnosis, allowing more effective diagnose and treatment of the patient.

*GIANNARIS, Eustathia Lela, Amanda J. COLLINS, Alexandra E. WINK, and Yasmin CARTER. Division of Translational Anatomy, Department of Radiology, UMass Chan Medical School, Worcester, MA, 01655, USA.
Pivot to Virtual Labs: An Opportunity to Expand Our Instructional Toolbox.

INTRODUCTION. During the pandemic, anatomy instruction at UMass Chan Medical School was forced to pivot from a hands-on, in-person experience to remote learning. In response, faculty created synchronous, interactive, virtual lab sessions for learners to apply content knowledge and work in their lab teams. Student feedback and evaluations, as well as faculty reflections, were examined to inform ongoing and future use of virtual labs for anatomy instruction. RESOURCES. The faculty team collaborated on development and delivery of virtual labs with a focus on content, interactivity, and timing. End-of-unit and -course evaluations of the virtual labs were administered for student feedback. DESCRIPTION. Virtual lab sessions included image labeling, Complete Anatomy tutorials, and educational games. Students worked in their dissection teams in breakout rooms and faculty led large group activities. Adaptations were made to subsequent sessions based on student feedback and faculty reflections. Virtual labs coupled with prosection self-study sessions were included in the next iteration of the course for certain anatomical regions, while dissection resumed for other regions. SIGNIFICANCE. Analysis of evaluations and comments showed most respondents felt that virtual labs helped them learn and understand the material and they liked working with their lab teams in breakout rooms. Common critiques of the virtual labs were about duration. Faculty found this approach to remote learning was effective based on comparison of lab practical exam performance and overall student satisfaction. Pivoting to virtual labs highlighted opportunities to enrich the in-person lab experience when able to be coupled with prosection self-study. Future anatomy instruction can utilize virtual labs to help learners consolidate content and understanding of certain complex 3D anatomical regions, while also supporting teamwork and community building during the learning experience.

Thank
You

for attending the 39th Annual Meeting
of the American Association of Clinical Anatomists in Fort Worth, Texas.

We look forward to seeing you next year.

***The 2023 meeting will be held in
Orlando, Florida.***

For further information, please visit www.clinical-anatomy.org

